

Case Report

Ectopic lumbar kidney: a rare presentation

Ela Haider Rizvi*, Kailash Charokar, Ajay Kumar Jain

Department of Surgery, People's College of Medical Sciences and Research Centre Bhopal, Madhya Pradesh, India

Received: 29 June 2018

Accepted: 26 July 2018

***Correspondence:**

Dr. Ela Haider Rizvi,

E-mail: dr.ela.haider@gmail.com

Copyright: © the author(s), publisher and licensee Medip Academy. This is an open-access article distributed under the terms of the Creative Commons Attribution Non-Commercial License, which permits unrestricted non-commercial use, distribution, and reproduction in any medium, provided the original work is properly cited.

ABSTRACT

Ectopic kidney is a rare developmental anomaly. Such kidneys may be asymptomatic or present with vague symptoms or remain unknown during the lifetime. Early detection and recognition of an ectopic kidney can prevent long-term complications. We report a 70-year-old lady with ectopic right kidney who presented with intermittent episodes of lower abdominal pain since one month 1 month. On clinical evaluation a tender lump was palpable in the right lower quadrant of the abdomen. Sonography revealed empty right renal fossa with normally present left kidney. A mass was detected in the right lower abdomen, with probability of ectopic kidney. Further, Multislice computed tomography with 3-D reconstruction demonstrated ectopic right kidney at the level of L4 to L5 lumbar vertebrae. Urine examination revealed pyuria. The patient was managed on empirical antibiotics for UTI with supportive and symptomatic therapy. On the next day, clinically the lump regressed significantly (Dietl's crises) in size, and the tenderness also reduced. The urine culture report grew *Escherichia coli*. Patients presenting with lower abdominal pain, and a palpable lump in the lower abdomen, one must include ectopic kidney in the differential diagnosis.

Keywords: Acute Hydronephrosis, Dietl's crises, Ectopic kidney, Lumbar kidney

INTRODUCTION

Acute abdomen is sometimes a challenging clinical presentation and poses a diagnostic dilemma for the clinicians. In adults, lower abdominal pain is one of the presentations in cases of acute abdomen, which sometimes may turn out to be a serious condition. It is imperative to keep in mind various relevant organ systems, including the genital organs while evaluating these cases. The ectopic kidney may present as abdominal pain and be a predisposing factor to complications in the genitourinary system. Such kidneys may be present in a pelvic, iliac, lumbar, abdominal, thoracic, or crossed position.¹

There is a risk of hydronephrosis due to extrinsic compression of the renal pelvis and/or kinks in the ureter causing chronic vague discomfort or pain; calculus formation with consequent hydronephrosis which may

present as colicky pain and haematuria. Also, ectopic kidneys are susceptible to external trauma due to ectopic locations.

Embryological development of kidneys involves a cephalic migration of the kidneys to their normal retroperitoneal location. Ectopic kidneys are a result of arrested normal migration.

The incidence of ectopic kidneys is 1:12,000 clinical and 1:900 postmortem cases.² Most cases of ectopic kidney remain asymptomatic through life, and the clinical recognition is estimated to be only 1 in 10,000 patients.³ Early diagnosis of the ectopic kidney can prevent complications and decrease its, long-term sequels or complications.

To our knowledge, ectopic kidney on the right side above the level of aortic bifurcation is rare. In this report, we

present the unusual cause of lower abdominal pain in an old female with a palpable ectopic kidney in the right lower quadrant of the abdomen.

CASE REPORT

A 70-year-old lady presented with lower abdominal pain for the 1-month duration. She complained about 4 episodes during the previous month, with each episode lasting for few days. She had consulted local doctors before visiting our hospital. The pain has increased in severity during the present episode, which was present since past 8 days. The pain started, on the right side of lower abdomen, and has not changed its' position since the beginning. She described the pain as intermittent and burning, but with no pain radiation. She also complained about the frequency of urine with dysuria but denied any complaints of haematuria, fever, chills, and vomiting. She had menopause about 20 years before. The past medical history was not contributory, and there was no history of previous surgery.

On admission, the general physical examination was within normal limits. Initial vital signs, including blood pressure, pulse rate, respiratory rate, and body temperature were within normal range.

Physical examination revealed a palpable moderately tender discoid shape firm lump (7cm X 10cm) in the right lower half of the umbilical and adjoining hypogastric region of the abdomen. The lump was partially mobile. Other regions of the abdomen were soft and non-tender. Bowel sounds were normal. The genital examination and digital examination were unremarkable.

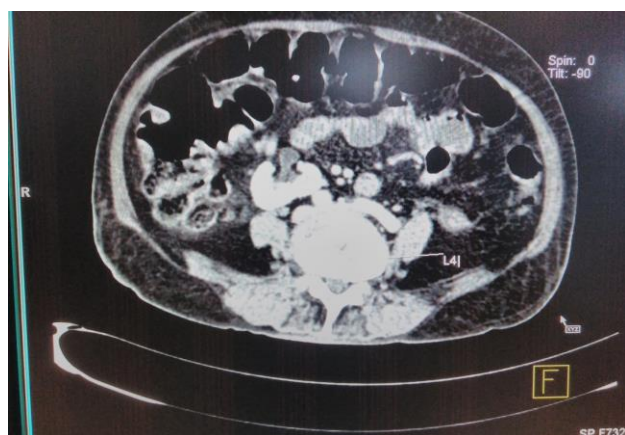

Figure 1: Right ectopic kidney at the level of L4 and L5 lumbar vertebra.

The white cell count was 15,200 cells /mm³ with a differential count of polymorphs 75.9%, lymphocytes 15.4 %, and 4.2% monocytes. The hemoglobin level was 10.5 g/dL, with a hematocrit of 28.5%.

Urinalysis revealed white blood cells (20-25/high power field), red blood cells (3-5/high power field). The

midstream urine cultures grew *Escherichia coli* with more than 10⁵ colony count. Blood sugar 128mg/dl, Blood urea 49.2mg/dl--and serum creatinine 1.32mg/dl. Liver function tests were within normal limits.

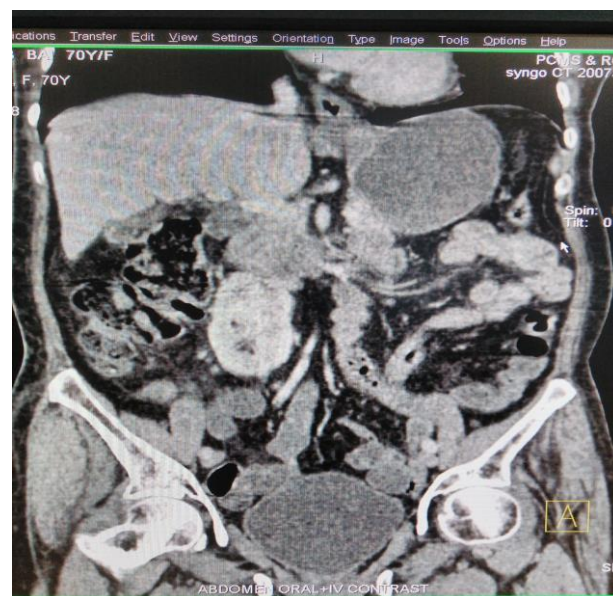

Figure 2: CECT abdomen with oral and IV contrast showing abnormally located right kidney.

Plain abdominal radiography was negative for calcifications and had a normal bowel gas pattern. Abdominal ultrasound was done on next day of admission, which revealed normally positioned left kidney (length 98mm, width 51mm) but the right kidney was not seen in the right renal fossa. Sonologically, a mass was seen in the right lower quadrant, probably low right kidney. Abdominal CECT (Figure 1 and 2) with IVU (figure 3) and 3D reconstruction confirmed small size, lumbar kidney opposite to 4th, and 5th lumbar vertebrae on the right side, above aortic bifurcation, and mildly enlarged left kidney in the normal position. No other evidence of obstruction was found in IVU.

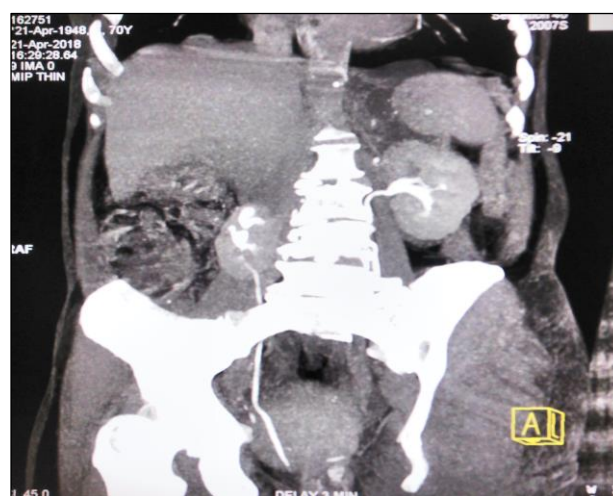


Figure 3: CT-IVU small ectopic right kidney.

The patient was managed on intravenous antibiotics, supportive and symptomatic therapy. During the continual therapy, clinically the tenderness and size of lump reduced significantly on the next day of admission, thereafter the patient made a gradual recovery. The significant reduction in size was clinically indicative of dietl's crises. Final clinical diagnosis of ectopic right lumbar kidney above aortic bifurcation with acute hydronephrosis (dietl's crises) and urinary tract infection was concluded. She was discharged from hospital on the 6th day with oral antibiotic therapy, and a regular follow up was advised. No episode of recurrent abdominal pain was encountered during the 3 months of follow-up at our outpatient clinic.

DISCUSSION

Human kidneys have a complex system of embryological development. The ectopic pelvic kidney is a rare anomaly about 1:2500 live births, left side being more common.⁴ This predisposes them to increased frequency of congenital malformations. Associated urological abnormalities were recorded in 43% of children with renal ectopia.⁵ The genitourinary malformations include ureteropelvic junction obstruction, vesicoureteral reflux, ectopic ureter, vaginal atresia, undescended testis, and hypospadias.⁶ Furthermore, the ectopic kidney is frequently associated with maldevelopment of other systems involving the skeletal and cardiovascular systems, gastrointestinal tract, and certain other miscellaneous anomalies.⁷ Congenital malformations of the urogenital system are estimated to be about 10% of all births.⁵ Of these, approximately 50% are defects of the upper urinary tract.⁸

When there is a migration arrest or deviation in the path of migration during the embryological development of metanephros, it results in an Ectopic kidney. Therefore, the normal renal fossa is seen empty in the imaging. The kidney may be ectopic on its own side (simple ectopia), or it may be located across the midline and be fused or unfused with its contralateral kidney (crossed ectopia). The crossed ectopia maybe 'S' or 'L' pattern depending upon the manner of fusion of the two kidneys. The 'S' pattern have pelvis and ureter facing laterally for the lower moiety, and in 'L' type the pelvis and ureter of lower moiety face medially.⁹ In general, the most common position is in the pelvis opposite the sacrum and below the aortic bifurcation.¹⁰ The clinical index of suspicion of ectopic kidneys is low due to its rare occurrence and vague presentations.

In a study the most frequent presenting symptoms and signs to be urinary tract infection, 44%; abdominal pain, 23%; palpable mass, 19%; microscopic hematuria, 6%; incontinence, 5%; hypertension, 3% and renal insufficiency, 3%.¹⁰ Classically, the size of the ectopic kidney is smaller, the renal pelvis and ureter having tortuosities. Tortuosity and kinking of the ureter predispose the ectopic kidney to obstruction or bacterial

infection.⁸ Our patient had acute hydronephrosis with urinary infection as the kidney was tender and palpable. Localized lower abdominal pain might be due to acute hydronephrosis (dietl's crises) form sudden stretching of renal capsule, infection of the kidney, or spasm of ureters or due to a combination of these factors. Ectopic kidneys are predisposed to recurrent upper urinary tract infections due to the reasons discussed above. The syndrome of episodic abdominal pain and acute hydronephrosis caused by sudden obstruction to urine flow due to ureteric mucosal edema, tortuosities, and kink of the ureter or extrinsic pressure from an artery is known as Dietl's crisis.¹¹ The key to diagnose Dietl's crisis is awareness of the entity, taking a detailed pain history, careful periodic clinical examinations, and timely cross-sectional abdominal imaging during an attack. Our, patient had a tender palpable ectopic kidney on admission, and it significantly reduced in size and tenderness resolved after 48 hours of starting the antibiotics.

On clinical suspicion, or incidentally, ectopic kidneys will be diagnosed by the radiographic investigations. Sonography, followed by Intravenous urography is the first-line investigation. However, we feel, a Multislice CT-IVU with 3-D reconstruction would be the preferred mode of investigations. If required, a voiding cystourethrography is helpful for assessing the vesicoureteric reflux. If indicated further, a cystoscopy and retrograde pyelogram may be undertaken for assessing the ureteric orifices and anatomy of the ureter and pelvis. Occasionally, angiography should be considered.⁶

Usually, for asymptomatic or incidentally discovered patients' ectopic pelvic kidneys do not require surgical treatment. However, when the ectopic kidneys are diagnosed to have pelvi-ureteric junction obstruction or vesicoureteric reflux, it will require surgical corrections. Similarly, an ectopic ureteric orifice producing incontinence, it will require reimplantation in the urinary bladder.⁸ However, if a nonfunctioning kidney is discovered with atrophic renal parenchyma, it is justified to perform a primary nephrectomy. Although the ectopic kidneys may be nonfunctional, cases of lithiasis or formation of renosigmoid fistulae have been reported in relation to a pelvic kidney. In such cases nephrectomy forms the choice of treatment, an effort to save the kidney being made only if the kidney is found to be functioning normally.¹²

In present case, since no such features were seen so the patient was managed conservatively with antibiotics for 3 weeks. Early confirmation and recognition of other anomalies associated with pelvic kidney can prevent the long-term complications. Upper tract urothelial carcinoma of the ectopic kidney is rare diseases with only three cases were reported in the literature.¹³ The transverse mobility of pelvic kidney causing left lower extremity deep venous thrombosis has been recently reported by the Christopher et al.¹⁴ Although a simple

ectopic kidney seldom causes symptoms, the association of malrotation of the renal pelvis with calculus increases the risk of hematuria and/or hydronephrosis, presenting with colicky pain. The clinician should be aware of such presentations in such a case.¹⁵ In a patient with an empty renal fossa, it is more common for the patient to have an ectopic kidney rather than renal agenesis. Ectopic kidneys may be dysplastic in appearance with variable size, shape, and rotation. It is important to be aware of the possibility of having an ectopic kidney and that it may have an atypical appearance to avoid misdiagnosis and potentially unnecessary surgery or biopsies.¹⁶

CONCLUSION

We have described an ectopic lumbar kidney on the right side presenting with ipsilateral lower abdominal pain. In cases of lower abdominal pain, with a palpable lump in the lower abdomen, one must consider ectopic kidney in the differential diagnosis. A simple ectopic kidney may sometimes present with complications, as in the present case. If asymptomatic, no treatment is required. However, the patient should be advised 3 monthly follow up or early if develops any symptoms.

Funding: No funding sources

Conflict of interest: None declared

Ethical approval: Not required

REFERENCES

1. Bauer SB. Anomalies of the kidney and ureteropelvic junction. In: Walsh PW, Retik AB, Vaughan Ed Jr, eds. Campbell's Urology. 7th ed. Philadelphia: Wb Saunders Company; 1998;1709-1755.
2. Meizner I, Yitzhak M, Levi A, Barki Y, Barnhard Y, Glezerman M. Fetal pelvic kidney: a challenge in prenatal diagnosis? Ultrasound Obstet Gynecol. 1995;5:391-3.
3. Gleason PE, Kelalis PP, Husmann DA, Kramer SA. Hydronephrosis in renal ectopia: incidence, etiology and significance. J Urol. 1994;151, pp. 1660-1.
4. Reddy CK, Syed NA, Satyanarayana N, Phukon MJ, Dutta R, Sunitha P, et al. Left ectopic kidney with non-rotation: a case report. Nepal Med Coll J. 2010; 12(2): 123-4.
5. Guarino N, Tadini B, Camardi P, Silvestro L, Lace R, Bianchi M. The incidence of associated urological abnormalities in children with renal ectopia. J Urol. 2004;172:1757e9.
6. Patricia K, Donahoe W, Hardy H. Pelvic kidney in infants and children: experience with 16 cases. J Pediatr Surg. 1980;15:486e95.
7. Ward JN, Nathanson B, Draper JW. The pelvic kidney. J Urol. 1965;94:36e9.
8. Macksood MJ, James RE. Giant hydrocephalus in ectopic kidney in a child. Urol. 1983;22:532e5.
9. Norman S, Christopher JK, Ronan O, Connel P. The Kidneys and Ureters. Bailey and Love's Short Practice of Surgery. 25th edn. Hodder Education, UK 2008. pp 1286-1287.
10. Malek RS, Kelalis PP, Burke EC. Ectopic kidney in children and frequency of association with other malformations. Mayo Clinic Proc. 1971;46:461e2.
11. Mergener K, Weinerth JL, Baillie J. Dietl's crisis: a syndrome of episodic abdominal pain of urologic origin that may present to a gastroenterologist. Am J Gastroenterol. 1997;92(12):2289-91.
12. Belsare SM, Chimmalgil M, Vaidya SA and Sant SM. Ectopic Kidney and associated anomalies: a Case Report. J Anat. Soc. India 2000;51(2) 236-238.
13. Halalsheh O, Ghawanmeh HM, Alshammari A, Sahawneh F, Al-okour R, Karasneh AA, et al. Upper Tract Urothelial Carcinoma in Ectopic Pelvic Kidney. Urol Case Reports. 2017; 11:42-3.
14. Christopher P, Vittore MD, Robert, Murray MD. Transverse mobility of pelvic kidney causing left lower extremity deep venous thrombosis. Radiol Case Reports. 2017;12; 285-6.
15. Rohit B, Dinesh S, Singh Y P, Kshama N, Anurag S. An Ectopic Pelvic Kidney. Pol J Radiol. 2015; 80:425-7.
16. Dagainawala N, Qin H, Lerner L, Jati A. Ectopic dysplastic kidney. Applied Radiol. 2016;45(12):28-30.

Cite this article as: Rizvi EH, Charokar K, Jain AK. Ectopic lumbar kidney: a rare presentation. Int Surg J 2018;5:3410-3.