

Case Report

Perforated appendicitis with peri-appendicular abscess within an incisional hernia: a report of an unusual case

Tousif Kabir^{1*}, Wong Kar Yong²

¹Department of General Surgery, Sengkang General Hospital, Singapore

²Department of General Surgery, Tan Tock Seng Hospital, Singapore

Received: 27 June 2018

Revised: 07 November 2018

Accepted: 14 November 2018

*Correspondence:

Dr. Tousif Kabir,

E-mail: tousif.kabir@singhealth.com.sg

Copyright: © the author(s), publisher and licensee Medip Academy. This is an open-access article distributed under the terms of the Creative Commons Attribution Non-Commercial License, which permits unrestricted non-commercial use, distribution, and reproduction in any medium, provided the original work is properly cited.

ABSTRACT

Amyand's hernia is a rare phenomenon referring to the presence of an appendix within an inguinal hernia. Hernial appendicitis occurs even more rarely in 0.07-0.13% of cases. Cases have been described in incisional hernias of laparoscopic port sites, nephrectomies and various other incisions. Author described an unusual case of an elderly lady who presented with nausea, fever and a tender abdominal mass over a previous paramedian incision. She was thought to have an incarcerated incisional hernia and was counselled for emergency surgical repair. Intra-operatively, she was found to have a perforated appendicitis with a large peri-appendicular abscess within an incisional hernia. The base of the appendix was unhealthy thus a limited right hemicolectomy was performed and the hernia was repaired primarily. Such cases present atypically and present a diagnostic challenge. Delays in recognition and timely intervention may lead to high morbidity and mortality. The authors hoped to raise awareness of this condition and contribute to the medical literature surrounding this unusual pathology.

Keywords: Amyand, Appendicitis, Hernia, Incisional

INTRODUCTION

Appendiceal hernias have been described in the literature since the 1700s.¹ The presence of the appendix in an inguinal hernia is known as an Amyand's hernia and the reported incidence is 1%.^{2,3} The commonest location for this is in the right groin but cases have also been described in femoral, spigelian, umbilical, obturator and incisional hernias.⁴⁻⁸ When the appendix becomes inflamed in these hernias, classic symptoms of appendicitis are not apparent and hence it can be very challenging to diagnose.⁹ Unfortunate delays in diagnosis have resulted in perforation, gangrene, abscess formation and even necrotizing fasciitis of the abdominal wall and groin.¹⁰ There are a few incidences of acute appendicitis occurring in incisional hernias following laparoscopic port sites, renal transplants and large abdominal wall

hernias.¹¹⁻¹³ Author reported an unusual case of a perforated appendix complicated with a large peri-appendicular abscess occurring in an incisional hernia, and present a review of the literature. A high index of suspicion is required due to the atypical presentation, and once recognized, prompt surgical intervention is crucial.

CASE REPORT

An 83-year-old lady presented with lower abdominal pain associated with nausea and fever. Abdominal examination revealed a right paramedian scar from a previous surgery, with a large 15cm tender mass palpable beneath. There was no cough impulse and the mass was irreducible. Blood tests revealed elevated white cell count of 18.5.

A diagnosis of incarcerated incisional hernia was made and the patient was counselled for emergency surgical repair. After a skin incision over the previous paramedian scar, a large abscess cavity was discovered in the subcutaneous layer. This was drained and subsequent examination revealed a 3cm fascial defect in the abdominal wall, with a necrotic tubular mass herniating through it (Figure 1).

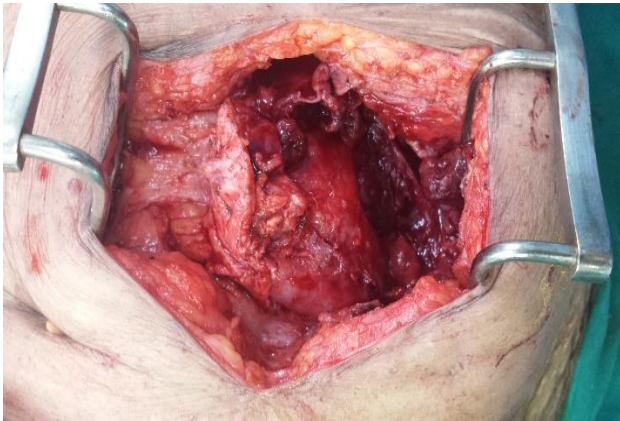


Figure 1: Abscess cavity containing necrotic tubular structure.

The mass was inseparable from the cecum and hence, a diagnosis of perforated appendicitis was made (Figure 2).

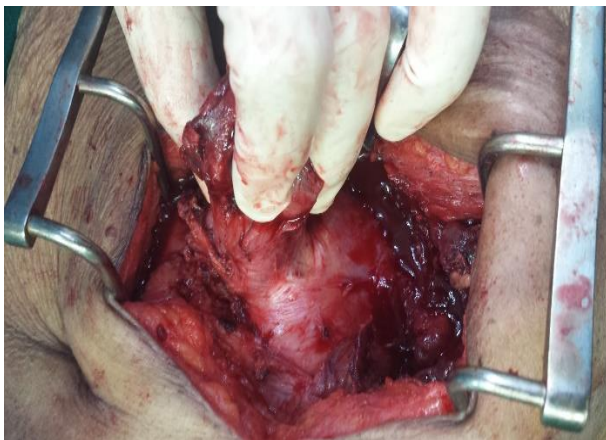

Figure 2: Appendix and part of caecum herniating through fascial defect.

The base of the appendix was unhealthy and part of the cecum had also herniated through the fascial defect. Thus, a limited right hemicolectomy was performed. Hernia repair was then performed by closing the transversalis fascia and internal oblique muscles primarily. The necrotic external oblique layer was debrided and irrigated copiously, a surgical drain was placed and the skin was closed loosely using staples. The patient subsequently recovered well. Histology revealed a fibro-inflammatory mass with the appendix trapped inside showing features consistent with perforated acute appendicitis (Figure 3).

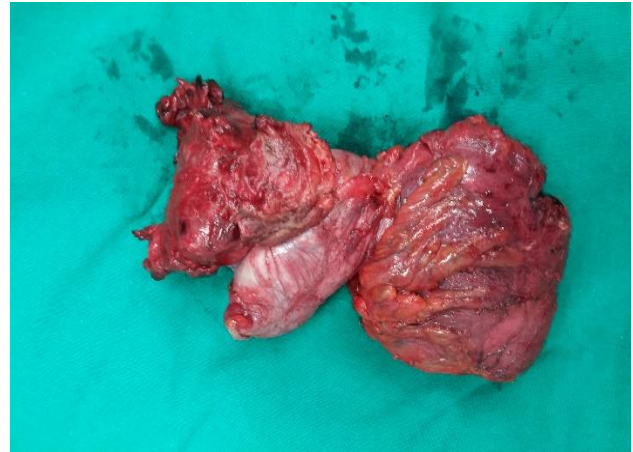

Figure 3: Resected specimen showing part of caecum and appendix.

DISCUSSION

The Amyand's Hernia (AH) owes its name to Claudius Amyand, a military surgeon in the British Army.¹ On 6th December 1735, he performed the first documented appendectomy on 11-year old Hanvil Anderson, who had a perforated appendicitis in a right inguinal hernia complicated by a faecal fistula. More than a century later, the first appendectomy done in the United States was also a case of Amyand's hernia, in which an abscess with gangrenous appendicitis was found inside a right inguinal hernia sac.¹⁴ AH has been defined as an inguinal hernial containing a non-inflamed appendix, an inflamed appendix or a perforated appendix.² They are quite rare, with the reported incidence of finding a non-inflamed appendix in the hernia sac being 1%, and that of hernial appendicitis occurring in 0.07-0.13% of cases.^{3,4,15} It tends to occur more frequently on the right side and in male patients.⁴ While the commonest location for this is in the groin, especially in inguinal and femoral hernias (called De Garengeot's hernia), cases have also been described in spigelian, umbilical, obturator and incisional hernias.⁵⁻⁸

The exact mechanism by which the appendix becomes incarcerated into the hernia is unknown, but it may be attributed to underlying hypermobility of the cecum, situs inversus (presenting with left-sided AH), or malrotation during embryonic development. In cases of incisional hernias such as ours, the cause is more likely progressive inflammation leading to adhesion formation from previous surgery.¹⁵ It is postulated that in these cases, appendicitis may be provoked by potential interference of the arterial supply or venous drainage of the organ due to its confinement within the edges of the hernial defect.⁸ This is different from intraperitoneal appendicitis where intraluminal obstruction is the typical precipitant of inflammation.¹⁶ Losanoff and Basson classified AH into 4 subtypes based on the extent of sepsis and presence of intra-abdominal pathology (Table 1).^{17,18}

Table 1: Losanoff and Basson's pathological types of Amyand's hernia and their respective management.

| Type of hernia | 1 | 2 | 3 | 4 |
|---------------------|---|--|--|---|
| Salient features | Normal appendix | Acute appendicitis localized in the sac | Acute appendicitis, peritonitis | Acute appendicitis, other abdominal pathology |
| Surgical management | Reduction or appendectomy (depending on age), mesh hernioplasty | Appendectomy through hernia, endogenous repair | Appendectomy through laparotomy, endogenous repair | Appendectomy, diagnostic workup and other procedures as appropriate |

In type 1, a normal appendix is present in the hernia sac. type 2 hernias consist of acute appendicitis with septic changes contained within the sac. When appendicitis occurs with sepsis spreading beyond the hernia sac resulting in abdominal peritonitis, it is considered type 3. Finally, in type 4 a serious complicating pathology may exist outside of the sac such as colon cancer, diverticulitis of the colon, adenocarcinoma of the vermiform appendix or inguinal appendicocoele with pseudomyxoma peritonei. Based on this classification system, the patients had a type 2 AH as all the pus was contained within the abscess cavity, and there was no intra-peritoneal sepsis. These hernias are notoriously difficult to diagnose as classic symptoms of acute appendicitis are not apparent. This is because the entrapment of the appendix in the hernia sac prevents the spread of inflammation to the peritoneal cavity. Fever and leukocytosis also may not be present.⁹ Most patients present with signs and symptoms suggestive of an incarcerated or strangulated hernia.¹⁹

Other differentials include strangulated omentocoele, Richter's hernia, inguinal adenitis, orchi-epididymitis, testicular tumor with hemorrhage, and acute hydrocele.⁹ As such, most cases are usually discovered during the surgery itself.²⁰ Delays in diagnosis have resulted in perforation, gangrene, abscess formation and even necrotizing fasciitis of the abdominal wall and groin.¹⁰ Previous reported mortality ranged from 14-30% due to peritoneal spread of the septic process.⁴ Early diagnosis and treatment has improved this to 5.5% in recent series.¹⁵

To prevent such delays, useful radiological adjuncts for diagnosis include Ultrasound (US) and Computed Tomography (CT) scans. On US, examination of the groin may reveal an inflamed hernia sac containing a solitary elongated, tubular, and blind structure with concentric layers in its wall, confirming an intestinal origin.²¹ Proximally, this structure can be seen traversing the inguinal canal and originating from the caecum.²² US is helpful in the paediatric population but CT scan are preferred for adults due to their larger size.²³ Luchs JS et al, were the first to describe the use of CT to diagnose AH in 2 patients who had presented clinically with incarcerated hernias.²⁴ Subsequently, the coronal and sagittal reformats were shown to be particularly useful in

identifying the blind-ending tubular appendix arising from the cecum and entering the inguinal canal.¹⁶ Type 1 hernias may be missed on CT scans especially if a prominent spermatic cord is present. Inflammatory fat stranding in the inguinal canal and an enlarged, thickened appendix within the hernia sac should alert one to the presence of a type 2 hernia. Type 3 hernias are difficult to diagnose, as extensive inflammatory changes may obscure the appendix within the inguinal canal. Finally, type 4 hernias may be very diverse as the intra-abdominal pathology may arise from any organ and thus careful radiological inspection is necessary for establishment of proper diagnosis.²⁵

The presence of the appendix within an incisional hernia is quite rare. To the best of our knowledge, there are only 10 case reports available, as summarized in Table 2. Including the present case, there are a total of 12 patients. 58% were female, and the average age was 62.3 years. Interestingly, 66% arose from right-sided incisions which is similar to the distribution in non-incisional AH. 4 cases occurred in port sites from previous laparoscopic surgery while the rest were from a variety of other abdominal incisions. CT scan was only performed for 4 patients, the remainder of the cases were diagnosed intra-operatively. 58% of the patients had type 2 hernias, 3 had type 1, and one patient each had a type 3 and type 4 hernia. The patient with type 4 hernia had an enterocutaneous fistula arising in an incisional hernia which was later found to be originating from an appendiceal mucinous adenocarcinoma. Primary suture repair was performed in 7 cases, while mesh was used to for the rest. Most authors recommend performing an appendectomy through the hernia defect, followed by primary hernia repair.⁹ In favourable circumstances, this may even be performed fully laparoscopically.^{26,27}

In the setting of a non-inflamed appendix, some would argue that performing an appendectomy may potentially violate aseptic principles by the excision of a faecally contaminated organ in a clean contaminated wound.¹⁵ This might increase the risk of wound and mesh infection and thus, incidental appendectomy is not advocated. However, this topic is debatable as the manipulation of a normal appendix may incite secondary appendicitis, hence performing an incidental appendectomy will reduce the future morbidity and risk of future

appendectomy.^{28,29} Another issue for contention is whether a mesh should be used in the presence of an inflamed appendix. Compared to open suture repair, mesh placement has been shown to reduce recurrence rates of hernias but increases the risk of infection.¹³ Most agree that prosthetic mesh can be safely used in the absence of gross soilage following hernial appendicitis. However, in the setting of a contaminated wound using a mesh is not advised as there is an increased risk of mesh infection and fistula formation. Indeed, in Losanoff and

Basson's classification, mesh placement was not advocated in any hernia other than type 1. In this study, patient where there was already frank infection in the form of a large abscess, mesh repair was definitely not an option due to the high risk of future mesh infection, which would be disastrous for the patient. Although there are some reports of biological meshes being safely utilized in contaminated surgical fields with good results further research needs to be done in this matter.³⁰

Table 2: Reports of incisional hernias containing appendix.

| Year | Author | Age | Sex | Incision type | Preoperative CT scan | Hernia type | Type of repair |
|------|-------------------------------|-----|-----|---|----------------------|-------------|---|
| 1991 | Horgan et al ⁸ | 62 | F | Left lower abdomen transverse incision | N | 3 | Primary suture repair |
| 2005 | McKay et al ³¹ | 45 | F | Right upper quadrant incision | N | 1 | Primary suture repair |
| 2009 | Menenakos et al ¹¹ | 63 | M | Laparoscopic port site in right lower abdomen | N | 2 | Mesh |
| 2010 | Sayles et al ³² | 68 | F | Right iliac crest incision for bone graft | Y | 4 | Mesh |
| 2010 | Hadithy et al ¹² | 57 | M | Right radical nephrectomy incision | Y | 2 | Mesh |
| 2011 | Das et al ³³ | 53 | F | Laparoscopic port site in umbilicus | N | 2 | Primary suture repair |
| 2011 | Latyf et al ³⁴ | 62 | M | Laparoscopic port site in right iliac fossa | N | 1 | Mesh |
| 2012 | Sugrue et al ¹³ | 78 | M | Upper midline incision | N | 2 | Mesh |
| 2012 | Sugrue et al ¹³ | 81 | M | Laparoscopic port site in right iliac fossa | N | 2 | Primary suture repair |
| 2012 | Galinanes et al ²⁶ | 27 | F | Pfannensteil incision | Y | 2 | Laparoscopic transabdominal suture repair |
| 2012 | Dittmar et al ²⁷ | 69 | F | Right lower abdomen | Y | 1 | Primary suture repair |
| 2016 | Current case | 83 | F | Right paramedian | N | 2 | Primary suture repair |

CONCLUSION

In summary, perforated appendicitis occurring within an incisional hernia is a very unusual phenomenon. Owing to the atypical presentation, a high index of suspicion is required and radiological adjuncts such as CT scans may be particularly useful for diagnosis. Prompt surgical intervention is crucial to prevent spread of sepsis beyond the confines of the hernia sac. Placement of mesh in a contaminated field is not advised due to the potential risk of mesh infection, which can have catastrophic consequences.

Funding: No funding sources

Conflict of interest: None declared

Ethical approval: Not required

REFERENCES

1. Amyand C. VIII. Of an inguinal rupture, with a pin in the appendix coeci, incruised with stone; and some observations on wounds in the guts. Philosophical Transactions. 1735 Jan 1;39(443):329-42.
2. Fernando J, Leelaratna S. Amyand's hernia. Ceylon Med J. 2002;47(2):71.
3. Thomas WE, Vowles KD, Williamson RC. Appendicitis in external herniae. Ann Royal Coll Surg Eng. 1982;64(2):121-2.
4. D'Alia C, Schiavo ML, Tonante A, Taranto F, Gagliano E, Bonanno L, et al. Amyand's hernia: case report and review of the literature. Hernia. 2003;7(2):89-91.

5. Thomas MP, Avula SK, England R, Stevenson L. Appendicitis in a Spigelian hernia: an unusual cause for a tender right iliac fossa mass. *Anno Royal Coll Surg Eng.* 2013;95(4):e1-3.
6. Huntington JT, Mansfield SA, Drosdeck JM, Zhang G, Evans DC. A case of a strangulated umbilical hernia causing gangrenous appendicitis. *Inter J Colorectal Dis.* 2016;31(5):1075-6.
7. Archampong EQ. Strangulated obturator hernia with acute gangrenous appendicitis. *Brit Med J.* 1969;1(5638):230.
8. Horgan PG, O'Donoghue J, Courtney D. Perforated appendicitis in an incisional hernia. *Irish J Med Sci.* 1991;160(11):350-1.
9. Logan MT, Nottingham JM. Amyand's hernia: a case report of an incarcerated and perforated appendix within an inguinal hernia and review of the literature. *Am Surg.* 2001;67(7):628-9.
10. Ebaugh EP, Hessel K, Udobi K. Appendiceal perforation, necrotizing groin infection and spermatic cord necrosis in a case of Amyand's hernia. *Inter J Surg Case Rep.* 2016;24:172-4.
11. Menenakos C, Tsilimparis N, Guenther N, Braumann C. Strangulated appendix within a trocar site incisional hernia following laparoscopic low anterior rectal resection. A case report. *Acta Chirurgica Belgica.* 2009;109(3):411-3.
12. Al-Hadithy N, Erotocritou P, Portou MJ, Hamilton H. Appendicitis in an incisional hernia after radical nephrectomy: a case report. *Ann Royal Coll Surg Eng.* 2010;92(6):e23-4.
13. Sugrue C, Hogan A, Robertson I, Mahmood A, Khan WH, Barry K. Incisional hernia appendicitis: A report of two unique cases and literature review. *Inter J Surg Case Rep.* 2013;4(3):256-8.
14. Creese PG. The first appendectomy. *Surgery, Gynecology Obstetrics.* 1953;97(5):643-52.
15. Sharma H, Gupta A, Shekhawat NS, Memon B, Memon MA. Amyand's hernia: a report of 18 consecutive patients over a 15-year period. *Hernia.* 2007;11(1):31-5.
16. Maizlin ZV, Mason AC, Brown C, Brown JA. CT findings of normal and inflamed appendix in groin hernia. *Emerg Radiol.* 2007;14(2):97-100.
17. Losanoff JE, Basson MD. Amyand hernia: what lies beneath-a proposed classification scheme to determine management. *Am Surg.* 2007;73(12):1288-90.
18. Losanoff JE, Basson MD. Amyand hernia: a classification to improve management. *Hernia.* 2008;12(3):325-6.
19. Meinke AK. Appendicitis in groin hernias. *J Gastrointes Surg.* 2007;11(10):1368-72.
20. Weber RV, Hunt ZC, Kral JG. Amyand's hernia: etiologic and therapeutic implications of two complications. *Surg Rounds.* 1999;22:552-6.
21. Çelik A, Ergün O, Özbek SS, Dökümcü Z, Balık E. Sliding appendiceal inguinal hernia: preoperative sonographic diagnosis. *J Clin Ultrasound.* 2003;31(3):156-8.
22. Coulier B, Pacary J, Broze B. Sonographic diagnosis of appendicitis within a right inguinal hernia (Amyand's hernia). *J Clin Ultrasound.* 2006;34(9):454-7.
23. Akfırat M, Kazez A, Serhatlıoğlu S. Preoperative sonographic diagnosis of sliding appendiceal inguinal hernia. *J Clin Ultrasound.* 1999;27:156-8.
24. Luchs JS, Halpern D, Katz DS. Amyand's hernia: prospective CT diagnosis. *J Computer Assisted Tomography.* 2000;24(6):884-6.
25. Constantine S. Computed tomography appearances of Amyand hernia. *J Computer Assisted Tomography.* 2009;33(3):359-62.
26. Galiñanes EL, Ramaswamy A. Appendicitis found in an incisional hernia. *J Surg Case Reports.* 2012;2012(8):3.
27. Dittmar Y, Scheuerlein H, Götz M, Settmacher U. Adherent appendix vermiformis within an incisional hernia after kidney transplantation mimicking acute appendicitis: report of a case. *Hernia.* 2012;16(3):359-61.
28. Ofili OP. Simultaneous appendectomy and inguinal herniorrhaphy could be beneficial. *Ethiop Med J.* 1991;29(1):37-8.
29. Saggarr VR, Singh K, Sarangi R. Endoscopic total extraperitoneal management of Amyand's hernia. *Hernia.* 2004;8(2):164-5.
30. Candage R, Jones K, Luchette FA, Sinacore JM, Vandevender D, Reed II RL. Use of human acellular dermal matrix for hernia repair: friend or foe?. *Surg.* 2008;144(4):703-11.
31. McKay DW. Vermiform appendix in right upper quadrant incisional hernia. *ANZ J Surg.* 2005;75(8):729-30.
32. Sayles M, Courtney E, Younis F, O'Donovan M, Ibrahim A, Fearnhead NS. Appendiceal mucinous adenocarcinoma presenting as an enterocutaneous fistula in an incisional hernia. *BMJ Case Reports.* 2010;2010:bcr1120092472.
33. Das S, Sarkar S, Ghosh M, De U. Eviscerated 'amyand' incisional hernia. *J IMA.* 2011;43(2):80.
34. Latyf R, Slater R, Garner JP. The vermiform appendix presenting in a laparoscopic port site hernia. *J Minimal Access Surg.* 2011;7(3):181.

Cite this article as: Kabir T, Yong WK. Perforated appendicitis with peri-appendicular abscess within an incisional hernia: a report of an unusual case. *Int Surg J* 2019;6:299-303.