

## Case Report

# A rare case of laparoscopic repair of incarcerated femoral hernia in patient of rheumatic heart disease with double valve replacement

Sachin Ambekar, Mrinal Shankar\*

Department of Minimal Access Surgery, Moolchand Medcity, New Delhi, India

**Received:** 10 June 2018

**Accepted:** 15 June 2018

**\*Correspondence:**

Dr. Mrinal Shankar,

E-mail: [ms\\_surg@yahoo.co.in](mailto:ms_surg@yahoo.co.in)

**Copyright:** © the author(s), publisher and licensee Medip Academy. This is an open-access article distributed under the terms of the Creative Commons Attribution Non-Commercial License, which permits unrestricted non-commercial use, distribution, and reproduction in any medium, provided the original work is properly cited.

### ABSTRACT

Femoral hernias are very rare presentation in comparison to inguinal hernia. Femoral hernias are a protrusion of the peritoneal sac covered with an extraperitoneal pad of fat through the femoral canal. Mostly an acquired condition often with incarceration or strangulation. Laparoscopic repair of femoral hernia has a learning curve for surgeons and now being preferred by majority surgeons to the conventional open repair. We report a case of a 65 year female as a high risk case of rheumatic heart disease who had underwent double valve replacement in recent, was undertaken for total laparoscopic extraperitoneal repair with meshplasty for the incarcerated femoral hernia on left side, with faster recovery of patient postoperatively. Laparoscopic repair of a femoral hernia reduces the risk of reoperation for a recurrence compared with open repair.

**Keywords:** Femoral hernia, Faster recovery, Laparoscopic repair

### INTRODUCTION

Presentation of femoral hernia are very rare compared to inguinal hernia. Mostly an acquired condition, often associated with incarceration or strangulation. More common in females.<sup>1</sup> The fundamental aetiology of femoral hernias is an enlarged femoral ring.

The lacuna vasorum increases in size in both sexes from birth to old age. This may account for the increased incidence in elderly patients. The lacuna musculorum decreases in size with age, possibly explaining the comparatively increased incidence in elderly men.

Theories on the cause of femoral hernias include the existence of a congenital preformed sac, an acquired aetiology and anatomical variations of the femoral canal together with acquired aetiological factors.<sup>2</sup> Laparoscopic approach for repair of femoral hernia is gaining

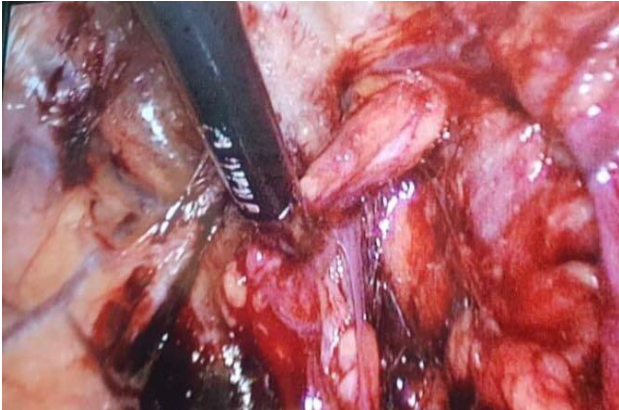
popularity and has lower recurrence rates, lower post-op pain and shorter stay. The conflict of laparoscopic hernia repair over the open approach is the added cost of procedure and that a general anaesthesia is almost always necessary.

The principal reasons for the long learning curve in laparoscopic hernia repair are the surgeon's lack of familiarity with the preperitoneal anatomy and the time it takes to develop the skills to operate in a confined space.<sup>3</sup>

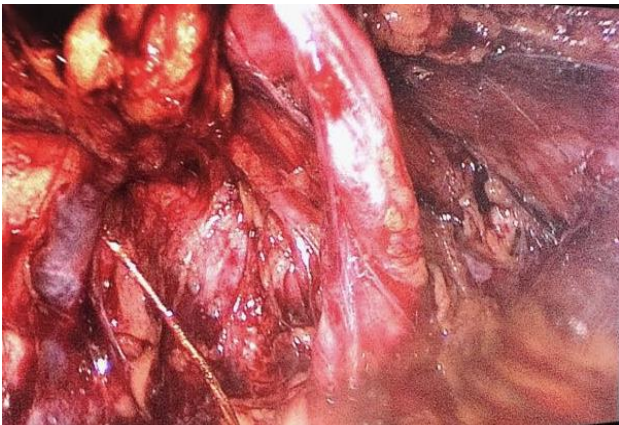
### CASE REPORT

A 65 year female presented with buldge over left femoral region. No acute abdomen or signs of SAIO. Known high risk case of Rheumatic Heart Disease and had underwent Double Valve Replacement in recent past. We planned for laparoscopic repair. Total laparoscopic extraperitoneal repair with meshplasty was done under

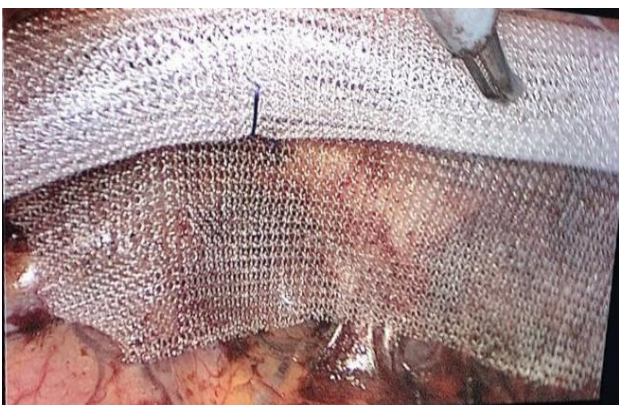
GA with operating time under 1 hour. Patient had a faster recovery and was discharged after 1 day. In follow up, patient had no further issue.



**Figure 1: Femoral hernia being reduced medial to the round ligament.**



**Figure 2: Complete reduction of femoral sac.**



**Figure 3: Mesh covering the femoral defect and the inguinal orifice as well.**

## DISCUSSION

Femoral hernias account for less than 5% of all hernias, occur just below the inguinal ligament, when abdominal contents pass through a naturally occurring weakness

called the femoral canal. The etiology of femoral hernia has been controversial, the acquired theory is widely accepted, however, the true cause of femoral hernia is not known.<sup>4</sup>

They are more common in females because of the wider pelvis and are more common in multiparous females. An enlarged femoral ring is thought to be the cause of the femoral hernia. Elevated intra-abdominal pressure caused by constipation, bronchitis, and pregnancy is considered to be the prime etiologic factor.<sup>5</sup>

Clinically a small irreducible soft mass is palpated means that incarceration of the hernia sac is present. Making the diagnosis become even more difficult when the femoral hernia sac is large, it frequently turns upwards and mimics an inguinal hernia. Strangulation also occurs more frequently in femoral hernia than the inguinal hernia and causes acute abdominal pain and small bowel obstruction. Richter's hernia sometimes occurs in femoral hernia and strangulation of the small intestine usually follows. It is difficult to make an early diagnosis of Richter's hernia before the necrosis of the strangulated small intestine begins.<sup>6</sup>

Lockwood's infra-inguinal approach, Lotheissen's transinguinal approach and McEvedy's high approach are the three approaches of repair in open surgery. Lockwood's approach is the chosen method for elective repair and McEvedy's approach is preferred in the emergency setting when strangulation is suspected as this allows better access for visualisation of bowel and possible resection if needed.<sup>7</sup>

Laparoscopic repair involves the extraperitoneal (TEP) or transabdominal preperitoneal (TAPP) approach. While there is good evidence for this method of repair it is still not the standard of care as it involves more time and laparoscopic skills. The advantages are a lower recurrence, superior mesh fixation, lower post-op pain and shorter stay.<sup>8</sup>

In high risk patients and Emergency, still open repair is preferred over laparoscopic repair, the conflict measures are there among surgeons. Our experience makes believe that even in high risk patients, laparoscopic repair can be taken with all preoperative preparations on mind. Although the operating time in high risk patients has to be kept less, thus laparoscopic repair demands long learning curve for surgeons.<sup>9</sup>

For any operation there are risks, and in particular there is a risk of infection, bleeding and injury. The overall risk of major complications is less than 1%. The specific risks in laparoscopic hernia repair are bleeding and injury to abdominal structures or organs. Surgery is required generally to repair these, and sometimes extensive surgery. The risks of the surgery are greater if there is scar tissue from previous surgery or conditions that have resulted in the matting down of adjacent structures. The

most common outcome is no complications or a minor problem that will pass such as wound infection.<sup>10</sup>

## CONCLUSION

Laparoscopic repair for femoral hernia should be preferred instead of conventional open repair for its lower recurrence rates and faster recovery, although it requires a learning curve for surgeon.

*Funding: No funding sources*

*Conflict of interest: None declared*

*Ethical approval: Not required*

## REFERENCES

1. Yang XF, Liu JL. Laparoscopic repair of femoral hernia. *Ann Translational Med.* 2016 Oct;4(19).
2. Henriksen NA, Thorup J, Jorgensen LN. Unsuspected femoral hernia in patients with a preoperative diagnosis of recurrent inguinal hernia. *Hernia* 2012;16:381-5.
3. Cox TC, Huntington CR, Blair LJ, Prasad T, Heniford BT, Augenstein VA. Quality of life and outcomes for femoral hernia repair: does laparoscopy have an advantage?. *Hernia.* 2017 Feb 1;21(1):79-88.
4. Pillay Y. Laparoscopic repair of an incarcerated femoral hernia. *Int J Surg Case Reports.* 2015 Jan 1;17:85-8.
5. Sarosi Jr GA, Kfir Ben-David MD, Turnage R, Collins KA. Laparoscopic inguinal and femoral hernia repair in adults. *InUptoDate* 2015. UptoDate, Waltham, MA;2015.
6. Rosemar A, Angerås U, Rosengren A. Body mass index and groin hernia: a 34-year follow-up study in Swedish men. *Ann Surg.* 2008;247:1064-8.
7. Read RC. Crucial steps in the evolution of the preperitoneal approaches to the groin: an historical review. *Hernia.* 2011;15(1):1-5.
8. Kouchupapy RT, Ranganathan G, Dias S, Shanahan D. Aetiology of femoral hernias revisited: bilateral femoral hernia in a young male (two cases). *The Annals Royal Coll Surg England.* 2013 Jan;95(1):e14-6.
9. Pahwa HS, Kumar A, Agarwal P, Agarwal AA. Current trends in laparoscopic groin hernia repair: A review. *WJCC.* 2015 Sep;3(9):789.
10. Andresen K, Bisgaard T, Kehlet H, Wara P, Rosenberg J. Reoperation rates for laparoscopic vs open repair of femoral hernias in Denmark: a nationwide analysis. *JAMA Surg.* 2014;149:853-7.

**Cite this article as:** Ambekar S, Shankar M. A rare case of laparoscopic repair of incarcerated femoral hernia in patient of rheumatic heart disease with double valve replacement. *Int Surg J* 2018;5:2639-41.