

## Case Report

# Is regional anesthesia a safe technique for patients with severe ankylosing spondylitis undergoing total hip replacement surgery?

Elif Copuroglu\*, Gonul Sagiroglu

Department of Anesthesiology, Trakya University, Faculty of Medicine, Edirne, Turkey

**Received:** 25 May 2018

**Accepted:** 27 June 2018

**\*Correspondence:**

Dr. Elif Copuroglu,

E-mail: [elifcopuroglu@hotmail.com](mailto:elifcopuroglu@hotmail.com)

**Copyright:** © the author(s), publisher and licensee Medip Academy. This is an open-access article distributed under the terms of the Creative Commons Attribution Non-Commercial License, which permits unrestricted non-commercial use, distribution, and reproduction in any medium, provided the original work is properly cited.

### ABSTRACT

**Background:** Authors report two cases of regional anesthesia management whom were scheduled for total hip replacement surgery due to ankylosing spondylitis.

**Methods:** Mouth opening, and cervical spine movements were limited. Cervical osteophytes have been recognized to cause distortion of the airway and can lead to unexpected difficulties during intubation.

**Results:** In present first case report we described continuous spinal anesthesia for a patient with severe ankylosing spondylitis. We achieved successful anesthesia using epidural catheter by insertion of spinal area. Awake epidural anesthesia management was described in second case of the study.

**Conclusions:** Authors suggest that regional anesthesia can be safely and effectively used as an alternative to general anesthesia in patients with ankylosing spondylitis.

**Keywords:** Ankylosing spondylitis, Epidural anaesthesia, Spinal anaesthesia

### INTRODUCTION

Ankylosing spondylitis (AS) is a chronic progressive multisystemic disease form of seronegative spondyloarthropathy. Patients with AS have arthropathies and they have many extra-articular manifestations.

Several textbooks of anaesthesia consider that whether general (GA) or regional anesthesia (RA) is hazardous for the patients with AS.<sup>1</sup> The following two case reports describe the successful anaesthetic management of total right hip replacement surgery using continuous spinal anaesthesia in patients with severe AS.

Rigid posture and restricted neck movements of the patients with ankylosing spondylitis leads difficulties in the administrations of general and neuraxial regional anaesthesia.<sup>2</sup> Possible temporomandibular joint disease

challenges for anesthesiologists particularly about airway management.<sup>3</sup>

New airway managements such as awake video laryngoscopic intubation and laryngeal mask applications, lateral approach applications of neuroaxial regional anesthesia as well as the standard general and neuraxial techniques were defined for these patients.<sup>4</sup>

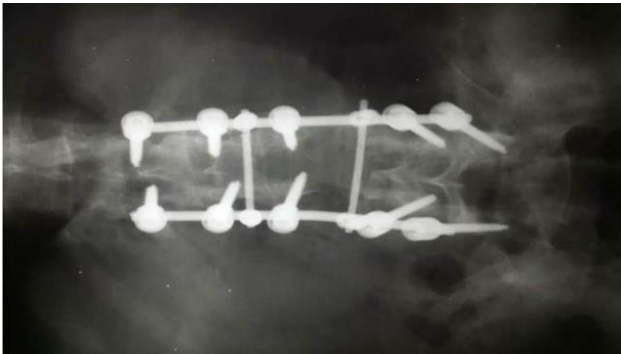
Giving ideal position for the administration of regional anesthesia is very difficult due to the ossification of ligaments around the vertebral column.<sup>5</sup> Limited movements of the cervical spine and the temporomandibular joint causes difficult airway management.<sup>6</sup>

Spinal anaesthesia is an acceptable alternative to general anaesthesia for perineal or lower limb surgeries for the patients with ankylosing spondylitis.<sup>7,8</sup>

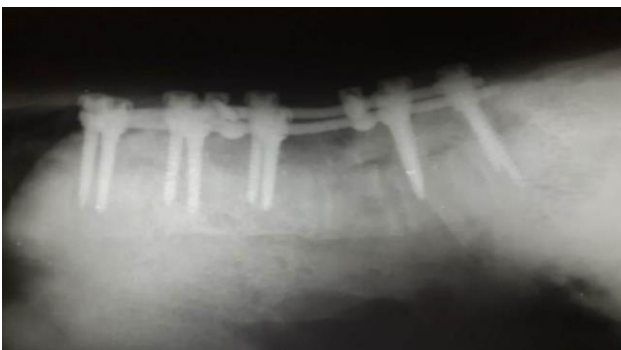## CASE REPORT

### Case 1

A 47-years old man weight 77 kg, height 183 cm with 14-years history of AS having difficult airway was admitted for total right hip replacement. He had previously undergone surgery because of lumbar spondylolisthesis 14-years ago. Examination showed that he had a full set of teeth, his chin was touching his chest and mouth opening was limited. Mallampati score was 4. He also demonstrated thyromental distance of 3 cm. History and physical examination suggested that there was severe cervical AS involving the thoraco-lumbar vertebral column posterior anterior (Figure 1) and lateral (Figure 2). Due to spondylolisthesis surgery, there was a 20 cm scar tissue on the patient's back. The patient has preferred GA for the first choice, although he had an approval for both GA and RA methods. But he rejected to give an approval for tracheostomy in case of any need.



**Figure 1: The thoraco-lumbar vertebral column posterior anterior.**



**Figure 2: The thoraco-lumbar vertebral column lateral.**

Authors induced general anaesthesia with propofol 3 mg/kg and rocuronium 0.6 mg/kg, but neither the introducer tool nor a finger sweep technique was successful in placing laryngoscopy. Due to bleeding in the mouth, anatomical structures couldn't be viewed with fiberoptic bronchoscope. It was unsuccessful. His venous blood gases parameters were pO<sub>2</sub>: 35 mmHg, pCO<sub>2</sub>: 41.9 mmHg, pH: 7.30, haemoglobin: 9.8 g/dL, haematocrit:

29%, SpO<sub>2</sub>: 59.7%, Na: 140 mmol/L, K: 3.24 mmol/L, Ca: 1.029 mmol/L, glucose: 147 mg/dL, lactate: 1.9 mmol, HCO<sub>3</sub>: 20.2 mmol/L, base excess: -6.4. Peripheral pulse oxymetre (SpO<sub>2</sub>) was 40%. Heart rate decreased to 40 pulse/min and bradycardia was treated with 1 mg atropine. The patient was decided to awake to continue with epidural anaesthesia, although he had previously undergone operation from lumbar area.

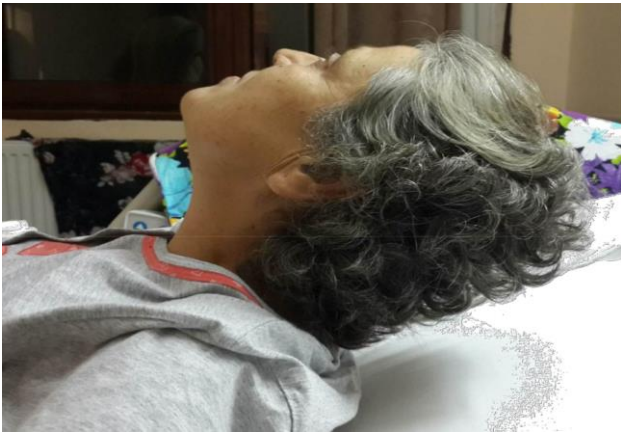Then sugammadex 4mg/kg was used to reverse neuromuscular blockade. His spontaneous breathing returned with a rate of 14 and 400-460 mL per minute, in few seconds. The hemodynamic data including mean arterial pressure (MAP), heart rate, SpO<sub>2</sub>, respiratory rate values were normal. The patient was placed in a sitting position for the procedure, and an epidural needle was placed in the L3-4 interspace in the midline using an 18G Tuohy needle via the saline loss of resistance technique. But cerebrospinal fluid was seen during aspiration and 0.5% isobaric bupivacaine 3 mL was administered to spinal space. Then we decided to place epidural catheter in to spinal space thinking that the replacement of the catheter to epidural place would be more difficult and we had failed airway management according to anatomical malformations. This resulted in a sensory and motor block from T<sub>6-7</sub>.

Monitoring included electrocardiography, non-invasive arterial blood pressure and pulse oximetry. Supplementary oxygen was administered continuously during the surgical procedure. During the operation, signs for bradycardia, hypotension were followed and if there is no deterioration in hemodynamical data (hypoventilation (less than 8 breaths per minute), apnea (not breathing for 30 seconds), airway obstruction, hypotension (a 30% reduction from baseline MAP value), arrhythmia, bradycardia (<50 beats/min)) was followed. On preoperative crystalloid 4000 mL and colloid 1000 mL fluid was given. When the MAP decreases below 20% of baseline MAP, dopamine was started to give at 2-5 µg/kg/min. There were no intraoperative problems except hypotension and surgery was performed successfully within four hours. One hour before the end of the operation, 0.5% isobaric bupivacaine was given only once. He was comfortable and without pain during the operation. After operation he was admitted in intensive care unit (ICU) for postoperative care. He stayed in ICU for 24 hours. He had hypotension at 4<sup>th</sup> and 11<sup>th</sup> hours in ICU. Fluid replacement therapy was successful for the treatment of hypotension. Without head headache paracetamol were administered (three times daily 1000 mg intravenously). There was no complication during hospitalization. He was discharged one week after operation.

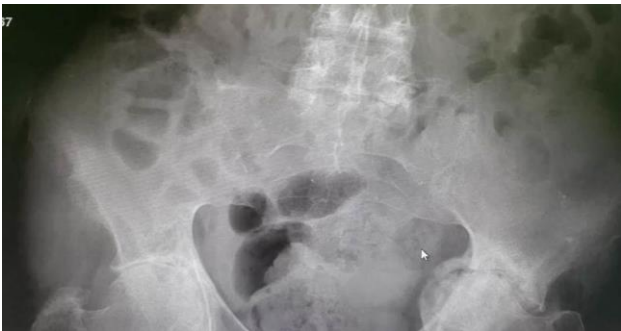### Case 2

A 49-years old woman, weight 72 kg, height 164 cm with AS was admitted for total hip replacement. She had a history of hypertensive heart failure and she had

previously undergone surgery of umbilical hernia after failed attempts to achieve general anesthesia with orotracheal intubation using a fiberoptic bronchoscope, so that we planned regional anesthesia for this case. On physical examination she had a full set of teeth, her mouth opening is normal, her chin was barely touching her chest. Mallampati score was 3. Her thyromental distance was 6 cm. Her occiput to wall distance was 18 cm (Figure 3). Ankylosing is a detectable in both sacroiliac joints and there is typical appearance of bamboo spine (Figure 4). The patient was informed about anesthesia methods and she signed an approval for both RA and GA methods. Authors planned epidural anesthesia.



**Figure 3: Short thyromental distance and restricted neck movement.**



**Figure 4: Typical appearance of bamboo spine.**

Authors administered midazolam 2 mg intravenously for premedication. The patient was placed in lateral decubitus position for the procedure, an epidural catheter was placed in the L<sub>3-4</sub> interspace in the midline using an 18G Tuohy needle via the saline loss of resistance technique. 0.5% isobaric bupivacaine of 6 mL and 50 µg Fentanyl was administered into epidural space. This resulted in a sensory from T<sub>6-7</sub>.

Monitoring included electrocardiography, non-invasive arterial blood pressure and pulse oximetry. Supplementary oxygen was administered continuously during the surgical procedure. The operation was lasted 3

hours without an event. The patient was comfort and without pain during the operation. After operation she was transferred to the orthopedic clinic with epidural patient-controlled anesthesia (PCA) installed. The patient had slight pain after detaching the PCA. There was no complication during hospitalization. She was discharged one week after operation.

## DISCUSSION

Both GA and RA managements of the patients having AS is challenging due to the clinical manifestations of this syndrome. Those patients have abnormal cervical spine, extremely limited neck mobility, and limited mouth opening related with temporo-mandibular joint involvement. So that anesthetists have troubles for intubating those patients and most of the clinicians prefer an awake fibreoptic for securing the airways.<sup>9</sup> Awake fibreoptic technique couldn't be applied in our first case, because the patient wanted to do it under GA.

Po-Kai Wang's study showed that how the patient nasally intubated in the lateral position by using laryngeal mask (LMA) and GlideScope.<sup>10</sup> But there was a mouth opening bigger than 4cm on the patient. And nasally intubation was done by placing LMA which allowed to ventilation. But in our first case there was a limited mouth opening so, neither LMA nor laryngoscopy was placed and anatomical structures with fiber optics couldn't be fully displayed. Tracheostomy may also fail on the patient with severe AS was highlighted on the a Parasai et al study.<sup>11</sup> Authors could have tried trachestomy such a case like that, but it wasn't done because of the refusal of the patient.

Neuraxial anesthesia can be preferred rather than GA in patients with AS. Placement of epidural or spinal needles is nearly impossible due to syndesmophytes between adjacent vertebrae and ossification of the interspinous ligament and ligamentum flavum. Different methods of neuraxial anesthesia, including epidural anesthesia through the caudal canal or the lateral approach method for spinal anesthesia have been suggested.<sup>12</sup> Each of these techniques has its own difficulties such as intraosseous puncture and injection can be accidentally done during caudal anesthesia resulting systemic toxic reactions.<sup>13</sup> The use of single-shot spinal anesthesia in patients with AS has been reported, although total spinal anesthesia has been described most likely due to stenotic intrathecal spaces. Restricted flexion of the lumbar spine and ossification of interspinous ligaments of those patients often make the placement of epidural catheter difficult and may leads to complete failure.<sup>14</sup> The complications of the epidural catheter placement are also common, including spinal hematomas.<sup>15</sup> Neuraxial anaesthesia may cause higher incidence of spontaneous epidural haematoma in patients with AS.<sup>16</sup> Even the patient was operated in his lumbar area in our case, authors easily entered the spinal range with epidural needle and there was no complication recorded. The spinal anesthesia

which made on subarachnoid space with epidural needle and catheter was placed, the patient didn't feel any pain. There were no complications recorded other than hypotension in his perioperative follow-ups. There was no complication recorded other than hypotension which responded to the treatment of fluid without vasopressor and inotropic in the ICU readings. Studied second case awake epidural anesthesia was managed successfully without any complication perioperatively. The patients were discharged from the hospital without any neurological deficits.

## CONCLUSION

Authors describe two cases with severe AS. First one had an extremely difficult airway in whom an epidural catheter was successfully induced for continue spinal anesthesia. The second case with awake epidural anesthesia. Authors suggest that RA can be safely and effectively used as an alternative to general anesthesia in patients with ankylosing spondylitis. Moreover, this report adds to literature supporting the safety and efficacy of RA in specific clinical situations.

*Funding: No funding sources*

*Conflict of interest: None declared*

*Ethical approval: Not required*

## REFERENCES

1. McKenzie PJ, Blogg CE. Orthopaedic and plastic surgery. In: Nimmo WS, Smith G eds. Anaesthesia, Oxford, Blackwell Scientific Publications;1989:721.
2. Sinclair JR, Mason RA. Ankylosing spondylitis. The case for awake intubation. Anaesthesia. 1984;9(1):3-11.
3. Wang PK, Luo PH, Chen A, Chen TY, Lai HY. Emergency tracheal intubation in ankylosing spondylitis patient in the lateral position using the GlideScope. Acta Anaesthesiol Taiwan. 2008;46(2):80-1.
4. Prasai A, Jani P, Jones G. Failed intubation in a patient with long-standing ankylosing spondylitis. J Clin Rheumatol. 2008;14(2):127.
5. Kumar CM, Mehta M. Ankylosing spondylitis: lateral approach to spinal anaesthesia for lower limb surgery. Can J Anaesth. 1995;42(1):73-6.
6. Weber S. Caudal anesthesia complicated by intraosseous injection in a patient with ankylosing spondylitis. Anesthesiol. 1985;63(6):716-7.
7. Schelew BL, Vaghadia H. Ankylosing spondylitis and neuraxial anaesthesia - a 10 year review. Can J Anaesth. 1996;43(1):65-8.
8. Wulf H. Epidural anaesthesia and spinal haematoma. Can J Anaesth. 1996;43(12):1260-71.
9. Van de Straete S, Demaerel P, Stockx L, Nuttin B. Spinal epidural haematoma and ankylosing spondylitis. J Belge Radiol. 1997;80(3):109-10.
10. Hoffman SL, Zaphiratos V, Girard MA, Boucher M, Crochetière C. Failed epidural analgesia in a parturient with advanced ankylosing spondylitis: a novel explanation. Canad J Anesthesia. 2012;59(9):871-4.
11. Raval C, Patel P, Kharod U. Retrograde intubation in a case of ankylosing spondylitis posted for correction of deformity of spine. Saudi J Anaesth. 2010;4(1):38-41.
12. Goktug AO, Basar H, Turkyılmaz E, Bakkal K, Baltacı B. Management of anesthesia in patient with ankylosing spondylitis. Turk J Anaesth Reanim. 2008;36:182-6.
13. Woodward LJ, Kam PC. Ankylosing spondylitis: recent developments and anaesthetic implications. Anaesthesia. 2009;64(5):540-8.
14. Balcı ŞC, Türköz A, Çınar Ö, Bircan HC, Sekmen Ü. Alternative anaesthetic management in ankylosing spondylitis. AĞRI 2014;26:196-7.
15. Kotekar N, Nagalakshmi NV, Gururaj, Rehman M. A case of severe ankylosing spondylitis posted for hip replacement surgery. Indian J. Anaesth 2007;51(6):546-9.
16. Woodward LJ, Kam PC. Ankylosing spondylitis: Recent developments and anaesthetic implications. Anaesthesia 2009;64:540-8.

**Cite this article as:** Copuroglu E, Sagiroglu G. Is regional anesthesia a safe technique for patients with severe ankylosing spondylitis undergoing total hip replacement surgery?. Int Surg J 2018;5:2913-6.