

## Case Report

# Challenges for endocrine surgeons: management of a colossal normotensive pheochromocytoma

Zahir Hussain, Jabamalai Ferdinand\*, Senthilkumar M. S., Kumaran M. P., Saivishnupriya V.

Department of Endocrine Surgery, Madras Medical College, Chennai, Tamil Nadu, India

**Received:** 13 May 2018

**Accepted:** 05 June 2018

**\*Correspondence:**

Dr. Jabamalai Ferdinand,

E-mail: [ferdinand1331@gmail.com](mailto:ferdinand1331@gmail.com)

**Copyright:** © the author(s), publisher and licensee Medip Academy. This is an open-access article distributed under the terms of the Creative Commons Attribution Non-Commercial License, which permits unrestricted non-commercial use, distribution, and reproduction in any medium, provided the original work is properly cited.

### ABSTRACT

Although the presentation of pheochromocytoma is remarkably protean, it usually presents as sustained or paroxysmal hypertension with triad of headache, palpitation and diaphoresis. The incidence of serendipitously discovered pheochromocytoma is approximately 4% to 8%. Perioperative management of such cases are not only controversial but also poses infallible challenges to the surgeon. This case report intends to highlight an unusual presentation of asymptomatic, normotensive pheochromocytoma as a huge abdominal mass and its management.

**Keywords:** Asymptomatic, Perioperative management, Pheochromocytoma, Normotensive

### INTRODUCTION

Pheochromocytoma is a potentially life-threatening condition which usually manifest as triad of palpitation, headache and diaphoresis. Albeit hypertension, sustained or paroxysmal is the principal presentation of pheochromocytoma, approximately half of the patients will be normotensive.<sup>1</sup> At this time, 10% to 49% of pheochromocytoma are incidentally detected during imaging studies for unrelated reasons.<sup>2</sup> Pheochromocytomas constitute 4% to 8% of incidentally detected adrenal masses.<sup>3</sup>

The unrestrained production of catecholamines by pheochromocytoma can precipitate physiological effects including vasoconstriction, hypovolemia, arrhythmias and severe left ventricular dysfunction. Discrepant management of such cases can lead to very dangerous catecholamine storm.

Hence perioperative management of normotensive cases are not only controversial but also poses infallible challenges to the surgeon. The key issues in the management of such patients are whether to start a

blocker and the need for volume expansion. We intend to highlight an unusual presentation of normotensive pheochromocytoma as huge abdominal mass and its management.

### CASE REPORT

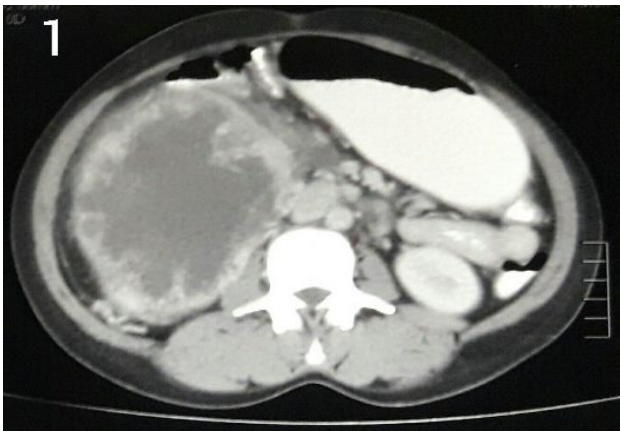
A 30-year-old female was detected to have an abdominal mass on routine gynaecological ultrasound suspected to arise from right adrenal gland and was referred to outpatient department of Endocrine Surgery Madras Medical College. On inquiry, she recalled experience of vague abdominal discomfort for past 3 months without any ratifying complaints.

Her blood pressure documented on multiple occasions was normal without any postural variation. She did not have any features of androgenic excess or any evidence of cushing's syndrome or neurocutaneous markers. General examination, past treatment and family history were non-contributory.

On abdominal examination a large mass measuring approximately 20x16x12cm was palpable occupying the

entire right hypochondrium, lumbar and epigastric region, the upper and lateral borders of the mass were not palpable. The mass was firm in consistency, non-tender and the mobility was restricted.

With a clinical diagnosis of adrenal incidentaloma, contrast enhanced computed tomography (CECT) was done which unravelled large heterodense lesion measuring 21x16x14cms with irregular peripheral enhancement and necrotic areas which was pushing the right kidney inferiorly, gall bladder anteriorly and inferior venacava medially, right adrenal gland was not separately visualised (Figure 1). Ultrasound neck was normal.



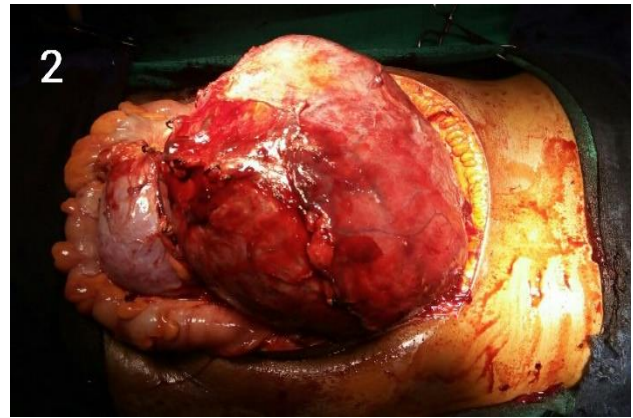
**Figure 1: CECT image showing large Adrenal mass.**

Relevant Biochemical investigations were done which showed Serum potassium of 4.3mEq/L (3.5-5.5), serum calcium of 10.2mg/dl (9-11), 24-hour urinary normetanephrine of 1593µg/24 hour (<600) and metanephrine of 410.4µg/24 hours (<350), over-night dexamethasone suppression test did not reveal any abnormality, plasma aldosterone concentration of 5.7ng/dl (2.52-23.2) and plasma renin activity of 0.4ng/ml/hour (1.6-7.4) with aldosterone renin ratio of 1.425ng/dl per ng/ml/hour and Dehydroepiandrosterone-sulphate level of 120µg/dl (<350).

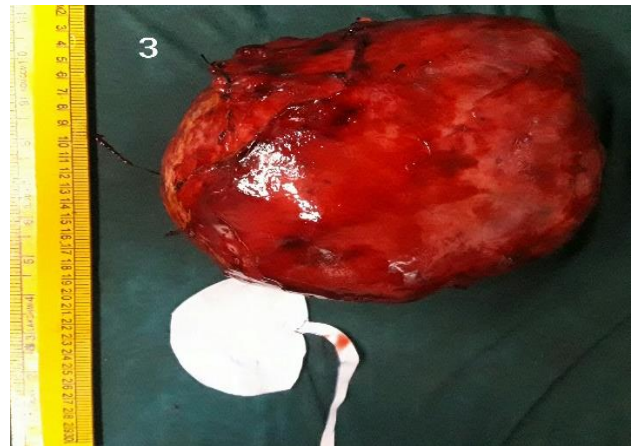
Having accordingly diagnosed right adrenal pheochromocytoma, the patient was prepared for surgery and was advised increased fluid intake as well as cautiously started on  $\alpha$ -blocker prazosin to prevent hypertensive crisis during surgery, adequate  $\alpha$ -blockade was established by the occurrence of nasal stuffiness, orthostatic hypotension and tachycardia. After achieving adequate  $\alpha$ -blockade, salt ad lib (>5 g/day) and  $\beta$ -blockers was added to counteract the orthostatic hypotension and tachycardia induced by  $\alpha$ -blockade, respectively.

Patient was taken up for surgery under general anaesthesia which she tolerated well. On laparotomy large well-encapsulated mass arising from right suprarenal area of size 21x16x14 was found pushing the right kidney inferiorly (Figure 2), which was resected

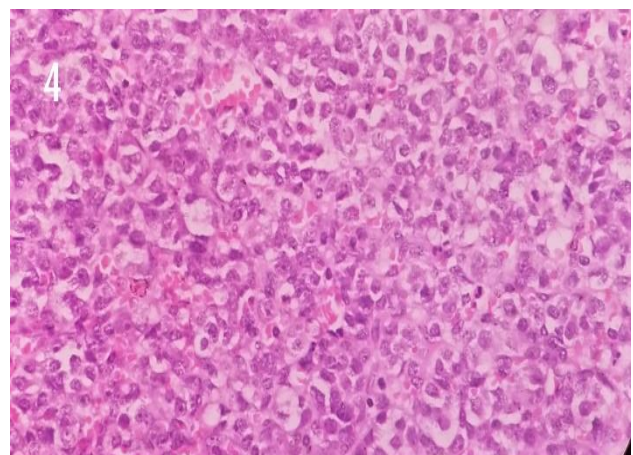
without any complication (Figure 3). Patient was hemodynamically stable throughout the procedure. Postoperative period was uneventful devoid of any fluctuation in blood pressure.



**Figure 2: Intra operative view of the Adrenal mass.**



**Figure 3: Resected specimen.**



**Figure 4: Histopathology showing Zellballen pattern of cells.**

Histopathological examination of tumour on cut section showed necrotic and haemorrhagic areas, on microscopy

revealed neoplastic cells arranged in Zellballen pattern and in cords, the tumour nests were separated by thin fibrovascular septae without any capsular or vascular invasion suggestive of pheochromocytoma (Figure 4), the diagnosis was confirmed by immunohistochemistry. Two weeks post-surgery, 24-hour urinary metanephrine and nor-metanephrine were normal. On six-month follow-up patient is normal without any evidence of recurrence.

## DISCUSSION

Clinically inapparent adrenal masses or incidentalomas, are unveiled through imaging done for unrelated non-adrenal disease. Pheochromocytoma is believed to be found in 0.05% to 0.1% of patients with sustained hypertension.

Nevertheless, afore mentioned accounts only for 50% of people with Pheochromocytoma whereas about half of the patients will have paroxysmal hypertension or will be normotensive.<sup>1</sup> Pheochromocytomas constitute 4% to 8% of all incidentally detected adrenal masses.<sup>3</sup>

Every case of adrenal incidentalomas should be evaluated unless proved otherwise, because the unrestrained production of catecholamines and its excess in the circulation can perpetuate physiological effects including vasoconstriction, hypovolemia, arrhythmias and severe left ventricular dysfunction and can lead to life threatening pheochromocytoma crisis.

The postulated causes for normotensive pheochromocytoma includes increased rate of catecholamine inactivation, down regulation of cardiovascular receptors so that the catecholamine response is blunted and low blood volume due to persistent vasoconstriction. This case was also presented as normotensive pheochromocytoma.

Several authors have described the occurrence of normotensive pheochromocytoma; Agarwal A et al. presented their experience on normotensive pheochromocytoma and justified the use of preoperative  $\alpha$ -blockade in this condition as undertaken for hypertensive pheochromocytoma.<sup>4</sup>

Shao Y et al. in 2011 described preoperative  $\alpha$ -blockade has no advantage in sustaining hemodynamic stability in patients with normotensive pheochromocytoma and can augment the use of vasopressor drugs and colloid infusion.<sup>5</sup> However we advocate  $\alpha$ -blockade prior to surgery because it is imperative to recognize even in normotensive pheochromocytoma abysmal intraoperative hemodynamic fluctuation can occur and result in life threatening pheochromocytoma crisis. In this case preoperative  $\alpha$ -blockade was done and there was no intraoperative need for vasopressor support or fluctuation in blood pressure.

Basso L and colleagues reported the biggest pheochromocytoma of size 29x21x12 cms weighing about 4050 grams with no sign and symptoms of catecholamine excess.<sup>6</sup> There are few published cases of pheochromocytoma larger than 20cm, one of them was reported by Arcos CT et al about malignant pheochromocytoma with largest dimension more than 20cms.<sup>7</sup> In this case report the size of the tumour was 21x16x14 cms weighing about 2230 grams. Histopathology and immunohistochemistry proved the diagnosis of pheochromocytoma.

The absence of metastasis, local invasion and intact capsule confirmed the benign nature of the tumour. Follow up is important and benign Pheochromocytoma has a salutary prognosis, with 5-year survival of greater than 95% and recurrence below 10%.<sup>8</sup>

The present case is under regular followed up and at the end of six months she is in good health without any evidence of recurrence.

## CONCLUSION

The spectrum of presentation of pheochromocytoma is versatile hence any adrenal incidentaloma should be evaluated for pheochromocytoma and should be resourcefully managed in the perioperative period to prevent unwarranted complications.

*Funding: No funding sources*

*Conflict of interest: None declared*

*Ethical approval: Not required*

## REFERENCES

1. Chen H, Sippel RS, O'Dorisio MS, Vinik AI, Lloyd RV, Pacak K. The North American Neuroendocrine Tumor Society consensus guideline for the diagnosis and management of neuroendocrine tumors: pheochromocytoma, paraganglioma, and medullary thyroid cancer. *Pancreas*. 2010;39(6):775-83.
2. Kopetschke R, Slisko M, Kilisli A, Tuschy U, Wallaschofski H, Fassnacht M, et al. Frequent incidental discovery of pheochromocytoma: data from a German cohort of 201 pheochromocytoma. *Eur J Endocrinol*. 2009;161(2):355-61.
3. Mansmann G, Lau J, Balk E, Rothberg M, Miyachi Y, Bornstein SR. The clinically inapparent adrenal mass: update in diagnosis and management. *Endocr Rev*. 2004;25(2):309-40.
4. Agarwal A, Gupta S, Mishra AK, Singh N, Mishra SK. Normotensive pheochromocytoma: institutional experience. *World J Surg*. 2005;29(9):1185-8.
5. Shao Y, Chen R, Shen ZJ, Teng Y, Huang P, Rui WB, et al. Preoperative alpha blockade for normotensive pheochromocytoma: is it necessary? *J Hypertens*. 2011; 29(12):2429-32.

6. Basso L, Lepre L, Melillo M, Fora F, Mingazzini PL, Tocchi A. Giant pheochromocytoma: case report. *Ir J Med Sci.* 1996;165(1):57-9.
7. Arcos CT, Luque VR, Luque JA, Gracia PM, Jimenez AB, Munoz MM. Malignant giant pheochromocytoma: a case report and review of the literature. *Can Urol Assoc J.* 2009;3(6):E89-91.
8. Reisch N, Peczkowska M, Januszewicz A, Neumann H. Pheochromocytoma: presentation

diagnosis and treatment. *J Hypertens.* 2006;24(12):2331-9.

**Cite this article as:** Hussain Z, Ferdinand J, Senthilkumar MS, Kumaran MP, Saivishnupriya V. Challenges for endocrine surgeons: management of a colossal normotensive pheochromocytoma. *Int Surg J* 2018;5:2672-5.