

## Case Report

# Gastrocolic fistula as a complication of percutaneous endoscopic gastrostomy (PEG): a case report and review of literature

Anand Kishore\*

Department of Surgery, RK Life Line Hospital, Sirsa, Haryana, India

**Received:** 04 May 2018

**Accepted:** 29 May 2018

**\*Correspondence:**

Dr. Anand Kishore,

E-mail: [anandkishore1980@gmail.com](mailto:anandkishore1980@gmail.com)

**Copyright:** © the author(s), publisher and licensee Medip Academy. This is an open-access article distributed under the terms of the Creative Commons Attribution Non-Commercial License, which permits unrestricted non-commercial use, distribution, and reproduction in any medium, provided the original work is properly cited.

### ABSTRACT

Gastrocolic fistula is a rare complication which is seen after percutaneous endoscopic gastrostomy (PEG). It usually manifest as a late complication. Interesting fact is that gastrocolic fistula is formed during the initial insertion of PEG tube itself but goes unrecognized. It becomes evident only when a tube replacement is done or when tube dislodgement occurs. We report a case where gastrocolic fistula was recognized after 1 month of tube feeding. Aim of our case report is to make clinicians aware of this rare condition and to have high clinical suspicion regarding possible complications of PEG even after a long period of uncomplicated feeding.

**Keywords:** Fistula, Gastrocolic, Gastrocolocutaneous, Percutaneous endoscopic gastrostomy

### INTRODUCTION

PEG is a minimal invasive procedure done for providing enteral nutrition in patients who are unable to swallow but have an intact gastrointestinal tract. Over the last 40 yrs. it has proven as a safe and effective technique for enteral feeding. Common indications of PEG are patients with neurological disorder, oropharyngeal disorders and terminal stage patients. Less common indications are anorexia, cachexia, recurrent aspiration and esophageal stricture.

Complications associated with PEG are tube dislodgement, wound infection, necrotizing fasciitis, peristomal leak, gastric perforation, hemorrhage and colonic injury.<sup>1</sup>

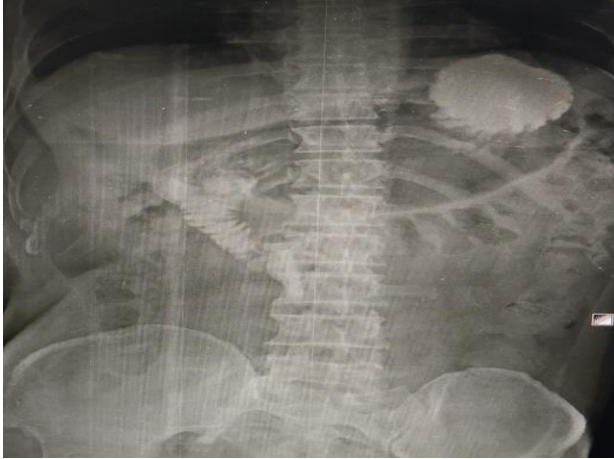Gastrocolic or gastrocolocutaneous fistula is a rare complication associated with PEG and has a late presentation with incidence of 0.5 to 3%.<sup>2</sup> This complication occurs due to penetration of interposed colon, when a PEG tube is placed into the stomach.<sup>3</sup>

Affected patients usually remain asymptomatic for few days to several months because initially feeds get delivered to stomach, therefore the fistula goes unrecognized until the tube is replaced, it dislodges and migrates into colon or until typical symptoms of diarrhea and feculent vomiting occurs.<sup>4</sup>

### CASE REPORT

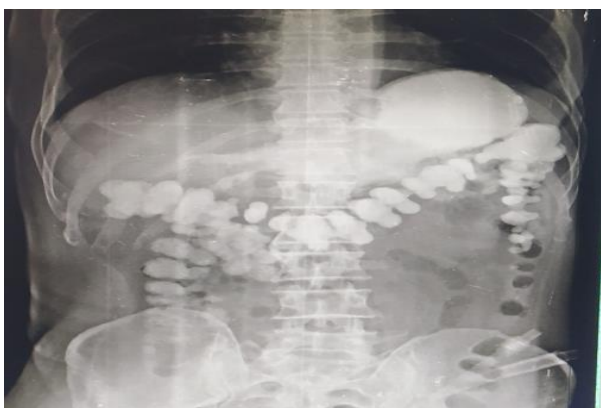a 55 year old male with history of head injury 3 months back who had undergone surgical decompression, was referred to gastroenterology department in our hospital for PEG procedure. Patient was having reduced level of consciousness, was tracheostomized and needed enteral nutrition for a long period. He underwent PEG procedure and it was uneventful. Gastrograffin study was also done through peg tube after completion of procedure, which showed contrast was entering into small bowel (Figure 1). Patient was sent home next day and put on tube feed. He was tolerating the feed well. There was no history of diarrhea after giving tube feeding. Patient reported to us one month later with history of accidental removal of

tube. We discussed the issue with patient relatives and advised them to undergo replacement of tube under endoscopic guidance but patient attendants refused for the procedure and were not willing to undergo any further procedure and instead wanted a Ryle's tube to be placed through which the feeding could be done.



**Figure 1: X-ray after completion of PEG, showing contrast in the small bowel. A note of excessively inflated stomach can be made. The greater curvature can be made out easily. The haustra of transverse colon is seen just below the greater curvature of stomach.**

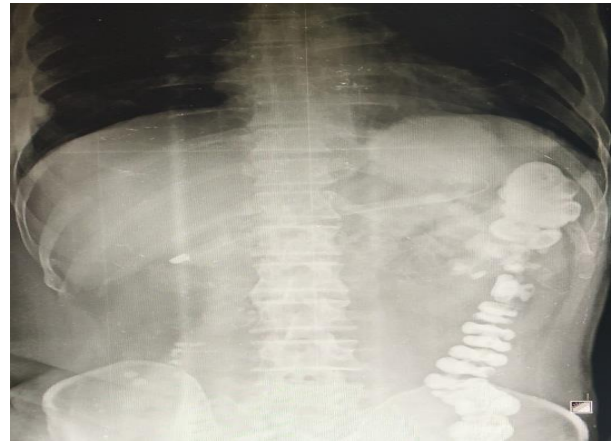
We agreed to it and keeping in mind the chances of leak from gastrostomy site and developing peritonitis, we advised for a gastrograffin study by injecting dye into stomach through the nasogastric tube to look for any possible leak from previous gastrostomy site. To our surprise whole of transverse colon, ascending and descending colon was seen filling with contrast material (Figure 2).



**Figure 2: Gastrograffin study after accidental PEG tube removal. The contrast given through nasogastric tube, showed rapid filling of the large bowel.**

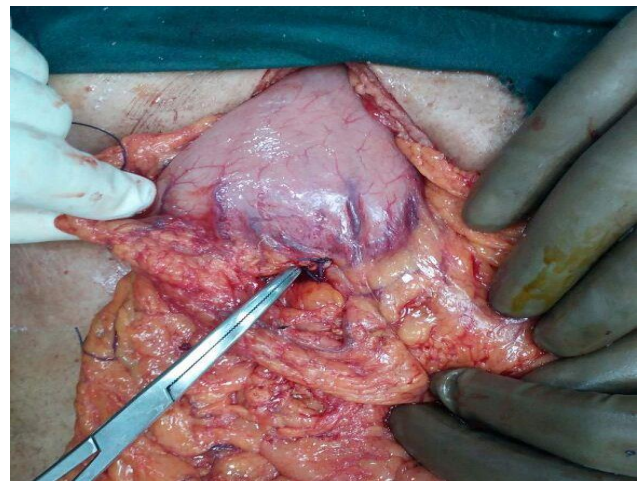
With the above findings we made a diagnosis of gastrocolic fistula and planned for conservative management. Patient was put on parenteral nutrition for

15 days and again gastrograffin study done (Figure 3) to look for closure of fistula.



**Figure 3: Gastrograffin study after 15 days of conservative treatment. The contrast was seen filling the transverse colon and descending colon.**

Radiological film suggested that fistula did not close spontaneously and the contrast material was seen entering into transverse colon and descending colon. We discussed the above complications with patient's attendant. We planned for laparotomy and excision of fistulous tract. Under general anaesthesia laparotomy was done. Fistulous tract i.e. Communication between stomach and colon was identified, excision of fistulous tract with primary closure was done (Figure 4).



**Figure 4: The site of gastrocolic fistula along the greater curvature of stomach.**

Feeding jejunostomy was also done for enteral feeding. Post-operative period was uneventful and patient was started on enteral feed through feeding jejunostomy on 5th post-operative day and discharged home on 7th post-operative day. Since then patient is on regular follow up and doing well. His conscious level and nutrition has also improved.

## DISCUSSION

Gastrocolic or gastrocolocutaneous fistula is a rare complication associated with PEG and has a late presentation with incidence of 0.5 to 3%. This complication occurs due to penetration of interposed colon between the abdominal wall and the stomach during initial insertion of PEG.

High risk factors include previous abdominal surgery, high riding transverse colon, abnormal posture and spinal deformity.<sup>5-8</sup> Anatomical relation of stomach and colon are such that it predisposes patients to complications like gastrocolic or gastrocolocutaneous fistula. Over distention of stomach during PEG procedure leads to anterior rotation of greater curvature of stomach leading to interposition of colon between stomach and abdominal wall. In our case we believe that injury occurred because of excessive inflation of gas during the PEG procedure, which is evident in Figure 1, which shows excessive gaseous dilation of stomach with haustra of transverse colon lying just below the greater curvature of stomach. During the surgery fistula tract was also noted along the greater curvature of stomach (Figure 4). In literature one case with chiladiti syndrome has been reported where during implantation of PEG tube lead to injury to transverse colon which was recognized just after the procedure and treated with laparoscopy surgery.<sup>9</sup>

Gastrocolic or gastrocolocutaneous fistula are formed at the time of insertion of PEG tube, symptoms may not manifest until the PEG tube migrates into transverse colon or until the tube is replaced.<sup>10</sup> An asymptomatic period may persist from few days up to months if tube replacement is not done.<sup>4</sup> In present case also patient was totally asymptomatic for 1 month and tolerating oral feed very well. Even the contrast studies just after the PEG procedure showed that contrast was entering into small bowel, when given through PEG tube (Figure 1). It was only after the accidental removal of PEG tube and contrast studies later on, we arrived at a diagnosis of gastrocolic fistula.

When tube loges into transverse colon patient starts presenting with typical symptoms of diarrhea after PEG feed and passage of undigested feed material.<sup>11</sup> Presence of fecal material in PEG tube or feculent vomiting is other symptoms seen due to retrograde passage of colonic content into stomach via the fistulous tract.<sup>12</sup>

Many studies have suggested several techniques to reduce the risk of colonic penetration during PEG procedure. According to Strodel et al the risk can be reduced by identifying the interposed colon with aspiration of a saline filled syringe to detect air bubbles that appear before endoscopic visualization of needle into the gastric lumen.<sup>13</sup> Excessive inflation of stomach should be avoided as it leads to colonic interposition between stomach and abdominal wall, Croaker and Najmaldin have demonstrated that too much inflation of

stomach before PEG leads to anterior rotation of greater curvature of stomach, carrying the gastrocolic omentum and transverse colon anterior to stomach.<sup>5</sup> The use of ultrasound and computed tomography scan is useful in patients with difficult abdominal anatomy. Technique such as Transillumination and finger pressure help in guiding the placement of tube and choosing the puncture site on abdomen.<sup>14</sup>

Diagnosis of gastrocolic or gastrocolocutaneous fistula can be done with upper gastrointestinal (UGI) endoscopy, radiologic study with a water soluble contrast medium, as seen in our case it was confirmatory or abdominal computed tomography (CT) scan.<sup>11</sup> Colonic haustration and gastrostomy tract can be seen through fluoroscopic images and CT scans.

Several treatment modalities have been suggested which include conservative management by removing the feeding tube and waiting for fistulous tract to heal by itself. Endoscopic treatments are indicated in following cases,

- When fistula does not close spontaneously even after conservative treatment.<sup>15</sup>
- Patients where delayed wound healing and infection is expected.<sup>4</sup>
- Large fistulous opening which definitely needs surgical intervention.

Previously endoscopic interventions were conducted through colonoscopy and clipping of colonic side of fistula tract was done. It is not popular now a day. Open surgery or laparoscopic surgery for fistula excision and primary closure can also be performed in selected patients.<sup>16</sup> In present case we planned to go for open surgery because we were not much experienced in advance laparoscopic surgery and fistula did not seem to be closing even after 15 days of conservative treatment.

## CONCLUSION

PEG is gaining popularity as it is a minimal invasive procedure. The procedure can be performed with minimal sedation and no anesthesia is required. Patient can be sent home same day. Gastrocolic fistula is a rare complication associated with PEG which goes unnoticed initially and recognized as a late complication. All clinicians should be aware of complications associated with PEG and the typical symptoms of gastrocolic fistula so that an early diagnosis and treatment can be provided to the patient to reduce morbidity and mortality. In safe and experienced hands endoscopic treatment or laparoscopic approach is a better alternative as compared to open methods for treatment of gastrocolic fistula.

*Funding: No funding sources*

*Conflict of interest: None declared*

*Ethical approval: The study was approved by the Institutional Ethics Committee*

## REFERENCES

1. Hucl T, Spicak J. Complications of percutaneous endoscopic gastrostomy. *Best Pract Res Clin Gastroenterol*. 2016;30:769-81.
2. Pitsinis V, Roberts P. Gastrocolic fistula as a complication of percutaneous endoscopic gastrostomy. *Eur J Clin Nutr*. 2003;57:876-8.
3. Smyth GP, McGreal GT, McDermott EW. Delayed presentation of a gastricocolocutaneous fistula after percutaneous endoscopic gastrostomy. *Nutrition*. 2003;19:905-6.
4. Kim HS, Bang CS, Kim YS, Kwon OK, Park MS, Eom JH et al. Two cases of gastrocolocutaneous fistula with a long asymptomatic period after percutaneous endoscopic gastrostomy. *Intestinal Res*. 2014;12:251-5.
5. Croaker GDH, Najmaldin AS. Laparoscopically assisted percutaneous endoscopic gastrostomy. *Pediatr Surg Int*. 1997;12:130-1.
6. Friedmann R, Feldman H, Sonnenblick M. Misplacement of percutaneously inserted gastrostomy tube into the colon: report of 6 cases and review of the literature. *JPEN J Parenter Enteral Nutr*. 2007;31:469-76.
7. Tominaga K, Saigusa Y, Ito S, Hirahata K, Nemoto Y, Maetani I. Percutaneous endoscopic gastrostomy with the aid of a colonoscope to avoid gastrocolic fistula formation. *Endoscopy*. 2007;39(Suppl 1):E112-E113.
8. Lee HJ, Choung RS, Park MS, Pyo JH, Kim SY, Hyun JJ et al. Two cases of uncommon complication during percutaneous endoscopic gastrostomy tube replacement and treatment. *Korean J Gastroenterol*. 2014;63:120-4.
9. Gunji S, Katayama H, Morikawa S. Successful treatment of an iatrogenic gastro-colo-cutaneous fistula in a patient with Chilaiditi syndrome: A case report. *Cogent Medicine*. 2017 Jan 1;4(1):1331600.
10. Yamazaki T, Sakai Y, Hatakeyama K, Hoshiyama Y. Colocutaneous fistula after percutaneous endoscopic gastrostomy in a remnant stomach. *Surg Endosc*. 1999;13:280-2.
11. Stefan MM, Holcomb GW, Ross AJ. Cologastric fistula as a complication of percutaneous endoscopic gastrostomy. *JPEN J Parenter Enteral Nutr*. 1989;13:554-6.
12. Minocha A, Rupp TH, Jaggars TL, Rahal PS. Silent colo-gastrocutaneous fistula as a complication of percutaneous endoscopic gastrostomy. *Am J Gastroenterol*. 1994;89:2243-4.
13. Strodel WE, Lemmer J, Eckhauser F, Botham M, Dent T. Early experience with endoscopic percutaneous gastrostomy. *Arch Surg*. 1983;118:449-53.
14. Schrag SP, Sharma R, Jaik NP, Seamon MJ, Lukaszczyk JJ, Martin ND et al. Complications related to percutaneous endoscopic gastrostomy (PEG) tubes. A comprehensive clinical review. *J Gastrointest Liver Dis*. 2007 Dec 1;16(4):407-18.
15. Hwang JH, Kim HW, Kang DH, Choi CW, Park SB, Park TI et al. A case of endoscopic treatment for gastrocolocutaneous fistula as a complication of percutaneous endoscopic gastrostomy. *Clin Endosc*. 2012;45:95-8.
16. Nicholson FB, Korman MG, Richardson MA. Percutaneous endoscopic gastrostomy: a review of indications, complications and outcome. *J Gastroenterol Hepatol*. 2000;15:21-5.

**Cite this article as:** Kishore A. Gastrocolic fistula as a complication of percutaneous endoscopic gastrostomy (PEG): a case report and review of literature. *Int Surg J* 2018;5:2653-6.