

## Original Research Article

# Approach to hernial defect in laparoscopic incisional hernia repair

Nijas N. A., Sanjay N. Koppad\*

Department of General Surgery, Yenepoya Medical College, Manglore, Karnataka, India

**Received:** 19 March 2018

**Accepted:** 24 March 2018

**\*Correspondence:**

Dr. Sanjay N. Koppad,

E-mail: [sanjaykoppad@gmail.com](mailto:sanjaykoppad@gmail.com)

**Copyright:** © the author(s), publisher and licensee Medip Academy. This is an open-access article distributed under the terms of the Creative Commons Attribution Non-Commercial License, which permits unrestricted non-commercial use, distribution, and reproduction in any medium, provided the original work is properly cited.

### ABSTRACT

**Background:** Ventral hernias are the second most common type of abdominal hernias and account for approximately 10% of all hernias. Recurrence rates after open suture repair have been reported to be as high as 31% to 49%. Laparoscopic ventral hernia repair (LVHR) has been reported to have reduced recurrence rates as compared to open mesh repair, reduced infection rate, shorter recovery time and hospital stay. During LVHR, closure of the hernial defect is a contentious issue. Author describe our observations with the closure of hernial defect in LVHR in comparison to non-closure of defects in relation to seroma, pain, ileus, and recurrence.

**Methods:** An observational study of closure versus non-closure of hernial defect in laparoscopic ventral hernia mesh repair was conducted in 81 patients from March 2016 to March 2017. Ventral hernia repair with mesh was done without closure of defect in 32 cases as compared to 49 cases in which closure of defect was done.

**Results:** Seroma, pain, ileus and recurrence incidence are less in closure of defect in comparison to non-closure of defect in present study.

**Conclusions:** With increasing experience, different theories and techniques have been described by different surgeons to overcome the intra operative and postoperative problems. During LVHR, closure of the hernial defect is a contentious issue. Closure of defect in the experience decreases rate of seroma formation. Closure of defect induce more post-operative pain but may be superior with regard to other important surgical outcomes. Duration of follow up is inadequate to conclude about incidence of recurrence in present study.

**Keywords:** LVHR, Post-operative pain, Recurrence, Seroma

### INTRODUCTION

Indications to repair a ventral hernia are symptom relief, cosmesis, and prevention of future problems related to the hernia such as pain, acute incarceration, enlargement, and skin problems.<sup>1</sup> For all hernia repairs it is important to define and align patient and surgeon goals for the operation preoperatively. Diagnosis of a ventral hernia is typically made during the history and physical examination.

Imaging studies including ultrasound, computed tomography (CT) with and/or without Valsalva, and magnetic resonance imaging (MRI) can also be used for

diagnosis. Imaging studies may be helpful to assess the anatomic details of a ventral hernia, augmenting the physical examination, especially when a hernia cannot be reduced, and therefore the defect cannot be palpated and measured. These situations commonly arise with small defects, obese patients, or incarceration (either acute or chronic). CT has been found to be useful in diagnosing occult hernias, multiple defects, abscess, and hematoma, as well as in differentiating incarcerated hernias from abdominal wall neoplasms.<sup>2</sup>

### METHODS

An observational study of closure versus non-closure of hernial defect in laparoscopic ventral hernia mesh repair

study was conducted in 81 patients from March 2016 to March 2017 in our college.

**Inclusion criteria**

- Age >18yrs
- Size of defect 2 to 6 cm

**Exclusion criteria**

- All irreducible hernias
- Size of defect >6cm
- Patients not fit for general anaesthesia
- Recurrent ventral hernia after laparoscopic repair

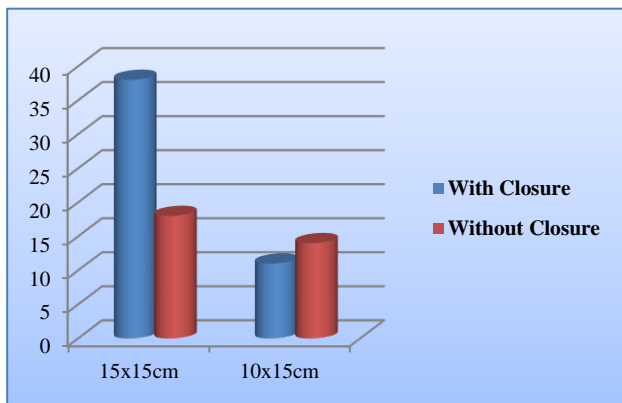
Thorough history and clinical examination of the patients was done with ventral hernia. All patients were asked for ultrasound of abdomen to know the site and size, number of defects, and content of ventral hernia. All were also thoroughly investigated and pre-operative medical and anaesthetist fitness was taken keeping in mind all patients required general anaesthesia for surgery.

Standard operative protocols as suggested by SAGES guidelines for laparoscopic ventral hernia were followed in all patients. All cases were operated under general anaesthesia and antibiotic prophylaxis was given. Pneumoperitoneum was created by closed method-Veress needle at Palmar’s point in all cases.

In all cases 10mm 300 telescope was used. Two port technique was used in 66 patients and in remaining 15 patients three port technique was utilized. Telescope was inserted through the 10mm trocar at the palmar’s point. Diagnostic laparoscopy was done and the ventral hernial site, content and size noted.

**RESULTS**

In the present study male patients were 26 and 55 were female patients. Median age of patients in present study was 42 years. Different types of ventral hernias in this study were umbilical-29, paraumbilical-25, incisional-18, epigastric-9.

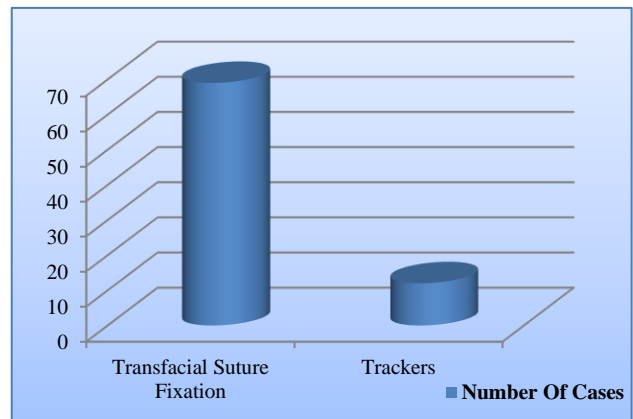


**Figure 1: Size of the dual mesh used.**

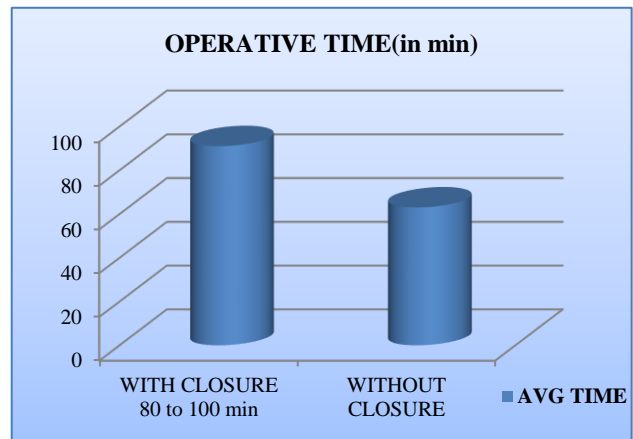
In this study 49 patients had hernia defect size 2-6cm and remaining 32 patients had defect >6cm. Omentum in 65 patients and bowel in 16 patients was seen as hernia content.

All adhesions were released by combination of blunt, sharp dissection and bipolar coagulation. In all case dual sided mesh was used of size 15 x 15cm - 56 cases and 10 x 15 cm - 25 cases (Figure 1).

Mesh was fixed by Transfascial sutures in 69 cases and with tackers in 16 cases (Figure 2). Operative time for hernia repair with closure of defect was 80 to 100 min and without closure of defect was 50 to 70 min (Figure 3).



**Figure 2: Mesh fixation.**



**Figure 3: Diagram depicting operative duration.**

All cases were discharged on 3-4 post-operative day except for 1 patient with ileus who was discharged at 5<sup>th</sup> day.

Patients in both the group were followed for 1 year. Seroma, pain, ileus and recurrence incidence are less in closure of defect in comparison to non-closure of defect in present study (Table 1).

**Table 1: Complications in defect closure.**

Complications	Non-closure (32 cases)	Closure (49 cases)
Seroma	6	1
Pain	1	5
Ileus	1	0
Recurrence	1	0

## DISCUSSION

The principles of safe abdominal access for laparoscopic surgery apply to LVHR, and technical details about establishment of pneumoperitoneum can be found in the SAGES Fundamentals of Laparoscopic Surgery (FLS) program. There have been no comparative data regarding techniques for establishing pneumoperitoneum specifically for LVHR, although a variety of techniques have been described in the published literature, all with low rates of complications and successful establishment of pneumoperitoneum.

Current options most commonly used for initial peritoneal access for LVHR include direct trocar insertion with an optical trocar (with or without a pneumoperitoneum with the use of the Veress needle), or an open Hasson technique.

Multiple meta-analyses and randomized controlled trials with a variety of general surgical and gynecological laparoscopic procedures reveal no difference in major complication rates with direct trocar insertion without pneumoperitoneum compared to establishment of pneumoperitoneum with Veress needle prior to initial trocar insertion. Regardless of the technique, the surgeon should have adequate training and/or experience with it in similar clinical situations. Additionally, since many LVHRs are performed for midline hernias, it is recommended to access the abdomen off the midline, to avoid areas with potential adhesions of bowel. Regarding placement location, it is desirable to have the working ports as far lateral as possible to expose midline hernias and to be able place a large piece of mesh without interference. The operation is usually accomplished using 3-5 ports.

A larger port (10-12mm) is typically utilized for the insertion of the prosthetic mesh. This port is sometimes the initial port placed with an open technique and placed just lateral to the rectus muscle for primary midline hernias, used mostly for mesh placement, and is eventually covered by the mesh used for the repair. There are usually 3 ports placed on one side of the abdominal wall and 1-2 ports placed on the other. Many authors report their entry techniques; however, none directly compare the techniques. One of the largest retrospective series described placement of a Veress needle at least 10 cm away from the prior scar, preferentially 2cm below the left costal margin in the midclavicular line (Palmer's

point). The left upper quadrant (LUQ) is the most commonly reported initial entry site with all techniques.<sup>3</sup>

It is important to consider the size of the hernia defect when contemplating a laparoscopic approach, as larger defects generally increase the difficulty of the procedure.<sup>4</sup> A recently published guideline by an Italian Consensus Conference recommended caution for defects greater than 10cm but did not consider such defects as absolute contraindication. On the other hand, the same group recommended that hernias with a defect size <3cm should not be approached laparoscopically. This recommendation was based on expert opinion and a survey showing that less than 10% of surgeons used prosthetics in defects less than 3cm; it was, therefore, deemed "an indirect indication of a minimum size limit for laparoscopy. The present MEDLINE search of the literature did not reveal any evidence in support of this recommendation. Therefore, additional evidence is needed before a minimum size for laparoscopic repair can be defined. Reported conversion rates in the literature range between 1-14% in series with over 50 patients. Possible reasons for a higher conversion rate may include poor patient selection, severe adhesions, incarcerated hernia content impossible to reduce and/or inadequate training and expertise on the part of the surgeon.<sup>5</sup>

Given the variation of technical ability and institutional capability, along with the gradual acquisition of experience, surgeons must use their judgement when determining whether to perform a laparoscopic or open VHR. When considering a laparoscopic approach and selecting patients, the surgeon should consider his or her own experience. There is limited evidence to indicate how expertise with laparoscopic VHR is developed; however, it appears prudent to recommend that less experienced surgeons should start with less complex cases. A study analyzing 180 cases of a prospectively collected database found a number of clinical factors that significantly increased operative time (which was used as a surrogate for laparoscopic repair complexity) such as adhesiolysis and prior ventral hernia repair(s). Other factors reported in the literature that increase the complexity of LVHR include large defects (>10cm diameter), hernias in unusual locations (subxiphoid, suprapubic, flank, etc.), incarcerated hernia, hernias with small defect size but large hernia sac, obesity, bowel distention, pregnancy, and presence of ascites.<sup>6</sup>

The forementioned factors, which are known to increase the technical difficulty of the operation, should help guide the surgeon in selecting the appropriate patients for LVHR.

The decision of whether or not to perform a LVHR should weigh the surgeon's training and experience, as well as the institution's capability to provide the proper equipment and supplies. As training and experience is gained, gradually more complex laparoscopic VHRs may be appropriately undertaken.

Traditionally ventral hernias were repaired by opened technique with or without the use of mesh. Later with the advent of laparoscopy focus was shifted to laparoscopic closure of defect initially later to use of mesh and recently to incorporate both the techniques i.e. closure of the defect with mesh reinforcement. Laparoscopic ventral hernia repair, compared to open repair, has a lower rate of wound infections.

Recurrence rates and postoperative pain are similar between the two techniques, during mid-term follow-up. The advantages offered by LVHR over open hernia repair in terms of decreased wound complication rates should be taken into consideration by surgeons and disclosed to patients during consultation and discussion of surgical options.

Reasons to close the defect during LVHR prior to mesh insertion include the possibility of reduced seroma rate, reduced recurrence rate, improved “abdominal wall function,” and improved abdominal wall contour postoperatively.<sup>7</sup> Persistent pain following laparoscopic ventral hernia repair should be treated with analgesics, anti-inflammatory medications, steroids, trigger point injection or nerve block.<sup>8</sup>

Seroma formation following laparoscopic hernia repair should be considered an expected outcome, rather than a complication. Seromas that are persistent for prolonged periods of time or those that are symptomatic may require treatment.<sup>9</sup>

Techniques for prevention of seromas may be employed to minimize the likelihood of developing this persistent problem but results of these techniques are mixed. There are few studies showing that cauterization of the hernia sac may decrease seroma formation. The use of abdominal pressure dressings and abdominal binders may improve pain but may not reduce seroma occurrence. Laparoscopic defect closure at the time of laparoscopic ventral hernia repair have been suggested to help restore the contour of the abdominal wall, reduce abdominal bulging as well as reduce seroma formation.

Reports of this technique have demonstrated a mixed benefit upon seroma formation with a low or absent incidence of clinically significant seromas, however abdominal wall contouring may be a benefit.<sup>10</sup>

Patients developing a postoperative ileus should be initially treated non-operatively with fluid administration, bowel rest, and/or gastric decompression. There is no uniformly accepted definition of prolonged ileus following laparoscopic ventral hernia repair, but “ileus” or “prolonged ileus” is reported to be between 0% and 20%, with the average incidence 4.0%.

The cause of postoperative ileus after LVHR has been speculated to be due to suture site pain, adhesiolysis, duration of procedure, or bowel manipulation.<sup>11</sup>

## CONCLUSION

This was an observational study which was conducted in our college with minimal resources. Lot of effort was put to ask patients for the follow up. From this study it is clearly evident that closure of defect in laparoscopic ventral hernia has more advantages than non-closure of the defect. Based on the above results we conclude that during LVHR with closure of defect in our experience decreases rate of seroma formation, induce more post-operative pain but may be superior with regard to other important surgical outcomes. Duration of follow up is inadequate to conclude about incidence of recurrence in present study.

*Funding: No funding sources*

*Conflict of interest: None declared*

*Ethical approval: The study was approved by the Institutional Ethics Committee*

## REFERENCES

1. Sauerland S, Walgenbach M, Habermalz B, Seiler C M, Miserez M. Laparoscopic versus open surgical techniques for ventral or incisional hernia repair. *Cochrane Database Syst Rev.* 2011;Cd007781.
2. Ianora AA, Midiri M, Vinci R, Rotondo A, Angelelli G Abdominal wall hernias: imaging with spiral CT. *Eur Radiol.* 2000;10:914-9.
3. Society of American Gastrointestinal and Endoscopic Surgeon (SAGES) Fundamentals of laparoscopic surgery 2015. Available at <http://www.flsprogram.org>. Accessed on April 23<sup>rd</sup>, 2015.
4. Jenkins ED, Yom VH, Melman L, Pierce RA, Schuessler RB, Frisella MM, et al. Clinical predictors of operative complexity in laparoscopic ventral hernia repair: a prospective study. *Surg Endosc.* 2010;24:1872-7.
5. Heniford BT, Park A, Ramshaw BJ, Voeller G. Laparoscopic repair of ventral hernias: nine years' experience with 850 consecutive hernias. *Ann Surg.* 2003;238:391-9.
6. Varnell B, Bachman S, Quick J, Vitamvas M, Ramshaw B, Oleynikov D. Morbidity associated with laparoscopic repair of suprapubic hernias. *Am J Surg.* 2003;196:983-7.
7. Palanivelu C, Jani KV, Senthilnathan P, Parthasarathi R, Madhankumar MV, Malladi VK. Laparoscopic sutured closure with mesh reinforcement of incisional hernias. 2007;11:223-8.
8. Sauerland S, Walgenbach M, Habermalz B, Seiler C M, Miserez M. Laparoscopic versus open surgical techniques for ventral or incisional hernia repair. *Cochrane Database Syst Rev.* 2011;Cd007781.
9. Zhang Y, Zhou H, Chai Y, Cao C, Jin K, Hu Z. Laparoscopic versus open incisional and ventral hernia repair: a systematic review and meta-analysis. *World J Surg.* 2014;38:2233-40.

10. Liang MK, Subramanian A, Awad SS, Laparoscopic transcutaneous closure of central defects in laparoscopic incisional hernia repair. *Surg Laparosc Endosc Percutan Tech.* 2012;22:e66-70.
11. LeBlanc KA, Whitaker JM, Bellanger DE, Rhynes VK. Laparoscopic incisional and ventral

hernioplasty: lessons learned from 200 patients. *Hernia.* 2003;7:118-24.

**Cite this article as:** Nijas NA, Koppad SN. Approach to hernial defect in laparoscopic incisional hernia repair. *Int Surg J* 2018;5:1738-42.