

## Case Report

# A stress ulcer duodenal perforation complicating diaphragmatic rupture with multiple bone fracture in a polytrauma patient due to fall from a tree

Sudhir Kumar Panigrahi\*, Amaresh Mishra, Pradipta Kishore Khuntia, Abinash Kanungo

Department of Surgery, Kalinga Institute of Medical Sciences, KIIT, Bhubaneswar, Odisha, India

**Received:** 07 March 2018

**Accepted:** 05 April 2018

### \*Correspondence:

Dr. Sudhir Kumar Panigrahi,  
E-mail: [drsudhir147@gmail.com](mailto:drsudhir147@gmail.com)

**Copyright:** © the author(s), publisher and licensee Medip Academy. This is an open-access article distributed under the terms of the Creative Commons Attribution Non-Commercial License, which permits unrestricted non-commercial use, distribution, and reproduction in any medium, provided the original work is properly cited.

## ABSTRACT

Polytrauma in a 55 years male due to blunt trauma like fall from a height involving fracture of long bones, undisplaced fracture pelvis, fracture multiple ribs with a preliminary diagnosis of eventration of the hemidiaphragm in a apparently hemodynamically stable patient with a normal CT scan of brain, though poses a major physiological challenge, however runs a better prognosis. But with the passing of hours as patient develops respiratory distress and chest and abdomen CECT confirms a large lacerated hemidiaphragm with herniation of abdominal viscera occupying the hemithorax with lung collapse, alarms the gravity of the injury. An uncommon stress ulcer duodenal perforation on the 2nd day of admission with ensuing pyoperitoneum further threatens the hemodynamics and enhances the morbidity and mortality. This warrants an active and prompt action by multispecialty involvement. Emergency laparotomy to address the pyoperitoneum, closure of the duodenal perforation, reduction of the herniated abdominal viscera from the hemithorax, thorough saline lavage of the abdominal and involved chest cavity, placement of intrathoracic chest tube drain, repair of the lacerated diaphragm, placement of peritoneal cavity drains and closure of the abdomen settles the issue of damage control surgery in this case. Postoperative care in the ICU with ventilator support, higher antibiotics and supportive medications, repeated laboratory and radiological tests helps in overcoming the hemodynamic crisis in such critically ill patients. Our patient subsequently developed pneumonitis and had a postoperative protracted course in the ICU and finally shifted to the general ward on 7th day of his admission.

**Keywords:** Diaphragmatic rupture, ICU care and prolonged morbidity, Multiple bone fracture, Polytrauma due to fall, Stress induced duodenal perforation

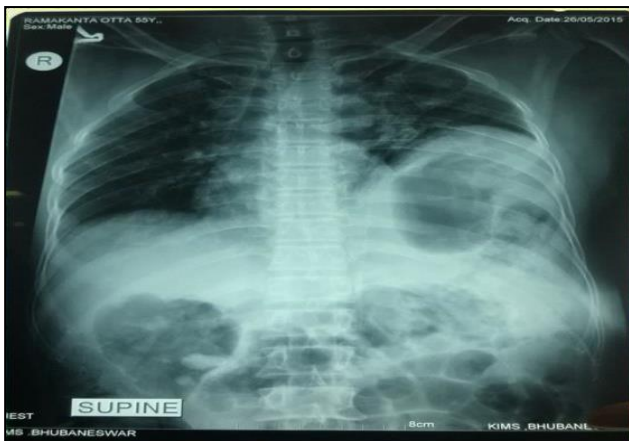## INTRODUCTION

Traumatic Diaphragmatic Injury (DI) may occur due to blunt trauma requiring laparotomy in 3%-8% patients and in 10% of patients with penetrating trauma to the abdomen.<sup>1</sup> Majority occur in men and involve Lt. hemidiaphragm in up to 70 to 90% of cases.<sup>2</sup> The cause of DI in approximately 75% by blunt trauma and 25% by penetrating trauma.<sup>3</sup> Left sided DI occur in 70-80% cases, right sided DI in 15-24% cases and both sided DI in 5-8% cases.<sup>4</sup> Incidence of Rt. sided DI is low due to

the cushioning effect of the liver (usually associated w/ significant vascular tears in IVC or hepatic vein w/ higher pre-hospital mortality). Eventration of the diaphragm is a rare condition occurring 1 in 1400 cases, due to a congenital abnormality of the pleuroperitoneal membrane or an acquired progressive muscular atrophy due to phrenic nerve palsy or trauma and involving permanent elevation without any breach in its surface continuity or attachment to the costal margins, 1st described in 1774 by Jean Louis Petit.<sup>5</sup>

## CASE REPORT

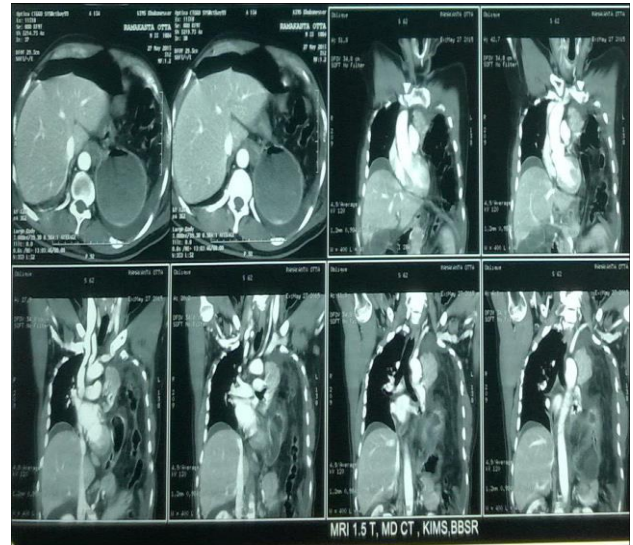
A 55 years gentleman was brought to the casualty within 4 hours following fall from a tree branch at a height of about 10 feet with inability to move the left hand, left lower limb and pain at these sites as well as the left anterior lower chest and adjacent upper abdomen. The patient had a bout of vomiting and became drowsy for about 5 minutes following the fall. At admission, his vitals, O<sub>2</sub> saturation was within normal limits. Initial X-ray chest, abdomen and limbs revealed fracture of both bones of distal forearm, 7th and 8th ribs, undisplaced fracture of the pubis and neck of the femur all on the left side, and eventration of the left hemidiaphragm. CT scan of brain was normal. The patient was therefore managed conservatively in the surgical ward under close observation with IV fluids, Inj. Pantoprazole, analgesics and antibiotics. As all the fractures were closed wounds and without much displacement or local exsanguinations, they were managed by posterior slab and immobilization with the plan of definitive treatment after initial physiologic stabilization of the patient. On the 2nd day night, the patient complained of sudden epigastric pain with dyspnea with O<sub>2</sub> saturation of 84% with a normal ECG. Immediate X-ray chest and abdomen showed gas under right dome of diaphragm with a high left hemidiaphragm. Next morning as the pain became increasingly diffuse, and patient became restless without O<sub>2</sub> support, an urgent repeat X-Ray chest suggested collapsed left lung with increased radiodensity of left hemithorax involving both mid and lower zones (Figure 1).



**Figure 1: CXR showing high placed left diaphragm and bowel gas shadow in the left hemithorax.**

A raised leukocyte count of 23,000/cu mm, 84% neutrophils and pyrexia of 101.0 F with rigidity of the abdomen. Immediate MDCT thorax and abdomen showed left hemi diaphragmatic rupture with herniation of stomach, colon, and greater omentum into the thoracic cavity and free peritoneal fluid (Figure 2). The attendants of the patient were thoroughly explained about the critical condition and plan of management including emergency

exploratory laparotomy and the risk involved and prognosis.



**Figure 2: MDCT of thorax and abdomen showing left hemithorax occupied by abdominal viscera.**

Exploratory laparotomy done through midline incision revealed pyoperitoneum, anterior duodenal perforation, herniation of whole of the stomach, transverse colon and greater momentum, occupying about whole of the left thoracic cavity and contusion of the left perinephric region. Peritoneal lavage with warm saline done and reduction of all the viscera from left chest cavity revealed a lacerated left hemidiaphragm of about 15 cm on its posterolateral aspect. Graham's omental patch closure of the duodenal perforation, repeat thorough saline lavage of both contaminated pleural and peritoneal cavities, left intercostal chest tube drain placed, diaphragm tear repaired by interrupted 1 prolene suture, 2 tube drains placed in the right subhepatic and pelvis and abdomen closed by mass closure with 1 loop ethilon. Patient shifted to ICU in the postoperative period, X-ray chest taken 6 hours after suggested a near total expansion of the left lung. Patient showed all signs of improvement and was extubated on 3rd POD and allowed orally on 4th POD. On 5th POD he developed pneumonitis of mid and lower zones of left lung as suggested by fever, leucocytosis of 18,000/cu mm and X-ray chest. Antibiotics were changed, and I.V. fluconazole was added based on blood and chest tube drain tip culture and sensitivity report. On 7th POD patient was shifted to the surgery ward and then transferred to the orthopedic ward on 14th day for the definitive management of long bone and pelvic fracture.

## DISCUSSION

DI due to blunt trauma include RTA or falls from a height and penetrating DI involve stabbing or gunshot injury.<sup>3</sup> Mechanism of rupture of the diaphragm include a sudden increase in the intra-abdominal or intra thoracic

pressure against a fixed diaphragm or avulsion from its site of attachment or stretched diaphragm sustaining a shearing force.<sup>6</sup> Rarely the cause for DI can be a violent act of vomiting or coughing, exercise, pregnancy or an iatrogenic injury. Mechanism of DI involve a direct anterior blow to the abdomen with a sudden transmission of force through the abdominal viscera that acts as a hydrodynamic fluid wave leading to significantly increase intra-abdominal pressure and disruption. Penetrating injuries include gunshot and stab wounds of the diaphragm and potentially more dangerous as they create smaller defects with high probabilities of later obstruction and strangulation. Iatrogenic injuries occur during thoracotomy or laparotomy and are usually insidious and difficult to identify. According to Grimes, based on the duration of injury, DI are categorized into 3 phases as<sup>7</sup>:

- Acute, i.e. immediately or within 14 days post-injury;
- Latent, diagnosed after 14 days but before intestinal obstruction or strangulation;
- Late, where diagnosis is established with intestinal obstruction or strangulation.

Causes of missed DI include delayed rupture or delayed detection. In delayed rupture, the diaphragmatic muscle is devitalized at the time of the initial injury and starts acting as a barrier against herniation. Delayed detection is due to later herniation. Therefore, during exploratory laparotomy in all cases of abdominal trauma, a meticulous inspection and palpation of the entire diaphragm becomes mandatory. The diaphragm is rarely injured alone. Triad of severe blunt thoraco-abdominal trauma consists of pelvic fractures, blunt diaphragmatic rupture and blunt thoracic aortic rupture. Associated Injuries with DI are blunt thoracic injuries such as haemo-pneumo-thorax and multiple rib fractures in 90%, pelvic fractures in 40%, both hepatic and splenic injuries in 25% and blunt rupture of the thoracic aorta in 5% pts.

Different modalities for the diagnosis of DI are X-ray chest, Ultrasonography, CT and MRI. Traumatic DI are detected in only 50-70 % of cases initially by chest X-ray , 25-50% detected in early X-ray and another 25% in the subsequent X-ray.<sup>8</sup> The CXR findings include the distortion of both diaphragmatic margin, elevated hemidiaphragm by >4 cm as compared to normal side and evidence of bowel loops in the thoracic cavity.<sup>8</sup> Currently multidetector CT (MDCT) is the investigation of choice in the detection of DI with sensitivity and specificity rate of 61-87% and 72-100% respectively.<sup>9</sup> The CT picture includes the "Collar Sign" suggestive of focal constriction of abdominal viscera , discontinuity of the diaphragm and herniation of abdominal viscera into the thoracic cavity.<sup>8</sup>

Repair of DI by laparotomy through abdominal or thoracic or thoraco-abdominal route and is considered the gold standard. Control of hemorrhage and shock,

should be closely followed-up. At laparotomy, careful inspection of the diaphragm and its laceration is repaired with interrupted non-absorbable sutures. In cases of diaphragmatic disruption due to massive trauma, prosthetic non-absorbable mesh is used for reconstruction. Initial small and undetected DI can progress to increase visceral herniation, obstruction and even strangulation. Immediate repair of DI is simple and heals early. Delayed repair becomes difficult due to adhesions, atrophy of the diaphragm and runs a risk of dehiscence (prosthetic meshes are preferred in such cases). Extensive literature review on route of DI repair reveals, via laparotomy in 74%, thoracotomy in 18% and a thoracoabdominal approach in 8% cases. Complications following DI repair are serious when associated with perforation of abdominal viscera with resultant pneumonia, empyema, sub-phrenic or intra-abdominal abscess, suture-line dehiscence, hemi diaphragmatic paralysis (secondary to phrenic nerve injury), respiratory insufficiency, pulmonary embolism (rare due to use of prophylaxis). Mortality in DI due to blunt and penetrating injury is 37% and 4.3 % respectively and attributable to irreversible shock and head injury for intra-op. and early post-operative deaths and sepsis and multisystem organ failure for later deaths. The stress induced duodenal perforation on 2<sup>nd</sup> day of admission with pyoperitoneum and subsequent pus spread to left chest cavity through the torn left hemidiaphragm forming a pyothorax in our case adds to the severity of the injury and the resultant morbidity despite prophylactic proton pump inhibitors. Acute gastric and duodenal erosions occur as a stress response of the gastrointestinal tract to major physiological stressors and can result in upper GI perforation.<sup>10</sup> This entity of stress related mucosal disease (SRMD) in critically ill patients of major trauma or polytrauma, burn, major surgery, shock, sepsis and multiple organ failure, was first described in 1971 by Lucas et al. Pathophysiology of these ulcers, though poorly understood, is thought to be multifactorial involving inadequate systemic perfusion with resultant poor mucosal blood flow, a decreased gastric pH, enhanced mucosal permeability and an altered mucosal protective mechanism.<sup>11,12</sup> These develop within hours of major illness or polytrauma, usually superficial causing capillary oozing. The deeper ulcers can lead to serious complications like profuse bleeding or rarely perforation that adds to the mortality.<sup>13</sup> Stress ulcer prophylaxis in all such patients include the use of proton pump inhibitors (PPIs), histamine-2 receptor antagonists (H2 RAs) and less frequently, sucralfate and antacids.<sup>14</sup>

To conclude, traumatic injuries of the diaphragm are often clinically occult, can be masked and disguised by other violent injuries associated with polytrauma. Best approach is the high index of suspicion in such cases. CXR followed by spiral CT (preferably with multidetector rows) are the main tools in evaluating the diaphragm. Surgery i.e., laparotomy is the gold standard for treatment of DI as it allows evaluation of other associated violent injuries. However, Laparoscopy and

thoracoscopy (especially VATS) can be utilized in both diagnosis and definitive management in thoracic trauma with diaphragmatic injuries. Stress ulcer prophylaxis in all critically ill patients helps in the prevention or reduction in the development of complications like GI bleeding and perforation which enhances the morbidity and mortality.

*Funding: No funding sources*

*Conflict of interest: None declared*

*Ethical approval: The study was approved by the Institutional Ethics Committee*

## REFERENCES

1. Nchimi A, Szapiro D, Ghaye B, et al. Helical CT of blunt diaphragmatic rupture. *AJR Am J Roentgenol*. 2005;184(1):24-30.
2. Dietrich P, Alsofrom G: The diaphragm. In *Radiology: diagnosis, imaging, intervention*. Volume 1. 1<sup>st</sup> Ed; Philadelphia: Lippincott;1990:1-10.
3. Shah R, Sabanathan S, Mearns AJ, Choudhury AK, Traumatic rupture of diaphragm, *Ann Thora Surg*. 1995;60(5):1444-9.
4. Eren S, Kantarcı M, Okur A. Imaging of diaphragmatic rupture after trauma. *Clin Radiol*. 2006;61(6):67-77.
5. McNamara JJ, Paulson DL, Urschel HC, Razzuk MA: Eventration of the diaphragm. *Surg*. 1968, 64(6):1013-21.
6. J. L. Cameron, "Diaphragmatic injury," in *Current Surgical Therapy*, 7<sup>th</sup> Ed, Louis, Mo, 2001.1095-100
7. O. F. Grimes, "Traumatic injuries of the diaphragm. Diaphragmatic hernia, *Am J Surg*.1974;128 (2):175-81.
8. Walchalk LR, Stanfield SC. Delayed presentation of traumatic diaphragmatic rupture. *J Emerg Medi*. 2010;39(1):21-4.
9. Larici AR, Gotway MB, Litt HI, Reddy GP, Webb WR, Gotway CA., et al. Helical CT with sagittal and coronal reconstructions: accuracy for detection of diaphragmatic injury. *AJR Am J Roentgenol* 2002;179(2):451-7.
10. Selye H. The general adaptation syndrome and the diseases of adaptation. *J Clin Endocrinol Metab* 1946;6(2):117-230.
11. Lucas CE, Sugawa C, Riddle J, Rector F, Rosenberg B, Walt AJ. Natural history and surgical dilemma of "stress" gastric bleeding. *Arch Surg* 1971;102(4):266-73.
12. Cook D, Heyland D, Griffith L, Cook R, Marshall J, Pagliarello J. Risk factors for clinically important upper gastrointestinal bleeding in patients requiring mechanical ventilation. *Crit Care Med*. 1999;27(12):2821-7.
13. Cook DJ. Stress ulcer prophylaxis: gastrointestinal bleeding and nosocomial pneumonia. Best evidence synthesis. *Scand J Gastroenterol Suppl*. 1995;30(210):48-52.
14. Kristian Rorbaek Madsen, Kristian Lorentzen, Niels Clausen, Emilie Oberg, Peter Roy Casparij Kirkegaard, Nana Maymann-Holler and Morten Hylander Moller. Guideline for Stress Ulcer Prophylaxis in the Intensive Care Unit. *Dan Med J* 2014;61(3):C4811.

**Cite this article as:** Panigrahi SK, Mishra A, Khuntia PK, Kanungo A. A stress ulcer duodenal perforation complicating diaphragmatic rupture with multiple bone fracture in a polytrauma patient due to fall from a tree. *Int Surg J* 2018;5:1952-5.