

Case Report

Posterior urethral valve presenting with urethral stone: a challenging diagnosis

Avreen Singh Shah*, Gurpreet Singh Bhangu, Rupinderjit Singh Sandhu, Kulwant Singh Ded,
Sukhmanjeet Kaur Mann

Department of Surgery, SGRDIMSR, Vallah, Amritsar, Punjab, India

Received: 09 August 2016

Accepted: 13 August 2016

***Correspondence:**

Dr. Avreen Singh Shah,

E-mail: Avreen@msn.com

Copyright: © the author(s), publisher and licensee Medip Academy. This is an open-access article distributed under the terms of the Creative Commons Attribution Non-Commercial License, which permits unrestricted non-commercial use, distribution, and reproduction in any medium, provided the original work is properly cited.

ABSTRACT

Posterior urethral valve is one of the most common causes of urethral obstruction in male neonates. Posterior urethral valve is now a day commonly diagnosed in prenatal USG. PUV can cause symptoms ranging from pulmonary hypoplasia to renal insufficiency. We are presenting a case report of a rare association of a large urethral calculus secondary to Posterior urethral valve in a 4 years old child who presented with difficulty while micturition. PUV is common finding in male children, which mainly presents with difficult micturition. This case was a rare association of urethral calculi secondary to valves presenting with painful micturition.

Keywords: PUV, Urethral stone, Valves

INTRODUCTION

Posterior urethral valve is one of the most common congenital obstructions of urethra presenting in males in neonatal period as life threatening conditions or in older children with minor voiding symptoms. The incidence of Posterior urethral valves ranges from 1 in 8000 to 1 in 25000.¹ The association of a urethral calculi and a Posterior urethral valve is uncommon with only few cases reported in literature.

A 4-year-old male presented to us with chief complaints of pain while micturiting since 2 years. The child would occasionally cry due to the pain experienced while voiding. The stream was poor. There was no history of any hematuria or any recurrent episodes of fever. The general physical examination of the child was normal. The routine blood investigations were also normal with 1-2 pus cells/HPF in urine examination. Ultrasonography of the abdomen showed with normal wall thickness of

bladder with slight mucosal irregularity and the cavity-contained debris. There were no upper urinary tract changes. A calculus of size 9x8x5 mm was noted in the prostatic urethra with residual urine 12 cc (Figure 1). Plain Xray Abdomen/Pelvis showed calculi at the level of prostatic urethra (Figure 2).

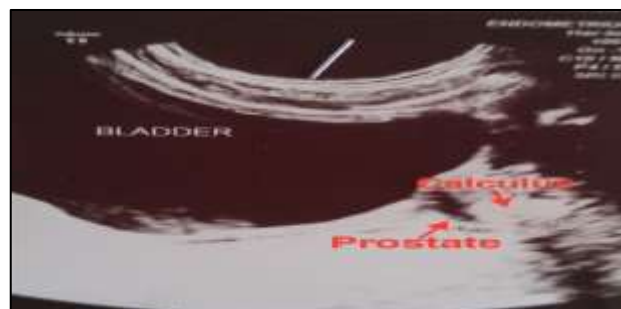


Figure 1: Ultrasound showing calculi in prostatic urethra.

Further imaging was done for the calculi. RGU/MCU was done which showed presence of high bladder neck, markedly dilated posterior urethra along with presence of a calculus in it. There was presence of PUV distal to the calculi (Figure 3). The patient was subsequently posted for cystoscopy and findings of posterior urethral valve type 1 along with a dilated posterior urethra harboring a stone of approximately 9 mm was seen (Figure 4). Note was also made of high bladder neck along with some debris and, mucosal irregularities in the bladder. Fulguration of Posterior urethral valves was done using a Bugbee electrode and incisions were given a 4,8 and 12'o clock position (Figure 5). The pneumatic lithotripter was used to fragment the stone in the urethra. Larger fragments were removed using a tripod forceps (Figure 6). Bladder was checked to see small fragments, which were removed by washes (Figure 7).

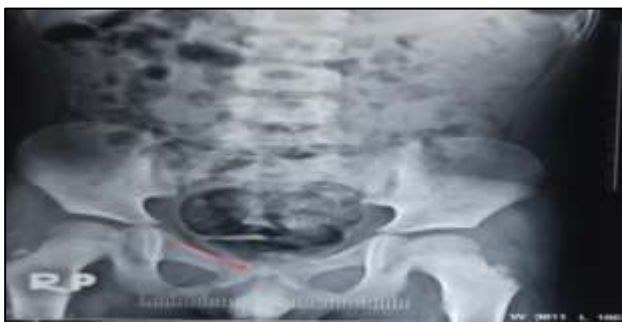

Figure 2: Plain x ray film showing calculi at the level of prostatic urethra.

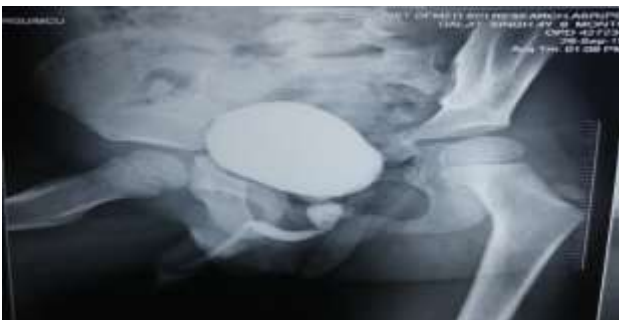

Figure 3: RGU MCU showing urethral calculi with dilated posterior urethra and high bladder neck.

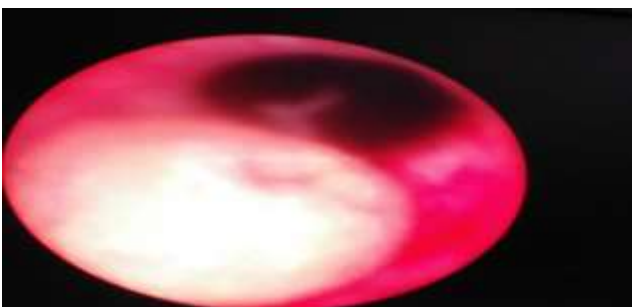


Figure 4: Cystoscopy showing large stone in the prostatic urethra, bladder neck seen.

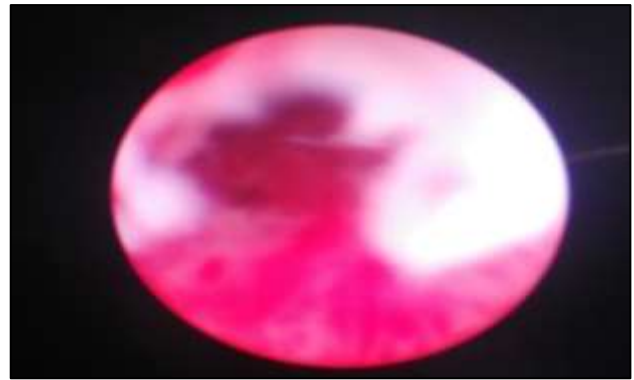


Figure 5: Fulgurated posterior urethral valve.

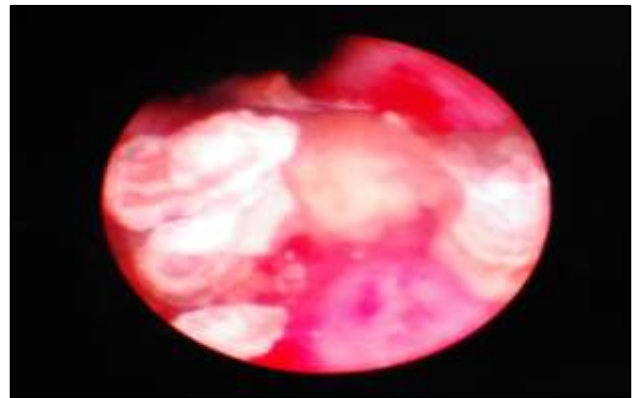


Figure 6: Fragmented stone in the urethra.

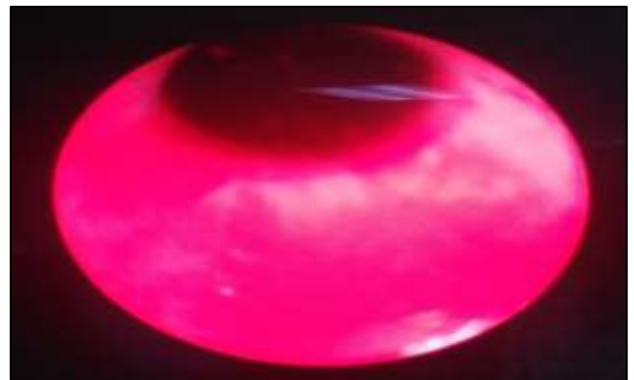


Figure 7: Urethra clear of stone and fragments.

The postoperative period of the patient was uneventful and the patient was discharged on POD 4.

DISCUSSION

Posterior urethral valves are the commonest cause of urinary tract obstruction in male neonates.¹ These days widespread use of antenatal USG has enabled in early detection of PUV. It is generally diagnosed and treated early in neonatal age but sometimes the children present late. The presentation can range from bladder dysfunction resulting in incontinence and poor emptying, life threatening pulmonary hypoplasia to minor voiding

difficulties. Poor urinary stream is seen in only 10% of patients. A urethral calculus in children is rare and its association with posterior urethral valve is still rarer with few case reports worldwide.²⁻⁴

The manifestations of urethral calculus are hematuria and pain while voiding. These symptoms can overlap with those of Posterior urethral valve and may be difficult to diagnose whether the pain is due to PUV or stone. Also in delayed presentations both can cause Urinary tract infections, nocturnal enuresis and dribbling of urine.⁵

Radiological investigations are very important to pick up a calculus in urethra especially when such patients are initially suspected to only ultrasounds. In our case the patient had undergone repeated ultrasounds from periphery where the calculus in the urethra wasn't picked. Plain abdominal x-ray KUB is also important which can show presence of calculus in the bladder or urethra. RGU/MCU must be done to evaluate the status and type of posterior urethral valve while planning treatment. The RGU/MCU can also be confusing to figure whether the dilatation is due to PUV or the stone causing obstruction.

Cystoscopy with fulguration of valves with urethrolitomy will correct such patients. Fulguration should be followed by lithotripsy of the stone so as the fragments are removed easily during washes. In conclusion we would like to state that Stone in the urethra along with posterior urethral valve is a very rare

presentation and a high index of suspicion must be made for these 2 conditions to present together.

Funding: No funding sources

Conflict of interest: None declared

Ethical approval: Not required

REFERENCES

1. Atwell JD. Posterior urethral valve in the british isles: a multicentric B.A.P.S. review. J Pediatr Surg. 1983;18(1):70-4.
2. Neulander E, Kaneti J .Posterior urethral valves and vesicolithiasis in children. Int Urol Nephrol. 1996;28(4):563-8.
3. Sinha A, Sarin YK, Sengar M. Posterior urethral valves associated with urethral calculi. Indian J Urol. 2001;18(1):84-5.
4. Khandelwal AK. Posterior Urethral Valve with a bladder stone:A case report. UroToday Int J. 2013;6(5):66.
5. Bomalaski MD, Anema JG, Copen DE, Koo HP, Rozanski T, et al. Delayed presentation of posterior urethral valves: a not so benign condition. J Urol. 1999;162(6):2130-2.

Cite this article as: Shah AS, Bhangu GS, Sandhu RS, Ded KS, Mann SK. Posterior urethral valve presenting with urethral stone: a challenging diagnosis. Int Surg J 2016;3:2254-6.