

## Original Research Article

# Cervical spondylosis: analysis of clinical and radiological correlation

RoseBist P. K.<sup>1\*</sup>, Anil Kumar Peethambaran<sup>1</sup>, Gowri Anil Peethambar<sup>2</sup>

<sup>1</sup>Department of Neurosurgery, <sup>2</sup>Medical Student, Government Medical College, Thiruvananthapuram, Kerala, India

**Received:** 10 January 2018

**Accepted:** 15 January 2018

### \*Correspondence:

Dr. RoseBist P. K.,

E-mail: [doctorrosebist@gmail.com](mailto:doctorrosebist@gmail.com)

**Copyright:** © the author(s), publisher and licensee Medip Academy. This is an open-access article distributed under the terms of the Creative Commons Attribution Non-Commercial License, which permits unrestricted non-commercial use, distribution, and reproduction in any medium, provided the original work is properly cited.

## ABSTRACT

**Background:** Cervical spondylosis is a chronic degenerative lesion of the cervical intervertebral discs causing axial neck pain, cervical radiculopathy and myelopathy. This study was undertaken to study the clinical and radiological correlation in cervical spondylosis with respect to clinical and radiological findings.

**Methods:** A prospective observational study was done on 100 patients with cervical spondylosis treated in a tertiary care centre of South Kerala. The sociodemographic details, clinical and radiological findings were recorded. Nurick's grading and Modified Japanese orthopaedic association cervical spine myelopathy scoring was done. Data collected was analyzed using Microsoft Excel 2010 and results expressed in proportions.

**Results:** Maximum prevalence was seen in 40-49 years group with male predominance. Majority of the patients had neck pain, sensory numbness and motor weakness. Spurling's sign and Lhermitt's sign was positive in 60% and 47% patients respectively. Complete paralysis was seen on both sides in 12% patients at wrist joint and 9% each in elbow and knee joints. Grade II cervical spondylosis was seen in 43%. Modified Japanese orthopaedic association score was less than 18 in all patients. Canal size was reduced in many. The clinical and radiological findings were consistent.

**Conclusions:** Cervical spondylosis is seen in those above 30 years of age with male predominance. Clinical and radiological findings are consistent with each other. Further studies are advised for better correlation.

**Keywords:** Cervical spondylosis, Myelopathy, Pain, Radiculopathy, Spinal canal

## INTRODUCTION

The term cervical spondylosis describes chronic degenerative lesions of multiple or single cervical intervertebral discs and the consequent formation of osteophytes on related vertebral bodies. It is a leading cause of musculoskeletal disability in human beings.<sup>1</sup> The sequence of disc degeneration leads to the clinical syndrome of cervical pain, cervical radiculopathy and cervical myelopathy.<sup>2</sup> The disease is multifactorial. Advancement of age, occupational heavy loading, trauma, whole body vibration etc are possible risk factors.<sup>3,4</sup> Smoking and genetic factors also contributes to the structural changes in spine.<sup>5-7</sup> Most common

degenerative change is seen in C<sub>5</sub>-C<sub>6</sub> followed by C<sub>6</sub>-C<sub>7</sub> and C<sub>4</sub>-C<sub>5</sub>.<sup>8</sup> The pain usually responds to activity modification, neck immobilisation, isometric exercises and medication. Cervical radiculopathy often responds favourably to conservative management but if there is persistence of pain or progressive neurological deficits, then surgery should be attempted through anterior or posterior cervical spine. Cervical spondylotic myelopathy is however a serious disabling condition.<sup>9</sup>

Cervical spondylosis is usually diagnosed on clinical grounds. A complete neurological evaluation should also be done to exclude diseases like amyotrophic lateral sclerosis. Radiological investigations like plain X-ray spine, CT scan, Myelography and Magnetic resonance

imaging may be used to detect the source and extent of neurological compression. This study was undertaken to study the clinical and radiological correlation in cervical spondylosis with respect to clinical and radiological findings.

## METHODS

This prospective observational study was done in 100 patients who were diagnosed to have cervical spondylosis in a tertiary care teaching hospital in South Kerala. Patients of both gender, more than 18 years of age, showing signs and symptoms of cervical spondylosis and willing to give informed consent were included in the study. Patients with amyotrophic lateral sclerosis, metastatic tumours, hereditary spastic paraplegia, multiple sclerosis, motor neuron disease, syringomyelia, tuberculosis, other causes of peripheral neuropathy etc were excluded from the study. The sociodemographic details, symptoms and signs (pain, sensory loss, motor weakness, clinical signs like spurling's sign, Lhermitt's sign, grading of muscle power of different joints, examination of spine, dermatomal variations in pain sense and light touch etc) were recorded in a predesigned proforma. Details of X-ray and MRI findings in these patients were also recorded. Nurick's grading and modified Japanese orthopaedic association cervical spine myelopathy scoring was also done.

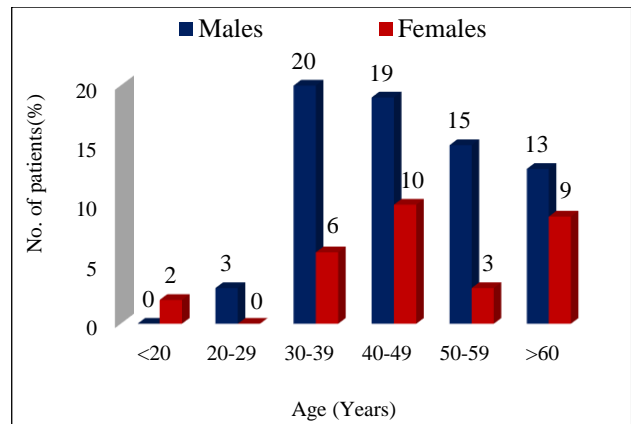
## Statistical analysis

Data collected was entered in Microsoft Excel 2010 and analysed. Results were expressed in proportions.

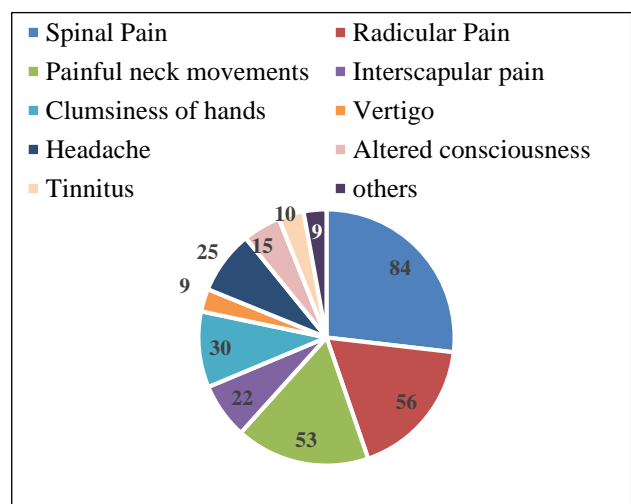
## RESULTS

This study was done in 100 patients diagnosed to have cervical spondylosis. 69% were males and 31% were females. Patients between 40-49 years of age showed the maximum prevalence of the disease (29%), followed by 30-39 years group (26%). 22% patients with cervical spondylosis were over 60 years of age. Above the age of 20 years, prevalence was more in males than females. 20% of males in 30-39 years group and 19% males in 40 - 49 years group showed symptoms and signs of cervical spondylosis (Figure 1). 32% of the study population were manual labourers and there was a history of trauma to head and neck region in 61% patients.

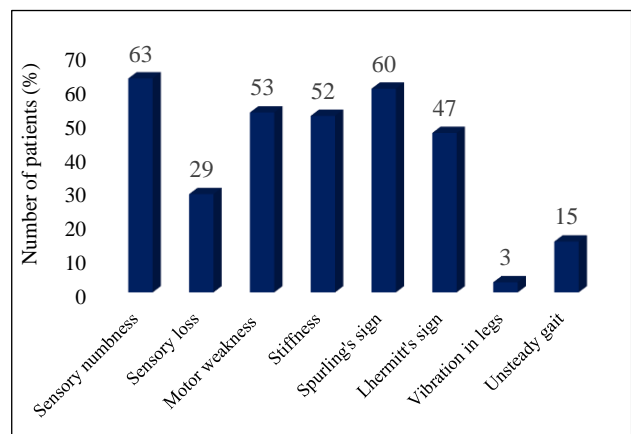
Figure 2 shows the symptom wise distribution of patients. 84% patients had spinal pain, 56 % had radicular pain. Interscapular pain was seen in 22 % only (Figure 2). 53 patients had complaints of painful neck movements. Majority of the patients (88%) showed a combination of these pain (Figure 2). Sensory numbness and motor weakness was present in 63% and 53% patients respectively. 50% showed stiffness in neck region also. Spurling's sign and Lhermitt's sign was positive in 60% and 47% patients respectively. Gait was unsteady in 15 % (Figure 3).



**Figure 1: Percentage distribution of patients in relation to age and gender.**



**Figure 2: Symptom wise distribution of patients.**



**Figure 3: Clinical findings in the patients.**

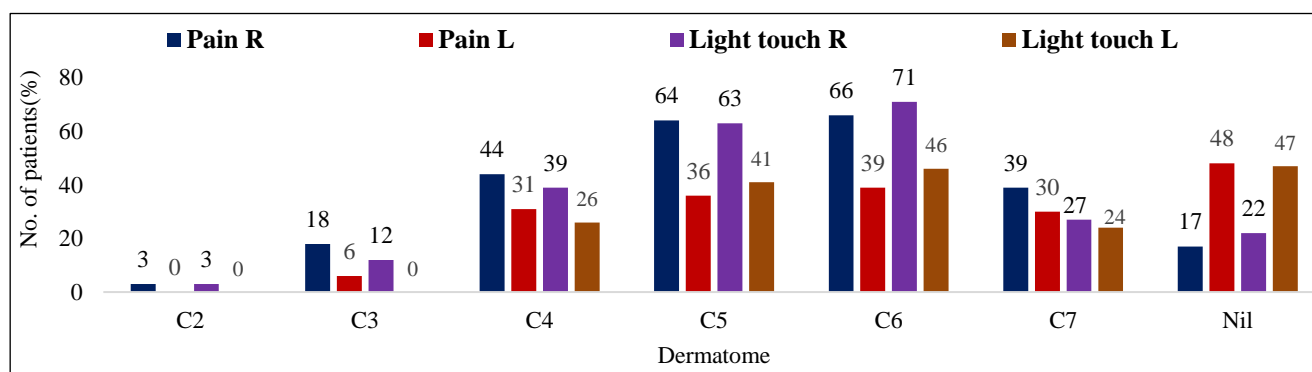
The power score of different joints on both sides are depicted (Table 1). Complete paralysis was seen on both sides in 12 % patients at wrist joint and 9% each in elbow and knee joints. Normal power was seen in 56% in shoulder joint, 34% in elbow joint, 35% in wrist joint.

More than 50% showed normal power in hip joint, knee joint and ankle joints.

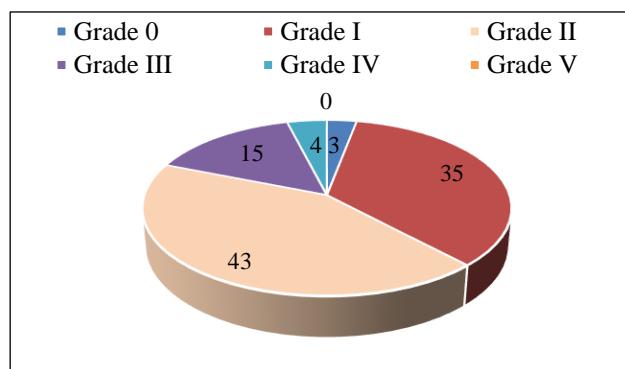
**Table 1: Frequency distribution of power score in different joints.**

Power	Sh JT		Elb JT		Wrist JT		Hip JT		Knee JT		Ank JT	
	R	L	R	L	R	L	R	L	R	L	R	L
Complete paralysis	3	6	9	9	12	12	3	6	9	9	6	6
Flicker of contraction	0	0	0	0	0	0	0	0	0	0	0	0
Power detected only when gravity excluded	19	16	27	27	24	24	16	16	15	15	4	4
Perform against gravity	0	0	0	0	0	0	0	0	0	0	16	16
Some degree of weakness	22	22	30	30	29	29	21	21	23	26	15	18
Normal power	56	56	34	34	35	35	60	57	53	50	59	56

(Sh jt - shoulder joint, Elb jt - Elbow joint, Ank jt - Ankle joint)



**Figure 4: Dermatomal distribution of pain sense and light touch.**

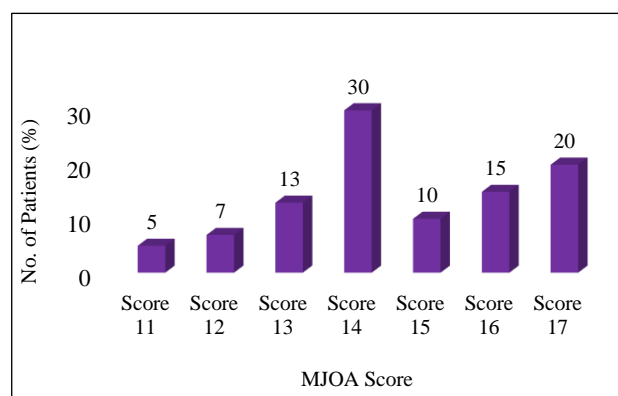


**Figure 5: Distribution of patients based on Nurick's grade.**

The dermatomal distribution with regards to pain sensation and light touch on both sides of the body (Figure 4). The left side was affected more in the perception of pain and light touch sensations from C<sub>2</sub> to C<sub>6</sub> dermatomes. Pain could be perceived by 18% in C<sub>3</sub>, 44% in C<sub>4</sub>, 64% in C<sub>5</sub>, 66% in C<sub>6</sub> and 39% in C<sub>7</sub> dermatomes on the right side (Figure 4).

Grade II cervical spondylosis was seen in 43%, grade I in 35% and grade III in 15% patients when Nurick's grading criteria was used (Figure 5). Modified Japanese orthopaedic association scoring of these patients showed

that 30% had score 14 and 20% had score 20. Score 13, score 16 and score 17 was seen in 13%, 10% and 15% patients respectively (Figure 6). Figure 7 and 8 depicts the X-ray findings and MRI findings of these patients respectively. Straightening in 71%, disc herniation in 10%, narrowing of canal in 18% and osteophytes in 65% patients (Figure 7).

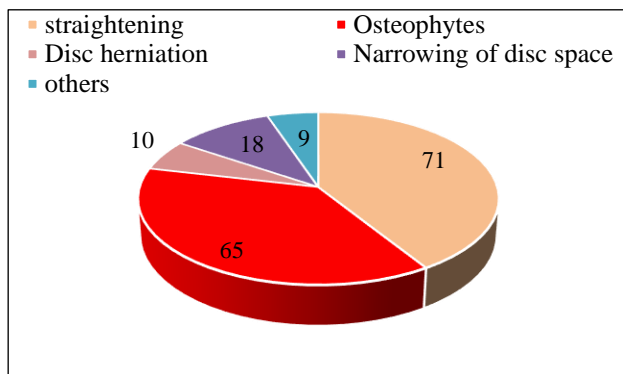


**Figure 6: MJOA scoring of patients.**

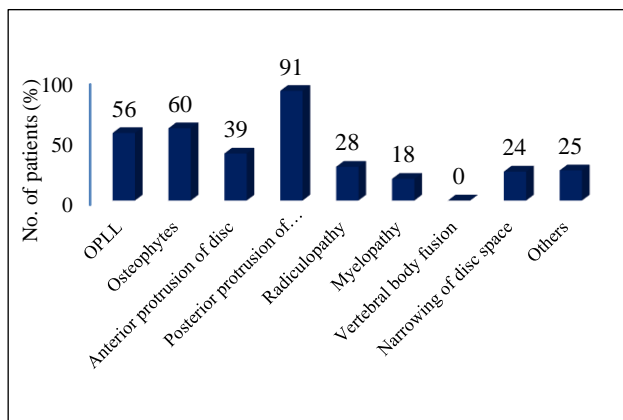
**Table 2: Canal size in patients.**

Dermatome	Canal Size	
	<13 mm	>13 mm

C2	43	57
C3	86	14
C4	87	13
C5	79	21
C6	75	25
C7	71	29



**Figure 7: X-ray findings of the patients.**



**Figure 8: MRI findings of the patients.**

**Table 3: Frequency of patients showing myelopathy, radiculopathy and myeloradiculopathy based on clinical and radiological impression.**

Feature	Clinical impression	Radiological impression
Myelopathy	27	29
Radiculopathy	53	59
Myeloradiculopathy	20	12

However, MRI findings as depicted in figure 8 showed osteophytes in 60% and narrowing of the disc space in 24% patients. The canal size was less than 13 mm at C<sub>4</sub> in 87% and at C<sub>3</sub> in 86% patients. It was reduced in C<sub>5</sub>, C<sub>6</sub> and C<sub>7</sub> levels in 79%, 75% and 71% patients respectively (Table 2). Proportion of patients showing myelopathy, radiculopathy and myeloradiculopathy based on clinical and radiological impression is depicted (Table 3). Chi-square test value was 66.374 with a significant p value (less than 0.001).

## DISCUSSION

Cervical spondylosis usually presents in patients between the ages of 40 and 60 years, with a male to female ratio of 3:2.<sup>10</sup> In this study, patients over 30 years of age were mainly affected. Maximum prevalence was seen between 40-49 years of age. There were only 5 cases where the patients were less than 30 years of age. Male preponderance was seen from 20 years of age.

Trauma to neck and acute insult to neck contributes to development of cervical spondylosis. Degenerative changes occur in cervical spine early in manual labourers doing heavy work because when a load is applied to arms to be placed on head, the weight of the load is transferred to cervical spine through muscles of arm.<sup>11</sup> 32% of the study population were manual labourers and there was a history of trauma affecting head and neck region in 61% patients in this study.

In cervical spondylosis, chronic disc degeneration results in increased mechanical stressors passing through cervical spinal column and cause osteophyte formation and secondary degenerative changes in facet joints, posterior longitudinal ligaments and ligamentum flavum.

These changes along with associated nerve involvements lead to the three clinical syndromes in cervical spondylosis like axial neck pain, cervical radiculopathy and cervical myelopathy.<sup>10</sup> Axial neck pain is commonly seen in clinical practice and when it is due to cervical spondylosis, headache is often associated in one third of these cases.<sup>9,12</sup> 53% patients had painful neck movements and 25% had headache in this study. Radicular pain occurs due to irritation of inflamed nerve roots.<sup>12</sup> Usually 6<sup>th</sup> and 7<sup>th</sup> roots are affected most. Pain in arms, neck and scapular region, sensory and motor deficits, paraesthesia etc are seen.<sup>13,14</sup> Radicular pain was seen in 56% patients, interscapular pain in 22%, sensory numbness in 63% and motor weakness in 53% patients in this study.

Perception of pain and light touch was affected in many patients. Power of most of the joints were affected in the patients. Complete paralysis was seen on both sides in 12% patients at wrist joint and 9% each in elbow and knee joints. Symptoms of cervical radiculopathy are aggravated by spurling's manoeuvre which describes extension or lateral rotation of head to side of pain.<sup>15</sup> Spurling's sign was positive in 60% patients suggesting radiculopathy in this study.

Narrowing of spinal canal can cause spinal cord compression and cervical spondylosis myelopathy.<sup>10</sup> It has an insidious onset and can present as neck stiffness, clumsiness of hands, reduced fine motor skills, awkward gait etc.<sup>15</sup> In present study, 30% patients had complaints of clumsiness of hands and 52% had stiffness in neck. Unsteadiness in gait was observed in 15% patients. Lhermitt's sign which describes extension and flexion of neck eliciting electric shock like sensation in extremities

was positive in 47% patients.<sup>9</sup> All these were suggestive of cervical myelopathy.

Nurick's grading criteria was used for functional grading of cervical spondylosis in the patients. 35% patients had grade I, 43% had grade II and 15% had grade III cervical spondylosis. Modified Japanese Orthopaedic Association Cervical spine myelopathy functional assessment scale (MJOA scale) was also used to score these patients. The score of a normal person according to this scale is 18. In all the patients, the MJOA scale score was less than 18.

Diameter of spinal canal, narrowing of disc space, osteophyte formation, facet degeneration, vertebral subluxation, bony abnormalities, ossification in posterior longitudinal ligaments (OPLL) etc can be assessed using radiological imaging techniques like X-rays or Magnetic resonance imaging. In normal adults, anteroposterior diameter of sub-axial spine is 17-18mm.

A score less than 13mm is indicative of developmental stenosis and predisposes to myelopathy.<sup>16</sup> In this study, more than 70% patients showed a canal size less than 13mm from C<sub>3</sub> to C<sub>7</sub>. In 43% patients, it was reduced at C<sub>2</sub> level also. Straightening, disc herniation, narrowing of canal, Osteophytes, OPLL etc were detected in many of the patients. The radiological findings were consistent with the clinical findings in the patients and p value was significant (less than 0.001).

## CONCLUSION

Cervical spondylosis is a degenerative disease seen in those above 30 years of age with a male preponderance and can present as axial neck pain, cervical radiculopathy or cervical spondylotic myelopathy. There is good correlation between clinical findings and radiological findings. However, studies may be undertaken with larger sample size for better correlation.

## ACKNOWLEDGEMENTS

Authors would like to thank all the patients who participated in the study.

*Funding: No funding sources*

*Conflict of interest: None declared*

*Ethical approval: The study was approved by the Institutional Ethics Committee*

## REFERENCES

1. Brooker AEW, Barter RW. Cervical spondylosis: A clinical study with comparative radiology. *Brain* 1965;88:925-36.
2. Lestini WF, Wiese SW. The pathogenesis of cervical spondylosis. *Clinical Orthop.* 1989;239:69-93.
3. Frymoyer JW. Back pain and Sciatica. *New Eng J Med.* 1988;318:291-9.
4. Anderson GBJ. The epidemiology of spinal disorders. In JW Frymoyer (ed): *The adult spine: Principles and Practice*, Raven press: New York; 1991:107-146.
5. Ernst E. Smoking, a cause of back trouble? *Br J Rheumatol.* 1993;32:239-42.
6. Wiltse LL. The etiology of Spondylolisthesis. *J Bone Joint Surg.* 1962;44:539-60.
7. Wynne-Davies R, Scott JH. Inheritance and spondylolisthesis: a radiographic family survey. *J Bone Joint Surg.* 1979;61(3):301-5.
8. Matsumoto M, Fujimura Y, Suzuki N. MRI of cervical intervertebral discs in asymptomatic subjects. *J Bone Joint Surg.* 1998;80(1):19-24.
9. McCormack BM, Weinstein PR. Cervical spondylosis an update. *West J Med.* 1996;165(1-2):43-51.
10. Kelly JC, Groarke PJ, Butler JS, Poynton AR, O'Byrne JM. The natural history and clinical syndromes of degenerative cervical spondylosis. *Advances in Orthopaedics.* 2012;2012.
11. Hayashi K. Origin of the uncus and of luschka's joint in the cervical spine. *J Bone Joint Surg.* 1995;67A: 788-91.
12. Holler JG. The syndromes of degenerative cervical disease. *Orthopedic clinics of North America.* 1992;23(3):381-94.
13. Ellenberg HR, Honet JC, Treanor WJ. Cervical radiculopathy. *Archives of physical Medicine and rehabilitation.* 1994;75(3):342-52.
14. Davidson RI, Duun EJ, Metzmaker JN. The shoulder abduction test in diagnosis of radicular pain in cervical extradural compressive pressure monoradiculopathies. 1981;6 (5):41-6.
15. Rao RD, Currier BL, Albert TJ. Degenerative cervical spondylosis: Clinical syndrome, pathogenesis and management. *J Bone joint Surg.* 2007;89(6):1360-78.
16. Bohlman HH. Cervical spondylosis and myelopathy. *Instructional course lectures* 1995;44:81-97.

**Cite this article as:** RoseBist PK, Peethambaran AK, Peethambar GA. Cervical spondylosis: analysis of clinical and radiological correlation. *Int Surg J* 2018;5:491-5.