

## Original Research Article

# Comparative study of aspiration versus non-aspiration fine needle technique in thyroid nodule and its correlation with post-operative histopathological examination

Harish Kumar C.\*, Yaam Kumar C.

Department of General Surgery, Bangalore Medical College and Research Institute, Bangalore, Karnataka, India

**Received:** 04 January 2018

**Revised:** 13 January 2018

**Accepted:** 31 January 2018

### \*Correspondence:

Dr. Harish Kumar C.,

E-mail: [drharry1986@gmail.com](mailto:drharry1986@gmail.com)

**Copyright:** © the author(s), publisher and licensee Medip Academy. This is an open-access article distributed under the terms of the Creative Commons Attribution Non-Commercial License, which permits unrestricted non-commercial use, distribution, and reproduction in any medium, provided the original work is properly cited.

## ABSTRACT

**Background:** Thyroid gland is unique of all endocrine glands because it is the largest, superficial and the only one amenable to direct physical examination. A discrete swelling in one lobe and with no palpable abnormality elsewhere is termed as solitary swelling. Fine needle aspiration cytology (FNAC) is the investigation of choice in solitary thyroid swellings. There is another technique fine needle non aspiration cytology (FNNAC) which avoids aspiration but still permits cytologic review of the swellings which can also be done in thyroid swellings. The objective of the study was to compare and analyze the preoperative efficiency of FNAC vs FNNAC in solitary thyroid nodules and its correlation with post-operative histopathological examination findings.

**Methods:** A total of 72 patients presenting with thyroid nodule in this hospital in BMCRI, Bengaluru during period of January 2017 to December 2017 underwent both FNAC and techniques. 23 G needles were used for both FNAC and FNNAC. FNAC was performed using needle and a syringe using aspiration. In FNNAC technique the needle held between thumb and fore finger of one hand was gently inserted into the nodule and was moved in different directions. Material entering the needle hub by capillary action was then expressed onto clean glass slides after attaching syringe filled with air to it and smears were prepared. Cases which underwent total/hemi thyroidectomy, the specimen was sent to pathology department in 10% formalin solution.

**Results:** FNNAC produced diagnostically superior samples and less diagnostically inadequate samples than FNAC.

**Conclusions:** As thyroid is a vascular and a colloid organ, in FNAC aspiration gives blood/colloid with less cellular architecture in most of the cases. In FNNAC cellular architecture was preserved with less blood/colloid background which aids in easier cytological diagnosis. Hence FNNAC is a better technique than FNAC in cytological diagnosis of solitary thyroid nodule.

**Keywords:** FNAC, FNNAC, Solitary thyroid nodule, Thyroid swelling, Thyroid lesions

## INTRODUCTION

The thyroid disorder is the most common endocrine disorder seen in clinical practice. Lesions of thyroid are predominantly confined to females in the ratio of 5:1, and this has been attributed to variations of thyroid hormone demand during female reproductive function and

physiological events such as puberty, pregnancy and lactation. A discrete swelling (nodule) in one lobe with no palpable abnormality elsewhere is termed as solitary (or isolated) swelling. Nodules appear early in endemic goitre and later (between 20 and 30 years) in sporadic goitre, although the patient may be unaware of the goitre until his or her late 40s or 50s. All types of simple goitre

are more common in the female than in the male owing to the presence of oestrogen receptors in thyroid tissue.<sup>1-3</sup>

Objectives of the study was to correlate the cytological diagnosis of thyroid swelling by FNAC and by FNNAC with histopathological diagnosis on excision biopsy.

Compare and analyze preoperative efficiency of FNAC vs FNNAC in various thyroid lesions.

## METHODS

It is a prospective study been conducted by utilizing the cases diagnosed clinically as solitary nodule of thyroid and treated on inpatient basis in the Department of General Surgery at Bowring and Lady Curzon Hospital and Victoria Hospital, Bangalore from January 2017 to December 2017 were included in the study. The patients were selected according to the inclusion and exclusion criteria as mentioned below.

### Inclusion criteria

Patients of age group 18-70 years who are clinically diagnosed to have a solitary thyroid swelling and who are consenting for FNAC, FNNAC and surgery.

### Exclusion criteria

- Patients with diffuse enlargement of thyroid and thyrotoxicosis.
- Patients refusing for investigations / surgery.

All the cases were studied in detail clinically and recorded as per the proforma. All relevant investigations were done whenever indicated.

After obtaining consent for FNNAC and FNAC of Thyroid Swelling, Thyroid swelling in every patient was sampled by both aspiration as well as non-aspiration by a single operator. To maintain consistency of results, non-aspirate was always performed before the aspirate technique and marked as slides "A" and "B" randomly to avoid bias of pathologist, that is, in some cases FNAC was marked as slides "A" and FNNAC as slides "B" and at times FNNAC was marked as slides "A" and FNAC as slides "B". Both procedures were done using 22 or 23 gauge needle. Fine needle aspiration was performed using a 10 ml syringe, while the non-aspirate technique was done without syringe or holder. The needle held between thumb and forefinger of aspirating hand, was inserted into the nodule and moved in different directions within the nodule. The material entering the hub of the needle by capillary action was then expressed onto clean glass slides after attaching an air filled syringe to it. All smears were interpreted by a single pathologist. The pathologist was unaware of sampling method employed (FNAC/FNNAC).

Apart from diagnosis, comments were made on the quality of slides. For this, proper three qualitative categories were created. They are:

- *Diagnostically Inadequate Sample (DIS)*: Consisted mainly of red blood cells or absent cellularity making them inadequate for cytodiagnosis.
- *Diagnostically Adequate Sample (DAS)*: Possible to render an opinion on nature of lesion sampled but the cellular material present was sub-optimal due to poor cellularity, sample dilution, degenerative changes, or specimen entrapment in blood clots.
- *Diagnostically Superior Sample (DSS)*: Cell aggregates were prominent, well preserved, and unobscured by background blood and cellular morphology was well displayed.

A single pathologist was requested to classify the slides as mentioned above and interpret the slides to come to a diagnosis, so that erratic classification of slides by different pathologist is overcome.

All pts who underwent FNNAC and FNAC and were willing for surgery for any reason i.e., mainly for cosmetic reason or fear of malignancy etc were subjected for appropriate surgery. All the specimens were sent for histopathological examination and was followed up. Patients were discharged and were asked to come for follow up. They were advised to take needful medications accordingly. FNAC and FNNAC results were compared with post-operative Histopathological Examination report accordingly. The results of the present study were compared with other studies.

## RESULTS

### Age incidence

The age of the patients with solitary nodule in the present study varied from 20 years being the youngest to 65 years being the oldest. The peak age incidence was found in 3<sup>rd</sup> and 4<sup>th</sup> decades of life. The mean age of all patients was 37.05 years. The mean age for females was 36.92 years and that for males was 38.5 years.

**Table 1: Age distribution in present study.**

| Age in years | Females | Males | Total | Percentage |
|--------------|---------|-------|-------|------------|
| 0-9          | 0       | 0     | 0     | 0          |
| 10-19        | 0       | 0     | 0     | 0          |
| 20-29        | 15      | 3     | 18    | 25         |
| 30-39        | 27      | 0     | 27    | 37.5       |
| 40-49        | 12      | 1     | 13    | 18.1       |
| 50-59        | 9       | 1     | 10    | 13.9       |
| 60-69        | 3       | 1     | 4     | 5.5        |
| Total        | 66      | 6     | 72    | 100        |

The peak incidence was seen in 4<sup>th</sup> decade of life with 37.50% of patients. Patients in 3<sup>rd</sup> and 4<sup>th</sup> decade of life constituted 62.5% of total patients.

The peak incidence was seen in 4<sup>th</sup> decade of life with 37.50% of patients. Patients in 3<sup>rd</sup> and 4<sup>th</sup> decade of life constituted 62.5% of total patients.

### Sex incidence

Solitary nodule of thyroid was found to be more common in females than in males. Out of 72 cases 66 were females and 6 were males. Male to female ratio was 1:11.

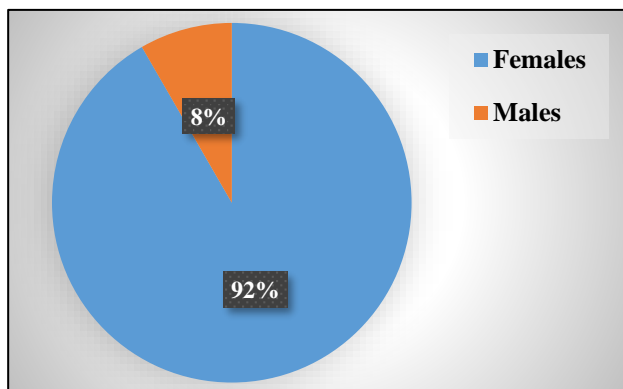


Figure 1: Sex distribution.

Table 2: Distribution of solitary thyroid nodule in present study.

| Site       | Number | Percentage |
|------------|--------|------------|
| Right Lobe | 47     | 65         |
| Left Lobe  | 25     | 35         |
| Isthmus    | 0      | 0          |
| Total      | 72     | 100        |

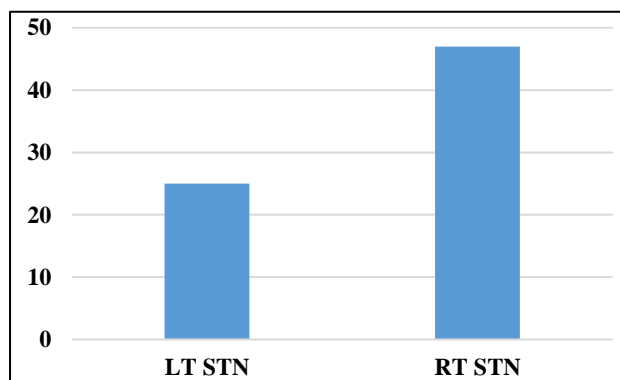


Figure 2: Site distribution.

### Distribution of cases as per FNAC and FNNAC results

After FNAC and FNNAC the cytology reports were labelled as Diagnostically Inadequate Sample (DIS), Diagnostically Adequate Sample (DAS) and

Diagnostically Superior Samples (DSS) and were tabulated as follows:

Table 3: Distribution of cases as per FNAC and FNNAC results.

|       | FNAC | FNNAC |
|-------|------|-------|
| DIS   | 14   | 11    |
| DAS   | 48   | 47    |
| DSS   | 10   | 14    |
| TOTAL | 72   | 72    |

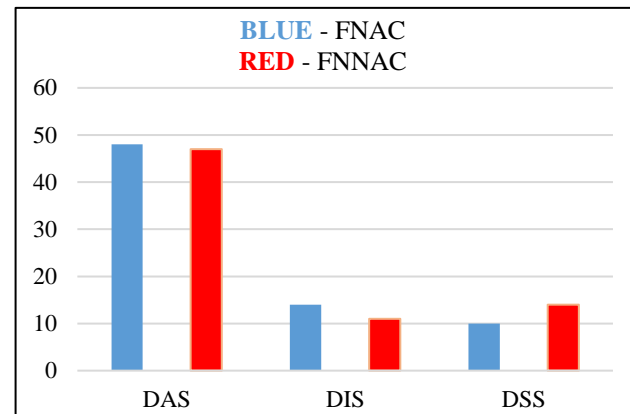


Figure 3: Comparison of FNAC and FNNAC.

Table 4: Distribution of cases according to HPE findings.

| HPE results  | Number of cases |
|--|-----------------|
| Nodular goitre                                       | 51              |
| Papillary carcinoma of thyroid                       | 7               |
| Follicular variant of papillary carcinoma of thyroid | 6               |
| Follicular adenoma                                   | 5               |
| Colloid cyst   | 2               |
| Follicular carcinoma of thyroid                      | 1               |
| Total number of cases                                | 72              |

Table 5: Comparison of FNAC and FNNAC with HPE.

|  | HPE | FNAC | FNNAC |
|--|-----|------|-------|
| <b>Benign</b>  |     |      |       |
| Nodular goitre                                       | 51  | 41   | 41    |
| Follicular adenoma                                   | 5   | 3    | 3     |
| Colloid cyst   | 2   | 2    | 2     |
| <b>Malignant</b>                                     |     |      |       |
| Papillary carcinoma of thyroid                       | 7   | 2    | 2     |
| Follicular variant of papillary carcinoma of thyroid | 6   | 2    | 5     |
| Follicular carcinoma of thyroid                      | 1   | 0    | 0     |
| Total  | 72  | 50   | 53    |

Out of total 72 cases 58 cases were benign and 14 cases were malignant. Out of total 72 cases 50 cases were correctly identified by FNAC and 53 cases were correctly diagnosed by FNNAC. Out of 58 benign cases 46 cases were correctly identified by both FNAC and FNNAC. Out of 14 malignant cases 4 cases were correctly identified by FNAC and 7 cases were correctly identified by FNNAC.

1. Number of cases found to be diagnostically superior by FNNAC were 14/72 (19.44%).
2. Number of cases found to be diagnostically superior by FNAC were 10/72 (13.88%).
3. Number of cases found to be diagnostically inadequate or unsuitable by FNAC was 14/72 (19.44%).
4. Number of cases found to be diagnostically inadequate or unsuitable by FNNAC was 11/72 (11.6%).
5. Number of cases found to be diagnostically adequate by both FNAC and FNNAC were almost equal but were slightly more in FNAC such as in FNAC 48/72 (66.66%) and in FNNAC 47/72 (65.27%).
6. All the 72 cases were correlated with final histopathology report.
7. Out of 72 cases, 14 cases were neoplastic and 58 cases were benign. Incidence rate of malignancy in solitary thyroid nodule in this study is 19.44%.
8. In both neoplastic and benign group, the diagnostic ability of FNNAC was better than FNAC.
9. Sensitivity of FNAC and FNNAC is 89.29% and 89.83%.
10. Specificity of FNAC and FNNAC is 87.5% and 84.62%.
11. Positive Predictive Value of FNAC and FNNAC are 96.15% and 96.36%.
12. Negative Predictive value of FNAC and FNNAC are 70% and 64.71%.
13. By the statistical analysis FNNAC is better than FNAC.

## DISCUSSION

Solitary thyroid nodule is a common clinical problem though varying in incidence in different geographical regions. In this study a total of 72 patients diagnosed clinically as solitary thyroid nodule were subjected to FNAC and FNNAC followed by surgery and then the specimen was sent for HPE. And the results of FNAC and FNNAC was compared with that of HPE findings.

In this study the age of patients ranged from 20 to 65 years of age with mean age of 37.05 years. Majority (37.5%) of these patients were between the age group of 30-39 years followed by 25% in age group of 20-29 years, least (5.5%) was in age group of 60-69 years. This study correlates with study done by Tauro where mean age was 39.16 years and Ranvir where mean age was 37

years.<sup>7,10</sup> This differs from the study by Purushoththam where mean age of presentation was 46 years.<sup>6</sup>

In this study solitary thyroid nodule were more common in females (92 %) than in males (8%). This correlates with study done by Nyontono where 84 patients were females and 4 were males.<sup>5</sup> This also correlates with the study done by Purushoththa, Ranvir, Tauro, Ramachandra also showed female preponderance.<sup>4,6,7,10</sup>

Right lobe (65%) of thyroid was most commonly involved lobe of thyroid than the left lobe (35%) in my study. In this study there was no involvement of isthmus.

A total of 81% patients had benign thyroid lesion which was suggestive of nodular colloid goitre, Follicular Adenoma and Colloid cyst. 19% of the patients had malignant thyroid lesions like Papillary carcinoma of thyroid and Follicular carcinoma.

Fine Needle aspiration cytology has been well established as the base line investigation in evaluating the thyroid nodules. It is known for many advantages it provides like, simple technique, safe, rapid turn-around time etc. It provides the primary information and or diagnosis which helps in choosing the further rightful management of the thyroid lesions. Being a blind technique, it has a few drawbacks limiting its clinical utility.

A major limitation of FNA of thyroid is blood in the samples, which interferes in the interpretation of the slide, thus leading to inferior quality samples. To combat this, non-aspiration technique has been tried by many researchers, Santos and Leiman described it first about its advantage over the FNA technique.<sup>6</sup> This was well supported many other studies quoting that FNNAC produces less bloody and higher quality samples.

In comparing both techniques on the parameter of blood clots; FNNAC was most likely to produce the least likelihood of hemorrhage, thereby giving a clear picture to the cytopathologist. This was also observed by Ramachandra and other authors. The presence of blood cannot be totally prevented in thyroid gland cytology samples, but its effect can be minimized by the capillary action of the FNNAC technique compared to the active high suction pressure of the FNA technique.<sup>5</sup>

In this study more, number of Diagnostically Superior Samples were obtained in FNNAC 14 (19%) technique than in FNAC 10 (14%) technique. This finding was in par with other studies FNNAC 14 (20%) and FNAC 5 (7%), FNNAC 36 (28%) and FNAC 18 (14%) by Bhavneet FNNAC 77 (62%) and FNAC 42 (34%).<sup>4,7,9</sup> These results are in variance with studies by Nisha where FNAC 80 (55%) and FNNAC 20 (14%) and FNAC 15 (30%) and FNNAC 9 (18%).<sup>8,10</sup>

In this study number of Diagnostically Adequate samples were almost similar in both FNAC 48 (66.66%) and



FNNAC 47 (65.27%) where FNAC was better in 1 case than FNNAC. This finding was in par with study by Ramachandra where FNAC 47(68%) and FNNAC 47 (68%).<sup>4</sup>

The studies where FNAC is better than FNNAC are those where FNAC 95 (74%) and FNNAC 78 (61%) and where FNAC 69 (55%) and FNNAC 42 (34%).<sup>7,9</sup> The studies where FNNAC is better than FNAC are those conducted where FNNAC 108 (75%) and FNAC 46 (32%) and other studies where FNNAC 35 (70%) and FNAC 32 (64%).<sup>8,10</sup>

In this study number of Diagnostically Inadequate Samples were less in FNNAC 11 (15%) than FNAC 14 (19%). Hence FNNAC is a better technique than FNAC as FNNAC has produced less number of inadequate samples than FNAC. This finding is in par with other studies where FNNAC 8 (12%) and FNAC 17 (25%), FNNAC 16 (11%) and FNAC 18 (13%), FNNAC 15 (11.6%) and FNAC 16 (12%), FNNAC 6 (5%) and FNAC 14 (11%).<sup>4,6-9</sup> This study was in variance with the study where FNNAC 6 (12%) produced more number of inadequate samples than FNAC 3 (6%).<sup>10</sup>

In this study, out of total number of 72 cases of Solitary thyroid nodule 58 were benign and 14 were malignant. In this study incidence benign cases were more than the incidence of malignant cases. This also correlates with the study where all these studies were also having more number of benign cases than malignant cases.<sup>4,6,7,9,10</sup> In this study FNAC identified 50 correct cases out of 72 and FNNAC identified 53 correct cases out of 72 which were correlated HPE.

In this study and from the above inferences FNNAC is better than FNAC in the cytodiagnosis of Solitary Thyroid Nodule. This study is in par with studies.<sup>4-7</sup> This study is in variance with the study where FNAC is better than FNNAC.<sup>10</sup> The study showed that the results of FNAC were similar with that of FNNAC.<sup>9,10</sup>

## CONCLUSION

Solitary Thyroid nodule is a common clinical entity seen more commonly in females than in males. There is a definite risk of solitary thyroid nodule of being malignant. This study shows an incidence rate of 19% of malignancy in solitary thyroid nodules, indicating that all cases of solitary thyroid nodules should be considered as important clinical entity and should be evaluated properly in order to rule out malignancy. Hemithyroidectomy is the most appropriate and least extensive surgery for treatment and further evaluation of solitary nodule of thyroid which can be done with least post-operative morbidity.

Those cases which were given benign by FNAC/FNNAC and hemithyroidectomy done and if the histopathology reveals malignancy, re-operation should be considered to do a total thyroidectomy. FNNAC is a simple, easy to

perform, and produces better results in the form of better quality of cellularity and less field obscuration by blood in lesions of the thyroid than FNAC.

Non-aspiration technique is less traumatic, allows a more sensitive fingertip feeling of lesion and improves the precision in the sampling of lesions. Hence FNNAC is a better technique than FNAC and should be used alone or in tandem with FNAC for better diagnostic yield.

*Funding: No funding sources*

*Conflict of interest: None declared*

*Ethical approval: The study was approved by the Institutional Ethics Committee*

## REFERENCES

1. Williams NS, Christopher JK, O'Connell BPR. The Thyroid and Parathyroid Glands, chapter 51, Bailey and Love's Short Practice of Surgery. 26<sup>th</sup> Edition. 2012;741-787.
2. Townsend CM, Beauchamp RD, Evers BM, Mattox K. Thyroid, Chapter 36, Sabiston Textbook of Surgery, 20<sup>th</sup> Edition; 2017:881-922.
3. Brunicaudi CF, Anderson DK, Billiar TR, Dunn DL, Hunter JG, Matthews JB, et al. Thyroid, Chapter 38, Schwartz's Principles of Surgery, 10<sup>th</sup> Edition; 2015:1521-1556.
4. Ramachandra L, Kudwa R, Rao ABH, Agarwal S. A Comparative Study of Fine Needle Aspiration Cytology (FNAC) and Fine Needle Non-aspiration Cytology (FNNAC) Technique in Lesions of Thyroid Gland. Indian J Surg July-August 2011;73(4):287-90.
5. Nyonyintono J, Fualal J, Wamala D, Galukande M. Comparing Aspiration and Non-aspiration Fine Needle Techniques in Cytodiagnosis of Thyroid Nodules. East and Central African Journal of Surgery. July-August 2011;16(2):46-54.
6. Krishnappa P, Ramakrishnappa S. Cytological evaluation of Thyroid lesions by Fine needle aspiration vs Non-aspiration techniques-a comparative study. Int J Cur Res Rev. May 2014;6(09):115-7.
7. Sinha RK, Kumar SK, Kumar M. A Comparative Study of Aspiration vs Non-aspiration Technique in Fine Needle Cytology of Thyroid. IOSR Journal of Dental and Medical Sciences. May 2017;16(5):106-11.
8. Malik NP, Jain M, Sharma VKC, Verma N, Singh A, Singh G. Comparison of aspiration versus non-aspiration technique of cytodiagnosis in thyroid lesions. Indian Academy of Clinical Medicine Jan - Mar 2013;14(1):20-2.
9. Kour B, Singh P, Singh G. Comparison of Fine Needle Aspiration versus Non-Aspiration Cytology in Diagnosis of Non-Neoplastic Thyroid Lesions. J of Medical Research and Clinical Science. Jul 2017;5 (7):25262-7.

10. Tauro LF, Lobo GJ, Fernandes H, A comparative Study on Fine Needle Aspiration Cytology versus Fine Needle Capillary Cytology in Thyroid Nodules, Oman Med J. 2012Jul;27(2):151-6.

**Cite this article as:** Kumar HC, Kumar YC. Comparative study of aspiration versus non-aspiration fine needle technique in thyroid nodule and its correlation with post-operative histopathological examination. Int Surg J 2018;5:1046-51.