

Original Research Article

An institutional comparative study of self-gripping progrid mesh with prolene mesh in repair of inguinal hernia: a single center study

Rashmiranjan Sahoo, Debasish Samal*, Md. Omar Abdullah

Department of Surgery, Institute of Medical Sciences and Sum Hospital, Siksha 'O' Anusandhan University, Kalinga Nagar, Bhubaneswar, Odisha, India

Received: 02 January 2018

Accepted: 10 January 2018

*Correspondence:

Dr. Debasish Samal,

E-mail: dr.dsamalindia@gmail.com

Copyright: © the author(s), publisher and licensee Medip Academy. This is an open-access article distributed under the terms of the Creative Commons Attribution Non-Commercial License, which permits unrestricted non-commercial use, distribution, and reproduction in any medium, provided the original work is properly cited.

ABSTRACT

Background: The type of inguinal hernia repair used depends on many factors predominantly surgeon's training, interpretation of the literature and personal preference. This prospective cohort study describes a consecutive series of open mesh inguinal hernia repairs (modified Lichtenstein technique) performed in this hospital with two different mesh types.

Methods: Analysis was undertaken on 60 consecutive patients who underwent inguinal hernia repair during last one year. Short-term outcomes were compared between those repaired with conventional polypropylene mesh and those with Covidien Progrid mesh.

Results: All patients were male, and the mean age was 60 years. The median operative time was 60 minutes for unilateral hernias and 90 minutes for bilateral hernias. The use of Covidien Progrid mesh reduced the operative time to 40 minutes for unilateral hernias and 60 minutes for bilateral hernias. After unilateral hernia repair, 10% of the patients repaired with Progrid mesh were discharged home within 1 day of operation. Almost 99% of Progrid repair cases were discharged within 48 hrs. Twenty-four hours postoperatively, 74% of the patients were either totally pain free or had minimal discomfort. At 4 weeks, 99% of the patients were either pain free or had minimal discomfort. Patients who underwent unilateral inguinal hernia repair with progrid mesh had the most rapid return to normal activities. All these parameters are slight longer in polypropylene mesh repair cases.

Conclusions: Open anterior mesh repair is safe and results in minimal postoperative pain and early return to normal activities. Progrid mesh resulted in a shorter operative time and more rapid return to normal activities and decrease in long term postoperative pain compared with polypropylene mesh.

Keywords: Inguinal hernia, Progrid mesh, Prolene mesh

INTRODUCTION

Inguinal hernia regardless of type is one of the most common diseases that surgeon has to manage. Improved surgical techniques and a better understanding of the anatomy and physiology of the inguinal canal have significantly improved outcomes for many patients. Inguinal hernia repair has been evolving for the past centuries and the pace of evolution accelerated in the last

decade with the introduction of the tension-free repair, the laparoscopic repair and with organizing the specialized hernia clinics. Traditional suture repair of inguinal hernia is fast giving way to routine tension free mesh repair. This operation is called a "hernioplasty". In many countries, mesh repair is now more common than suture repair. Lichtenstein presented his open mesh repair technique for inguinal hernia in 1986. The Lichtenstein technique has since become the most frequently used

one.^{1,2} The repair of an inguinal hernia is one of the most common operations performed in general surgery with significant costs to health care and society. Rate of repair is increasing annually and has a potential to double in the near future. Since its introduction, the Lichtenstein mesh repair has been the most widely performed in groin hernia repair and is used as the gold standard to which other techniques are compared. The Lichtenstein technique performed and refined over several decades, revolutionized hernia surgery as a result of its reduced risk for morbidity and its potential use in patients previously unsuitable for this type of procedure. Surgeons quickly popularized this technique of tension-free mesh hernia repair, and it became the gold standard for the treatment of inguinal hernias. Since the introduction of Lichtenstein mesh repair, overall hernia recurrence rates have fallen to 2% or less. But now the common postoperative problem was chronic pain which is mainly due to the fixation techniques for which, many modifications had been done to deal it. Modifications started from the nonabsorbable sutures to absorbable sutures, Glue and now self-fixating systems.³

Self-gripping mesh

In 2008, Covidien launched ProGrip™ mesh (Figure 1), a self-gripping mesh indicated for the use in inguinal and incisional hernia repairs. ProGrip™ is designed to offer patients greater comfort following surgery, and allow physicians the ability to position and secure the mesh in less than 60 seconds, which may contribute to the reduction of operation time.⁴ The macroporous polyester mesh has resorbable polylactic acid (PLA) micro-grips on one side of the mesh, which secure quickly without sutures, tacks, fibrin glue, or any other form of fixation.³

METHODS

The study was performed in this hospital within one year. Data were collected prospectively and were analysed for 60 male patients with inguinal hernias. All patients included underwent open surgical repair for inguinal hernia by prolene mesh and ProGrip mesh. Sixty patients were operated; 30 were treated with Lichtenstein repair with prolene mesh (L group) and 30 with ProGrip mesh without fixation (P group). Patients were consecutively included in the protocol. Exclusion criteria were laparoscopic hernia repair and recurrent inguinal hernias.

Patient data

Sixty patients were randomly included in the study. Data collection was used as standardized clinical report forms. Preoperative information of patients was obtained: hernia type, previous treatment, preoperative pain measured via visual analogue scale (VAS) graduated from 0 to 10. Preoperative data was collected: type of hernia, operative time, perioperative complications. Early and late postoperative complications were recorded. Postoperative pain was assessed by VAS. Clinical follow up was

performed postoperatively at first, second, seven days and one month; complications, pain in VAS and any short-term recurrences were carefully collected.

Surgical technique

The Lichtenstein operation was performed as described by Amid et al, using 2-0 polypropylene (Prolene) to secure the mesh.² A 7×11cm polypropylene mesh (that was trimmed to match the size of the inguinal floor if necessary) was used. After closure of the external oblique and Scarpa's fascia, the skin was closed with an interrupted 2-0 polyamide (Figure 1). The surgical technique recommended for parietex ProGrip Covidien mesh was as follows: After a 6 to 9 cm skin incision, the external oblique aponeurosis was incised. The spermatic cord is carefully dissected. The inguinal ligament was dissected from the pubis up to the anterior superior iliac spine. A wide dissection of the conjoint tendon and the rectus muscle aponeurosis (Figure 1) was performed up to the linea alba as to create the space required to spread out the mesh. The mesh was then opened from its packing and any folding of the mesh (Figure 1) should be avoided. The self-gripping flaps of meshes were then opened and closed around the cord outside the operating area in order to avoid any untimely side by side placement. The mesh was then spread down carefully to its final position (Figure 1), its fixation starting inferiorly to conjoint tendon and high towards the internal oblique muscle and aponeurosis and to the adjacent inguinal ligament. No additional fixation suture was required.

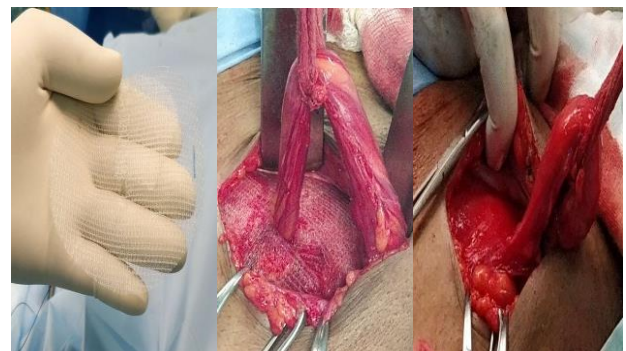


Figure 1: Surgical technique.

RESULTS

Sixty patients were followed-up for three months. Mean operative time was significantly shorter in the ProGrip mesh group at 40±10 compared to 60±10 in the Lichtenstein group. In demographic status there were no perioperative complications and no conversions to another method in any group. There are 2 types of hernia direct and indirect. In total 25, unilateral and 5 bilateral in progrip group (P), as well as 22 unilateral and 8 bilateral prolene group (L) were recorded. Moreover, 29 primary and 1 recurrent in P group and 25 primary and 5 recurrent in L group (Table 1). The VAS score was lower in the P group patients than the L group patients after 7 days and

4 weeks. There were no major complications. There were no significant differences between the groups. Return to daily routine activity was statistically significant between two groups (Table 2). Postoperative pain and requirement of analgesia is significantly lower in P group (Figure 2,3).

Table 1: Demographic status.

Demographic status	ProGrip (P group)	Prolene mesh (L group)
Age in years range		
50-80	21	20
20-50	8	10
Type of hernia		
Indirect	20	18
Direct	10	12
Unilateral	25	22
bilateral	5	8
Primary	29	25
recurrent	1	5

Table 2: Comparative outcome.

Operative details	ProGrip	Prolene mesh
Operative time		
Unilateral	30±10 min	60±10 min
bilateral	50±10 min	90±10 min
Length of stay		
Day 2	26	3
More than 2 days	1	27
Return to normal activity		
Unilateral	2day	7day
bilateral	4day	10day

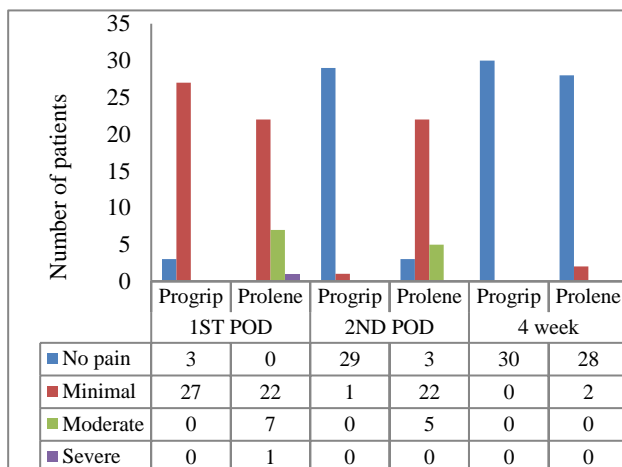


Figure 2: Visual analogue scale.

DISCUSSION

In this study results suggest that inguinal hernia repair with the Lichtenstein approach using self-gripping meshes is a safe and efficient procedure.^{4,5} The suture less ProGrip mesh is a revolutionary mesh as it can be

secured without a suture, avoiding any risk for nerve entrapment, and preserving anatomical structures.^{6,7}

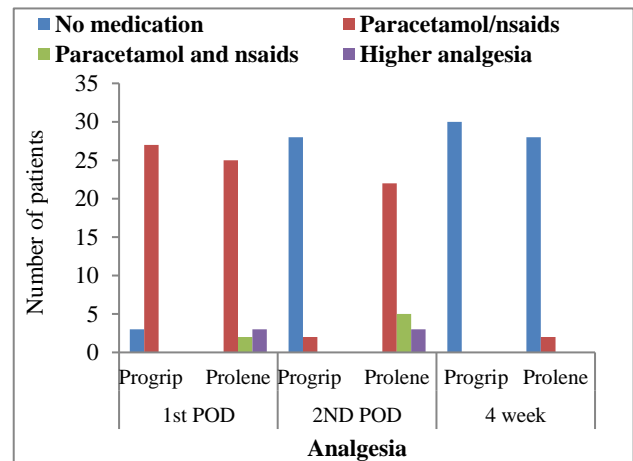


Figure 3: Requirement of analgesia.

Moreover, the resorbable PLA micro-grips of the ProGrip mesh are substantially blunt to prevent damage to the surrounding tissues. A study examined the impact of ProGrip mesh on fertility in rat models and found that self-gripping mesh posed no harm to the ductus deferens.⁸ Given the larger dimensions of the human ductus deferens, there is little or no risk for a detrimental effect on fertility by application of a proGrip mesh on exposed tissue. The operative duration is significantly shorter in this study and similar conclusion drawn by Zhang et al and Fang et al.^{9,10} Significant reduction of early postoperative pain which helped the patient for early return to day to day activities in this study is also comparable to the earlier studies.^{7,11,12} Another study Fan et al, there is no recurrence with comparison to present study in P group.¹³

CONCLUSION

Duration of surgery, early postoperative pain and infection rates were significantly reduced with self-gripping polyester mesh compared to Lichtenstein repair with polypropylene mesh. There is early return to day to day activity with self-gripping mesh. The use of fixation increased postoperative pain in the L group. The absence of early recurrence highlights the gripping efficiency effect.

ACKNOWLEDGEMENTS

Authors would like to thanks Prof. Dr. R. N. Padhy (Central Research Laboratory) for approving the manuscript and thanks to S. N. Rath for data acquisition.

Funding: No funding sources

Conflict of interest: None declared

Ethical approval: The study was approved by the Institutional Ethics Committee

REFERENCES

1. Lichtenstein IL, Shulman AG, Amid PK, Montllor MM. The tension-free hernioplasty. *Am J Surg.* 1989;157:188.
2. Amid PK, Shulman AG, Lichtenstein IL. Critical scrutiny of the open "tension-free" hernioplasty. *Am J Surg.* 1993;165(3):369-71.
3. Campanelli G, Pascual MH, Hoferlin A, Rosenberg J, Champault G, Kingsnorth A, et al. Randomized, controlled, blinded trial of Tisseel/Tissucol for mesh fixation in patients undergoing Lichtenstein technique for primary inguinal hernia repair: results of the TIMELI trial. *Ann Surg.* 2012;255(4):650-7.
4. Kapischke M, Schulze H, Caliebe A. Self-fixating mesh for the Lichtenstein procedure: a present study. *Langenbecks Arch. Surg.* 2010;395:317.
5. Kolbe T, Hollinsky C, Walter I, Joachim A, Rulicke T. Influence of a new self-gripping hernia mesh on male fertility in a rat model. *Surg Endosc.* 2010;24:455.
6. Yilmaz A, Yener O, Kaynak B, Yiğitbaşı R, Demir M, Burcu B, et al. Self-gripping Covidien™ ProGrip™ mesh versus polypropylene mesh in open inguinal hernia repair: multicenter short term results. *Prague Med Rep.* 2013;114(4):231.
7. Chastan P. Tension-free open inguinal hernia repair using an innovative self-gripping semi-resorbable mesh. *J Minim Access Surg.* 2006;2:139.
8. Zhang C, Li F, Zhang H, Zhong W, Shi D, Zhao Y. Self-gripping versus sutured mesh for inguinal hernia repair: a systematic review and meta-analysis of current literature. *J Surg Res.* 2013;185(2):653-60.
9. Fang Z, Zhou J, Ren F, Liu D. Self-gripping mesh versus sutured mesh in open inguinal hernia repair: system review and meta-analysis. *Am J Surg.* 2014;207(5):773-81.
10. Smeds S, Nienhuijs S, Kullman E, Sanders DL, Lehnert T, Ziprin P, et al. Identification and management of the ilio-inguinal and ilio-hypogastric nerves in open inguinal hernia repair: benefits of self-gripping mesh. *Hernia.* 2016;20(1):33-41.
11. Verhagen T, Zwaans WA, Loos MJ, Charbon JA, Scheltinga MR, Roumen RM. Randomized clinical trial comparing self-gripping mesh with a standard polypropylene mesh for open inguinal hernia repair. *Br J Surg.* 2016;103(7):812-8.
12. Fan J, Yip DC, Foo O, Lo SH, Law WL. Randomized trial comparing self-gripping semi reabsorbable mesh (PROGRIP) with polypropylene mesh in open inguinal hernioplasty: the 6 years result. *Hernia.* 2017;21(1):9-16.
13. Kingsnorth A, Gingell-Littlejohn M, Nienhuijs S. Randomized controlled multicenter international clinical trial of self-gripping Parietex ProGrip polyester mesh versus lightweight polypropylene mesh in open inguinal hernia repair: interim results at 3 months. *Hernia.* 2012;16:287.

Cite this article as: Sahoo R, Samal D, Abdullah MO. An institutional comparative study of self-gripping progrid mesh with prolene mesh in repair of inguinal hernia: a single center study. *Int Surg J* 2018;5:456-9.