

Case Report

Huge carbuncle of the neck with intracranial extension: a case report

Alaa Sedik^{1*}, Muhammad Y. Rauf², Mahmood Makhdoom¹, Ihab Abdo¹, Abdelhamid Harga¹,
Amir Suliman², Abrar Hussein¹, Hamza Ali¹, Rasheed Altwiher¹, Abdullah Alrashidi¹,
Wael Alanazi¹, Salwa Elhoushy³, Alaa Osman⁴, Mohamed Mostafa⁵

¹Department of General Surgery, ²Department of Neurosurgery, ³Department of Internal Medical, ⁴Department of Radiology, ⁵Department of Anesthesia, King Khalid Hospital Hail, KSA, Saudi Arabia

Received: 29 December 2017

Accepted: 30 January 2018

*Correspondence:

Dr. Alaa Sedik,

E-mail: asedik59@yahoo.com

Copyright: © the author(s), publisher and licensee Medip Academy. This is an open-access article distributed under the terms of the Creative Commons Attribution Non-Commercial License, which permits unrestricted non-commercial use, distribution, and reproduction in any medium, provided the original work is properly cited.

ABSTRACT

A carbuncle is a coalescence of several inflamed follicles into a single inflammatory mass with purulent drainage from multiple sinuses. They can develop in healthy individuals with no predisposing conditions or in immune-compromised ones. Author are presenting a case report of 57 years old Saudi presented with neglected huge carbuncle of the neck that was found complicated with intracranial extension in the posterior cranial fossa. He underwent successful simultaneous excision of the carbuncle and debridement of gross necrotic tissues; together with evacuation of the intracranial abscess. Both general and neurosurgical teams were involved. Patient made uneventful recovery and discharged home in good condition.

Keywords: Abscess, Carbuncle, Intracranial, Neck

INTRODUCTION

A carbuncle is a coalescence of several inflamed follicles into a single inflammatory mass with purulent drainage from multiple follicles.¹ Carbuncles can develop in healthy individuals with no predisposing conditions or in those immune-compromised. They mostly attributed to *S. aureus* monoinfection.²⁻⁴ They affects the hairy areas commonly the nape of the neck and back but rarely affects the face, axillae and buttocks.⁵ They need aggressive treatment debridement of the necrotic tissues leaving a large area of soft tissue defect not amenable to direct skin closure and may need a plastic coverage.⁶

CASE REPORT

A 56 years old Saudi male, known to have a long history of psychiatric illness, type 2 diabetes mellitus and

hypertension on medications was brought to emergency department with his brother as he is single and living alone. He was complaining of a huge painful neck swelling of 28 days duration that started over the back of neck and increased gradually with time associated with fever and headache.

He didn't seek medical advice before. He denied any history of vomiting, change of consciousness, visual changes or dyspnea. Clinically, general average weight male in severe pain, conscious with BP (90/60mmHg), Pulse (110/min), temp (38.4°C), O₂ saturation (93% on O₂ mask 5L/min). There was no dyspnea, stridor or cyanosis.

A huge neck carbuncle of the nape of neck, left lateral aspect of the neck reaching almost to the midline

anteriorly and down to the upper posterior back and shoulder.

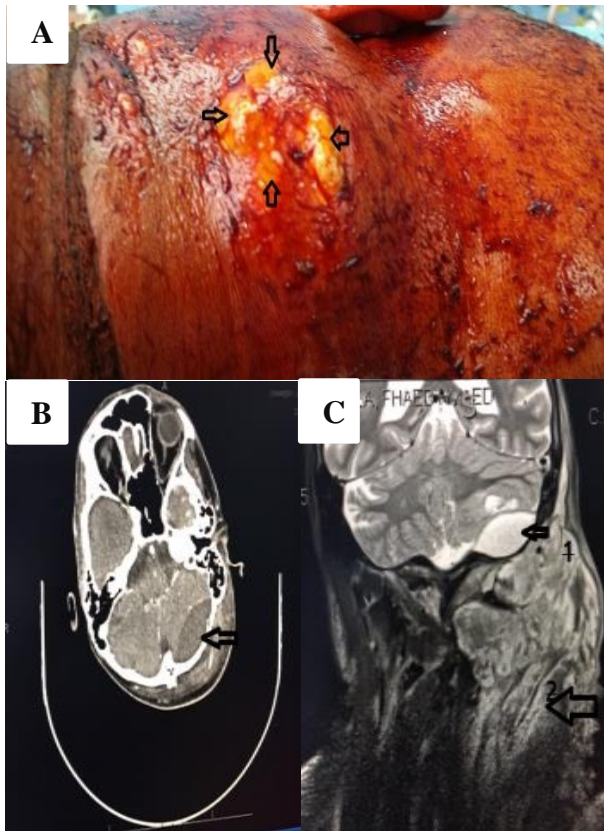


Figure 1: (A) preoperative photo showing multiple sinuses (arrows), (B) showed intracranial epidural abscess (arrow 1) and extensive left neck inflammatory swelling and collection, extending down to thoracic outlet, with tracheal deviation (arrow 2), (C) showed left epidural abscess (arrow).

The swelling was very tender, tense, with hotness and redness of the covering skin that showed areas of gangrene with some sinuses discharging pus (Figure 1A).

He was resuscitated with IV fluids, O₂, samples were taken for blood works that showed WBC (27000), Hb (9.8gm/dl), random blood sugar was 18, creatinine (130micromol/l) and urea (8mmole/l). PT, PTT, INR were 15 sec, 46 sec, 1.9 respectively, serum calcium (1.9mmol/l) and albumen (25gm/l). An impression of neglected carbuncle of neck was made and patient was prepared for contrast enhanced computerized scan (CECT) of head, neck, and chest (Figure 1B, 1C). Author were surprised that there was a huge neck carbuncle looks like a bag of pus; with an associated intracranial extradural extension to the left posterior cranial fossa, mostly through the foramen magnum. Skull bones were normal, including the left mastoid process. Moreover, the neck collection extends down both deeply to the thoracic inlet and superficially to over the left shoulder under the skin and antro-medially to the left para-pharyngeal space. Patient was seen by medical, endocrinologist,

nephrologist, psychiatric, neurosurgery, anesthesia and ENT; as he might need tracheostomy postoperatively. Patient was stabilized soon in high dependency unit.

The situation was discussed with his brother and he was consented for high risk to both simultaneous general surgery and neurosurgery intervention under general anesthesia.

After induction our patient was placed in the right lateral position and the General Surgery (GS) team started with excision of the necrotic skin including all sinuses, together with aggressive debridement of the necrotic tissues. A 500ml of pus was found. All pockets of pus around the shoulder, deep going to the thoracic inlet and to the left para-pharyngeal space were evacuated and washed with saline (Figure 2A).

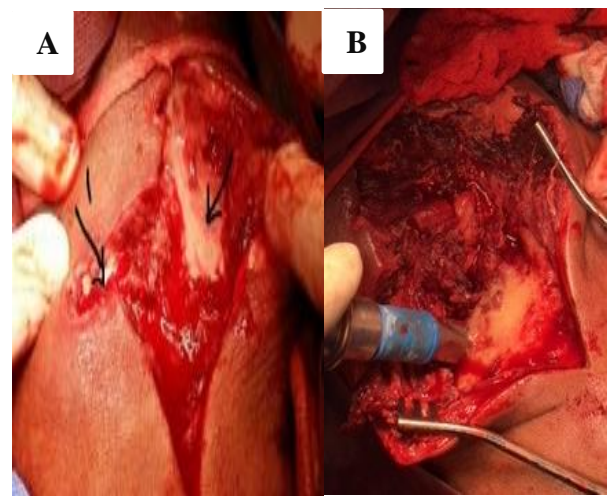


Figure 2: (A) Debridement, evacuation of pus (arrow 2), opening of all loculi with pus coming on pressure by fingers (arrow 1). (B) NS team with skull exposure after vertical skin incision extension for left sided sub-occipital craniotomy.

All areas were packed lightly with saline gauze. The neurosurgery (NS) team made a vertical upper skin incision through which left paramedian sub-occipital craniotomy and evacuation of the epidural abscess was performed (Figure 2B). The whole abscess was evacuated. The whole area was washed with saline and skin and soft tissues closed over the craniotomy. Samples of pus were taken for culture and sensitivity, and acid-fast bacilli tests. An opposite dressing was placed. Postoperatively, patient was shifted to high dependency unit under observation on IV amoxicillin and clavulanic acid. He started fluid diet and gradually to DM diet. Cultures were only positive for *Staphylococcus aureus*. He was taken to theatre on the third postoperative day (Figure 3) and wound were looking much better with some necrotic areas were found and debridement was done.

Regular daily dressing was done with saline and wet saline gauze packs. A vacuum-assisted closure device (VAC system) was applied on the 5th postoperative day. Plastic surgery consultation confirmed that no need for coverage with graft or local flaps, repeated wound cultures came to be negative. Patient has made uneventful recovery and discharged in a good condition for outpatient follow-up by general surgery, neurosurgery, plastic, endocrinology, psychiatry and medical specialties.

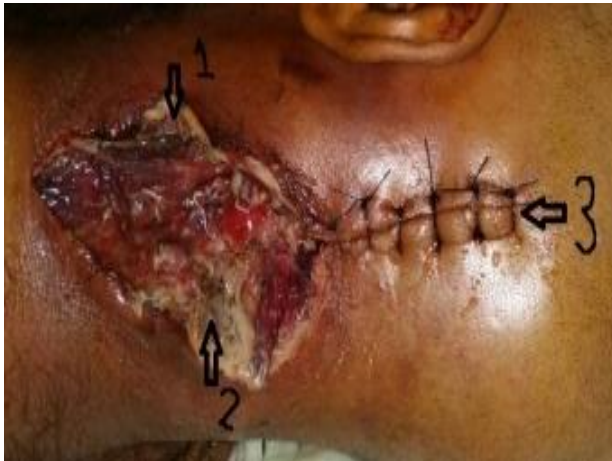

Figure 3: Second session, showing necrotic areas (arrows 1, 2) that were debrided, the incision made by neurosurgeon is shown (arrow 3).

During the course of follow up, he was symptom free and showed a small clean wound remain that was completely healed with regular local dressings with saline. Follow-up CT of head showed complete recovery (Figure 4).

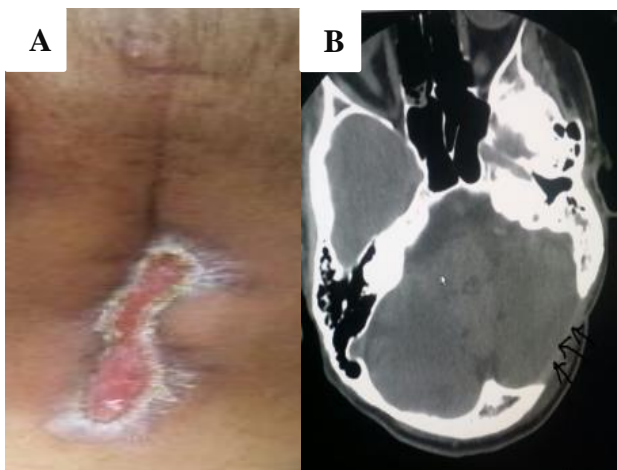


Figure 4: (A) Almost healed wound, sutures removed. (B) A plain CT of the head with complete recovery, the site of craniotomy shown also (arrows).

DISCUSSION

Carbuncle is a common dermatological disease process¹ that usually affects the nape of the neck, back, axilla, and

buttocks.¹ It is most commonly caused by *Staphylococcus aureus* that usually starts as a furuncle/ boil around the root of a hair follicle.²⁻⁵ On a literature search by the authors, carbuncles with such extensive involvement of the neck region have not been reported thus far and to the best of our knowledge this case was the first reported. Whereas poor hygiene, advanced age, an impaired immune system and delay in seeking medical advice seem to be the most important factors in such an extensive spread. The decreased pain sensation associated with uncontrolled diabetes appears to be an important factor behind this patient's late presentation.

In carbuncles of huge size of this region, the onset of severe intractable headaches should be investigated further to rule out intracranial complications, which may necessitate multidisciplinary involvement. Such complications were ruled out in this case by plain CT scan of the head ordered emergently. This approach has been followed in our case with an excellent outcome.^{7,8}

Generally, carbuncles require an early aggressive surgical approach with complete debridement of necrotic tissue should be planned in a single procedure to avoid further anesthesia in high-risk patients. While skin grafts or flaps are the recommended techniques for coverage of large carbuncle defects not amenable to direct surgical closure.^{5,6} The results of continued daily dressings and good sugar control may be quite surprising as evidenced by the remarkable wound healing that occurred in this case. An option of management that was undertaken solely on the behest of the patient's attendants. This outcome may be related to 2 factors. First, carbuncles tend to involve loose tissues of the skin, this leads to contraction of the postoperative defect becoming the predominant form of repair. The second factor relates to the type of procedure employed during surgical debridement, with the 2 recommended choices of excision of the necrotic center and surrounding cellulitis (saucerization) and incision and drainage with debridement of the necrotic center without removal of the surrounding cellulitis (which is left to respond to antibiotics). The latter approach was used in this patient not as an aim to avoid skin grafting later on, but to save as much of the skin and delicate tissues overlying the important vital vascular and nerve structures in the region, as possible. However, leaving behind the surrounding cellulitis and continuing with antibiotics leads carbuncle defects to heal quickly with skin grafting required rarely. These 2 factors in conjunction with optimum management of comorbidities probably led to the better than expected cosmetic outcome in this patient.⁹

CONCLUSION

Carbuncles in diabetic patients can result in significant morbidity like large soft tissue defects of the involved skin region that may need a plastic reconstruction or left to heal. Cooperation between the members of multi-

disciplinary team is crucial with high index of suspicion of possible complications. Proper diagnosis, preparation and management of comorbidities, surgical reconstruction if needed.

Another purpose to present this rare case to discuss the processes of wound healing that may have had an impact on this patient's remarkable cosmetic outcome despite no use of plastic surgical techniques used for skin coverage.

Funding: No funding sources

Conflict of interest: None declared

Ethical approval: Not required

REFERENCES

1. Stevens DL, Bisno AL, Chambers HF. Practice guidelines for the diagnosis and management of skin and soft-tissue infections. Clin Infect Dis. 2005;41:1373.
2. Summanen PH, Talan DA, Strong C. Bacteriology of skin and soft-tissue infections: comparison of infections in intravenous drug users and individuals with no history of intravenous drug use. Clin Infect Dis. 1995;20:S279.
3. Ruhe JJ, Smith N, Bradsher RW, Menon A. Community-onset methicillin-resistant *S. aureus* skin and soft-tissue infections: impact of antimicrobial therapy on outcome. Clin Infect Dis. 2007;44:777.
4. Moran GJ, Krishnadasan A, Gorwitz RJ. Methicillin-resistant *S. aureus* infections among patients in the emergency department. N Engl J Med. 2006;355:666.
5. Iyer SP, Kadam P, Gore MA, Subramanian P. Excision of carbuncle with primary split-thickness skin grafting as a new treatment modality. Int Wound J. 2013;10(6):697-702.
6. Mohammad JA, Al-Ajmi S, Al-Rasheed AA. Surgical management of post carbuncle soft tissue defect in diabetic patients. Middle East J Fam Med. 2007;5:4.
7. Chou PY, Chen YC, Huang P. Forehead carbuncle with intractable headache. Neuropsychiatr Dis Treat. 2015;11:793-5.
8. Chelliah G, Hamzah AA, Ahmad MZ, Ahmad RS. Carbuncle of the chin: a case report and literature review. Libyan J Surg. 2013;2:839571.
9. Benfield T, Jensen JS, Nordestgaard BG. Influence of diabetes and hyperglycemia on infectious disease hospitalization and outcome. Diabetologia. 2006.

Cite this article as: Sedik A, Rauf MY, Makhdoom M, Abdo I, Harga A, Suliman A, et al. Huge carbuncle of the neck with intracranial extension: a case report. Int Surg J 2018;5:1154-7.