International Surgery Journal
Illuri HR et al. Int Surg J. 2018 Feb;5(2):602-607
http://www.ijsurgery.com
pISSN 2349-3305 | eISSN 2349-2902

DOI: http://dx.doi.org/10.18203/2349-2902.isj20180361

Original Research Article

Hydatid disease: a 2 years retrospective study in a tertiary care center in South India

Haren Reddy Illuri, Caren D. Souza*, Erel A. I. Dias, Prashanth Philip Das

Department of Surgery, Father Muller Medical College, Mangalore, Karnataka, India

Received: 06 December 2017
Revised: 30 December 2017
Accepted: 03 January 2018

***Correspondence:**
Dr. Caren D. Souza,
E-mail: drcaren11@gmail.com

Copyright: © the author(s), publisher and licensee Medip Academy. This is an open-access article distributed under the terms of the Creative Commons Attribution Non-Commercial License, which permits unrestricted non-commercial use, distribution, and reproduction in any medium, provided the original work is properly cited.

ABSTRACT

Background: Hydatid disease (HD) is a common parasitic zoonosis and its mortality, morbidity, and socioeconomic burden makes it a significant public health problem. Though a primary disease of liver (55-70%) followed by the lung (18-35%) it is now found to affect various other organs like spleen, kidney, peritoneal cavity, skin and muscles (2%) heart, brain, vertebral column, ovaries, pancreas, gallbladder, thyroid gland, breast, and bones (1%). This study is done to describe the spectrum of presentation of hydatid disease in India. Author also discuss the rare cases of soft tissue and bone hydatid disease and peritoneal hydatid disease in this study.
Methods: It was a retrospective observational study done in a tertiary care center in India. Data was collected from patients admitted with diagnosis of hydatid disease from the patient data files and included patient profile, area of residence, occupation, history of exposure to farm animals or dogs, investigation findings and management given. Special emphasis was given to cases of extrahepatic hydatid disease and their management. The collected data was tabulated.
Results: Author found 17 cases of documented hydatid disease in the two years period. This included 11 case of hepatic hydatid disease and 6 cases of extrahepatic disease with unusual locations of bone and soft tissue, lung and parietal peritoneum. The majority of patients were in the age group of 30-50 yrs with history of exposure to sheep and farm animals. All patients received 4-6 weeks of 15mg/kg/day albendazole preoperatively. Five patients showed regression in size of the cyst and were hence continued on medical management.
Conclusions: The remaining patients underwent surgical drainage procedure. Albendazole was continued post operatively for next 6 months.

Keywords: Echinococcosis, Extrahepatic hydatid, Hydatid disease, PAIR, Scolicidal agent, Zoonosis

INTRODUCTION

Despite long standing public health measures to control spread of *Echinococcus granulosus*, hydatid cysts are still endemic in many sheep rearing areas of India. Very few retrospective studies have been undertaken to throw light on the clinical manifestations, diagnosis, treatment and outcome of hydatid cysts in India and how this scenario has changed with time and advancements in surgery. It most commonly occurs in the liver (55-70%) followed by the lung (18-35%). Incidence of HD involving the spleen, kidney, peritoneal cavity, skin and muscles is about 2% each and incidence of the heart, brain, vertebral column, ovaries, pancreas, gallbladder, thyroid gland, breast, and bones involvement is about 1% each.[1,2] This study is intended to shed light upon the various manifestations and mode of presentation of hydatid disease in India.

Aims and objectives of this study was undertaken to discuss the spectrum of presentations and management of hydatid disease hepatic and extrahepatic in India.

METHODS

Author did a retrospective observational study of two years in a tertiary care center in India from 2015-2017. Ethical committee clearance was taken from the institution ethical committee. Data was collected from patients admitted with diagnosis of hydatid disease from the HIS software and from patient data file. Data collected included patient profile, area of residence, occupation, history of exposure to farm animals or dogs, investigation findings and management given. All the cases were diagnosed based on ultrasonography and X-rays. CECT abdomen was not performed. MRI scan was performed for patient with bone involvement special emphasis was given to cases of extrahepatic hydatid disease and their management.

Inclusion criteria includes all patients with diagnosis of hydatid disease. Exclusion criteria includes patients who have refused treatment for the hydatid disease.

RESULTS

Table 1: Demographic details of patients.

Paterient demographics		
Sex	Male	8
	Female	9
Age	0-20	0
	20-50	15
	50-80	7
	>80	0
Site	Liver	11
	Lung	2
	Bone and soft tissue	1
	Extraperitoneal	3

Table 2: details of extrahepatic cases.

	Case1	Case 2	Case 3	Case 4	Case 5	Case 6
Age/sex	45/f	38/f	50/m	46/f	44/m	36/f
Site	Parietal peritoneum	Parietal peritoneum	Bone and soft tissue	Parietal peritoneum	Lung	lung
Symptoms	Pain abdomen	Pain abdomen, fever Past history of surgery for hydatid cyst	Fracture femur, limping gait, swelling in groin	asymptomatic	Cough	Cough, fever
Imaging	Multiloculated cyst in right lobe of liver with evidence of daughter cyst	Cyst in the parietal abdominal wall indenting on liver	Extensive lytic lesion of pelvic bones, femur head, shaft with fracture shaft of femur, multiple multiloculated soft tissue lesion in the periarticular region of femur and left hip	3*6cm hydatid cyst in close proximity to right lobe of liver in the right parietal peritoneum	Multiloculated cyst in right lower lobe 4*6cm with daughter cysts	Hydatid cyst multiloculated cyst right lung
Preoperativ	6 weeks of 15mg/kg/day albendazole	4 weeks of 15mg/kg/day albendazole	6 weeks of 15mg/kg/day albendazole	6 weeks of 15mg/kg/day albendazole	6 weeks of 15mg/kg/day albendazole	6 weeks of 15mg/kg/day albendazole
Intraop finding	Parietal wall hydatid extending from the right side of ABD to below the diaphragm, multiloculated, presence of daughter cysts	Parietal wall hydatid in the right parietal peritoneum	Multiloculated soft tissue hydatid in region of left groin extending to the pubic region and the perineal region.	Regressed not operated	Not operated	Not operated
Post op treatment	6 weeks of 15mg/kg/day albendazole	6 weeks of 15mg/kg/day albendazole	6 weeks of 15mg/kg/day albendazole	6 weeks of 15mg/kg/day albendazole	6 weeks of 15mg/kg/day albendazole	6 weeks of 15mg/kg/day albendazole
HPE	Endocyst, exocyst and pericyst revealed	Endocyst, exocyst and pericyst revealed	Endocyst, exocyst and pericyst revealed			
Follow up	No recurrence in 1 yr period	No recurrence in 1 yr period	Hydatid disease treated. Fracture united by malunion	No recurrence in 1 yr period	regressing	No recurrence in 1 yr period

Author found a total of 17 documented cases of hydatid disease in the two years duration. This included 9 females and 8 males. Majority of patients were in the age group of 30-50 yrs with only one lady of 78 years (Table 1).



Figure 1: Groin swelling in patient with bone and soft tissue hydatid disease.



Figure 2: Case of bone involvement in hydatid disease, pelvic x-ray, shows erosion of pelvis bone and fracture of femur.

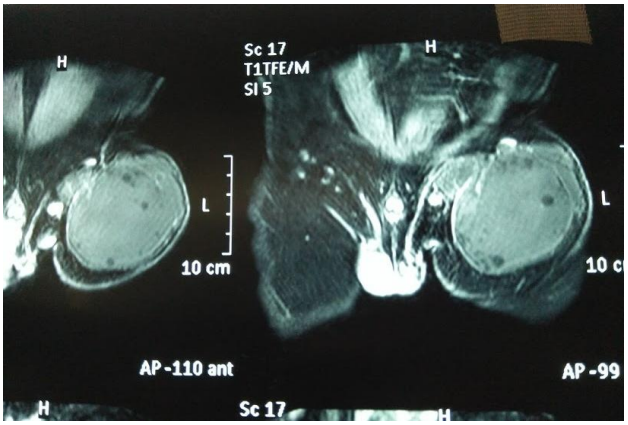

Figures 3: MRI image of bone and soft tissue hydatid.

Among these patients 13 patients gave history of contact with dogs and sheep and cattle rearing. 12 patients were from rural areas. 4 patients in the group were asymptomatic for the hydatid and were diagnosed incidentally during evaluation of other complains.

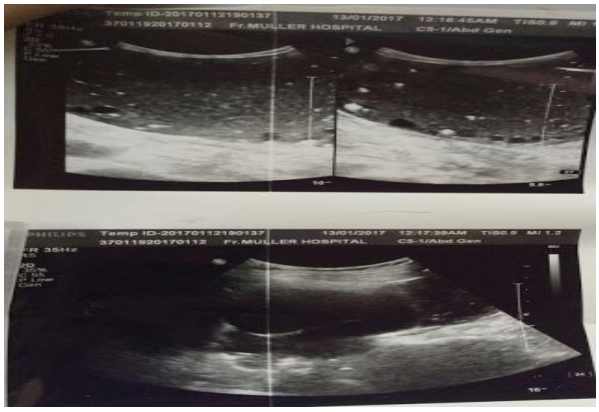

Figure 4: Ultrasonography image of hydatid cyst.



Figure 5: Intrahepatic findings of bone hydatid showing daughter cysts.



Figure 6: Injection of scolicidal into the cavity.

Out of these 11 were in the liver and six in extrahepatic locations. The extrahepatic locations included lung (2), bone (1), and parietal peritoneum (3). Among the hepatic hydatid cysts 7 involved right lobe, and 4 involved the left lobe (Table 2). Among the hepatic hydatid cyst patients there was no incidence of ascitis or jaundice noted. The main complaint was pain abdomen (9), fever (3). The patients with lung hydatid had a main complaint

of cough and chest pain. The patient with bone hydatid presented with fracture of left femur with pain in the pelvic region. The patients with involvement of parietal peritoneum were reported by usg as hepatic hydatid probably due to close proximity to right lobe and diaphragm.



Figure 7: Intrahepatic findings of parietal peritoneum hydatid.



Figure 8: Intrahepatic findings of parietal peritoneum hydatid drainage.



Figure 9: Hydatid cyst wall and scolices.

All patients received 4-6 weeks of 15mg/kg/day albendazole and were followed up by imaging studies. Five patients showed regression in size of the cyst and were hence continued on medical management. The remaining patients underwent surgical drainage procedure. Albendazole was continued post operatively for next 6 months.

Author found the parietal peritoneum hydatid cysts located between the right lobe of the liver and the right crus of the diaphragm. Out of these three patients, one had a recurrent disease being operated 5 years prior for hepatic hytadinosis.

The bone hytatid disease was found in relation to the left femur and the pelvis with erosion of the bone and multiple loculations were also seen in the subcutaneous and the intramuscular planes.

DISCUSSION

The ancient Greeks used the word “echinococcus” meaning “hedgehog berry” for hydatid cysts. Hippocrates pointed out “livers full of water” for cases of echinococcosis. The life cycle of Echinococcus granulosus was first described by Haubner.[2-4] It is an important zoonotic and parasitic infection of humans, following ingestion of tapeworm eggs excreted in the faeces of infected dogs.[3]

Echinococcosis is endemic in developing countries like South America, Middle East, Australia, India and Mediterranean countries where flocks of sheep and cattle are raised with dogs and hence more common in the rural population and with also the people involved in animal husbandry.[2,4,5] In India the highest prevalence is reported in Andhra Pradesh, Tamil Nadu, and Jammu and Kashmir[5]. Hydatid cysts can affect any organ of body except hair, teeth and fingernail. The sites of occurrence in descending order are liver (50-93%), lungs (18-35%), peritoneal cavity (10-16%), spleen (2-3%), kidney (1-4%), and retroperitoneum (0.5-1.5%).[2-4,6] After infection with *Echinococcus granulosus*, humans are usually asymptomatic for a long time. The growth of the cyst in the liver is variable, ranging from 1 mm to 5 mm in diameter per year.[3]

Author found majority of the patients were from the sheep rearing areas of Karnataka and Kerala, with history of exposure to sheep and dogs. Majority of the patients had hepatic hydatid disease with 7 out of 11 cases involving the right lobe of liver. Out of the 6 cases of extrahepatic hydatid locations included lung (2), bone (1), and parietal peritoneum (3).

Finding hydatid cyst in a striated muscle is rare, and this has been attributed to two factors - the presence of lactic acid and contraction of the muscles. However, parasitic cysts are inclined to grow in the trunk, neck, and legs because of relatively less muscle contraction and rich blood supply to these areas.[7]

Most cysts of liver are univesicular (62.5%), single and involves right lobe (80.77%) due to drainage pattern of portal vein. As the cysts enlarge local pressure causes a mass effect on surrounding tissue producing commensurate symptoms and signs like generalized upper abdominal pain and discomfort or obstructive jaundice or a picture very similar to ascending cholangitis with fever, pain and jaundice.[3]

Due to decreased resistance offered by alveolar loose tissue in lung parenchyma, cysts grow faster in lung than in liver.[2,7]

Usually parasites spread via portal blood stream. Other routes of spread may be lymphatic invasion by the parasite, and retrograde migration from the vena cava to the subclavian vein. HD can also involve any organ of abdomen due to hematogenous route or due to peritoneal fluid circulation phenomenon. The movement of the diaphragm and peristalsis of bowel regulate the movement of fluid in this circulatory pathway. It is partially cleared by the sub-phrenic lymphatics. Fluid stays in these watershed regions in the peritoneal cavity: The ileocolic region, the root of the sigmoid mesentery, and the Pouch of Douglas. The spread of HD can be along the areas of peritoneal fluid circulation and may result in spontaneous intraperitoneal seeding[5] this explains the presence of hydatid cysts in the parietal peritoneum in 3 of the patients. Though one patient gave us a past history of surgical treatment of hepatic hydatid, in other two patients it was a primary presentation.

Author also noticed that out of six cases of extrahepatic hydatid disease only one patient had past history of hepatic cyst while five patients did not. This finding is similar to study by talpur et al.[8] This probably hints to the fact that liver need not be the primary organ of involvement.

The serological tests include Casoni intradermal skin test, Weinberg complement fixation (CF) test, indirect hemagglutination (IHA) test, ELISA, and western blot (WB) with the reported sensitivity of 96.7%, 87.1%, and 100%, for IHA, ELISA, and WB, respectively.[9]

Ultrasonography (US) and CT have been reported to be the main diagnostic tools, with 85% and 100% sensitivity (Table 3).[9] CT gives valuable information regarding the size of the cyst, septations presence, the integrity of germinative membrane, status of liver parenchyma, location and the depth of the cyst and adjacency with bile ducts. They may show a “spoke wheel” pattern or a water lily sign typical eggshell- like appearance is seen in completely calcified cysts.[4,5,10]

Treatment of HD Small, calcified cysts do not require treatment but should be monitored.[1] Treatment options can be divided into chemotherapy (benzimidazolic drugs) and surgery, which consist of PAIR (Puncture, Aspiration, Injection, Respiration), PPDC (Percutaneous Puncture with Drainage and Curettage), conservative surgery (open cystectomy with or without omentoplasty), and radical surgery (total pericystectomy or partial hepatectomy). Palliative treatment consists of simple tube drainage of infected cysts or communicating cysts. Laparoscopic or open surgical drainage procedure involves: aspiration, installation of scolicidal (0.04% chlorhexidine gluconate, 20% hyperomic saline, 0.5% silver nitrate, 10% povidone-iodine, and 2% formalin[9]), deroofing, removal of all contents and converting the cyst into a big size non-dependant cavity.

However, pre- and post-operative 1-month courses of albendazole and 2 weeks of praziquantel should be considered in order to sterilize the cyst, to decrease the chance of anaphylaxis, to decrease the tension in the cyst wall and to reduce the recurrence rate post-operatively.[5,11.]

Albendazole inhibits tubulin, induces blockage of glucose absorption, and produces glycogen depletion and degenerative alterations in the endoplasmic reticulum and mitochondria of the germinal layer, thereby increasing lysosomes and producing cellular autolysis. In the case of alternative medical therapy using chemotherapy alone, albendazole is used with an adult dosage of 400mg orally, twice a day for 1-5 months and a pediatric dosage of 15 mg/kg/day (maximum of 800mg) for 1-6 months.[1,4,5,10,11]

Study by Gourgiotis S and collegues on 169 patients of hydatid cysts in a 12 years period showed that surgical procedures combined with antiscolicidal agents like albendazole were more effective in treatment of hepatic hydatid cysts.[11]

Even though, mortality directly due to echinococcosis is very low, it can produce a very disabling morbidity and mortality rate between 0.29% and 0.6%.[5] Overall, the reported recurrence rates of hydatid cyst in the literature vary from 6.6% to 22%.[9,5]

The main differential diagnosis of hydatid disease is simple cysts, cysticmetastasis, pancreatic pseudocysts, and cystic teratoma; in the case of complicated or calcified cysts (type III or IV), the differentials are abdominal abscesses, tuberculosis, and hepatocellular carcinoma.[1]

CONCLUSION

A sound knowledge of various modes of presentation of hydatid disease, combined with clinical judgment, high suspicion in endemic areas and confirmation by newer diagnostic modalities like USG and CT is required for early diagnosis and treatment and prevent complications.

Funding: No funding sources
Conflict of interest: None declared
Ethical approval: The study was approved by the Institutional Ethics Committee

REFERENCES

1. Leitão P, Carvalho A, Fernandes T, Gonçalves J. Cystic Echinococcosis: A Case of Extrahepatic Intra-Abdominal Involvement. Case reports in radiology. 2017 Jan 17;2017.
2. Kamble MA, Thawait AP, Kamble AT. Hydatid cyst in the past and the present. Journal of Evolution of Medical and Dental Sciences. 2014;3(18):4886-902.
3. Venukumar R. Clinical presentation of hydatid cyst of liver: descriptive study. Int Surg J. 2017; 4(1):214-6.
4. Duman K, Girgin M, Hamcan S. Uncomplicated Hydatid Cysts of the Liver: Clinical Presentation, Diagnosis and Treatment. J Gastrointest Dig Syst. 2016;6(430):2.
5. Sachar S, Goyal S, Sangwan S. Uncommon locations and presentations of hydatid cyst. Ann Med Health Sci Res. 2014;4(3):447-52.
6. Gole S, Gole G, Satyanarayana V. Unusual presentation of hydatid cyst: A case series with review of literature. The Internet Journal of Parasitic Diseases. 2013;6(1).
7. Kullolli GK, Vaidya MK, Patil R. Unusual Presentations of Hydatid Cyst-A Case Study. International Journal of Scientific Study. 2017 Apr 1;5(1):218-22.
8. Talpur AA, Shaikh AA, Arain MI, Siddiqui AJ. Experience with Extra Hepatic Intra Abdominal Hydatid Cyst. Journal of Nepal Medical Association. 2016 Oct 7;53(200):270-4.
9. Alzobydi AH, Guray SY, Guraya SS. Primary extrahepatic hydatid cyst of the soft tissue: a case report. 2012.
10. Mohan SV, Shashidhara TM, Kumar BS. Hydatid cyst-surgical management. Journal of Evolution of Medical and Dental Sciences. 2013;2(31):5903-9.
11. Gourgiotis S, Stratopoulos C, Moustafellos P, Dimopoulos N, Papaxoinis G, Vougas V, et al. Surgical techniques and treatment for hepatic hydatid cysts. Surgery Today. 2007;37(5):389-95.

Cite this article as: Illuri HR, Souza CD, Dias EAI, Das PP. Hydatid disease: a 2 years retrospective study in a tertiary care center in South India. Int Surg J 2018;5:602-7.