

Case Report

Pectus excavatum-insights into its diagnosis and the current treatment options along with its clinical outcomes: two case reports

Chukwuemeka D. Iroegbu*, Zhou Zhongxin, Tan Sheng, B. O. Jiang, Liu Jingsong

Department of Thoracic and Cardiovascular Surgery, Affiliated Hospital of Xuzhou Medical University, Xuzhou, Jiangsu Province, China

Received: 28 November 2017

Revised: 30 December 2017

Accepted: 03 January 2018

*Correspondence:

Dr. Chukwuemeka D. Iroegbu,

E-mail: Dr.iroegbu_daniel@yahoo.com

Copyright: © the author(s), publisher and licensee Medip Academy. This is an open-access article distributed under the terms of the Creative Commons Attribution Non-Commercial License, which permits unrestricted non-commercial use, distribution, and reproduction in any medium, provided the original work is properly cited.

ABSTRACT

Pectus excavatum (PE) is a congenital sternal depression, one of the most frequent major congenital malformations of the chest wall. Generally, the malformation is not associated with functional disorders and often constitutes an aesthetic alteration with significant psychological distress. Nevertheless, the surgical repair of PE in childhood has been a well-established procedure with modified Ravitch repair (MRR) and minimally invasive repair (MIR) by Nuss been the two most popular methods of corrections. As a means of concealing the ugly skin scars caused by the MRR technique, the procedure was however highly modified with the use of bilateral inframammary separated skin incisions. However, MIR has been a preferable technique due to its shorter operative time and minimal blood loss, but its postoperative complications have so far seemed to be its limiting factor whereas, extensive and combined deformities of the ventral chest wall are classically corrected using either MIR by Nuss and the MRR technique. Notwithstanding, Conservative treatment using alloplastic implants or vacuum bell to elevate the sternum in patients with mild PE defect is becoming a potential alternative and a means of preventing unnecessary surgical procedures mostly in mild funnel chest. Presented here is a case of PE surgical correction in a 12-year-old boy and an 11-year-old girl with pectus bar dislodgment. This article analyses the chain of events between both patients, reviews the literature on the subject and other currently available treatment options.

Keywords: Nuss procedure, Pectus excavatum, Ravitch procedure, Silicon implants, Vacuum bell

INTRODUCTION

PE is the most common congenital chest deformity characterized by a depression in the anterior chest wall due to the dorsal deviation of the sternum and the third to seventh rib or costal cartilage involvement, with PE affecting about one to eight per 1000 live births.^{1,2} PE frequently affects males more than females in a ratio of 5:1.¹⁻¹² However, the depression on the sternum can displace the heart; cause a decrease in the right ventricular functions of the heart and also a decrease in

pulmonary functions too due to the decrease in thoracic volume.^{2,3} Nevertheless, PE cases have mostly been a cosmetic defect including issues regarding body image which may significantly impact a person's quality of life, low self-esteem, and increased psychosocial problems with PE patients mostly complaining of chest pain, difficulty breathing, decreased cardiac output and decreased exercise capacity depending on its severity.^{4-6,13-17} Morphological differences in pectus excavatum may result in different effects on pulmonary function as well as cardiac morphology and function.^{5,6} Symptoms of

untreated patients can progress with age, and it's recommended that the deformity is surgically treated in both young and adult patients.² In light of this, a number of clinical studies have shown improvement of pulmonary and/or cardiovascular symptoms and patient quality of life after surgical repair.⁷ The defect primarily affects the 3rd to the 8th costal cartilages that cave in the body of the sternum, reducing the distance between the vertebrae and sternum. Furthermore, Haller's thoracic index (transverse diameter/anteroposterior diameter of the chest) defines the severity of the malformation; a value of C3.2 is considered by some authors to be pathology.^{11,12} However, Poston et al, proposed a correction of the Haller index the "correction index" which is more accurate in reflecting the severity of the pectus excavatum even in patients with nonstandard chest morphologies.¹³ Notwithstanding, various techniques have been used to correct this deformity, the most common being that developed by Ravitch.⁸ It's an open surgical procedure which involves complete resection of the cartilage, xiphoid excision, and osteotomy of the sternum when it was introduced at first.⁸ However, in

1998, a new method was introduced by Nuss et al, which was a MIR technique.⁹ Unlike the Ravitch procedure, which uses a single incision in the center of the chest, the Nuss procedure uses a small incision on the lateral side of the chest wall under the arms raising the sternum using a single or double retrosternal metallic bar which was based on the fact that the thorax of younger subjects were flexible making an effective correction possible without costal cartilage resection or sternal osteotomy, with the Nuss procedure having an advantage over the Ravitch technique such as; the reduction in blood loss, shorter operative time and less remaining scar tissue.^{2,8-10} In addition, recent studies have suggested that minimal invasive repair of PE improves the quality of life, body image, and the patient's self-esteem.^{15,16,18-20}

CASE REPORT

Case 1

Table 1: Timeline of medical history, interventions, and outcomes (case 1).

Past medical history (2011-2017)	Sever recurrent chest pain, chest tightness and difficulty breathing
Current history/ diagnosis (12 th April 2017)	Bilateral symmetrical moderate pectus excavatum
Vital signs: outpatient/pre-admission (12 th April 2017)	
Supine position	Sitting position
Heart rate: 76 beat/min	Heart rate: 86 beats/min
Blood pressure: 100/70mmHg	Blood pressure: 100/75mmHg
Vital signs: on admission/ inpatient (15 th April 2017).	
Respiratory rate:	20/min.
Temperature:	37°C
Pulse rate:	100 beats/min.
Blood pressure:	110/70mmHg.
Clinical findings (17 th April 2017)	
Radiographic study:	Posterior displacement of the lower end of the sternum with normal cardiac size and no associated scoliosis
Computer tomographic study:	Haller index 5.845
Surgical intervention (21 st April 2017)	Surgical correction of the chest deformity
Postoperative chest radiography (23 rd April 2017)	Satisfactory
Medications/ pain control (21 st April- 26 th May 2017)	
10mg of Oxycodone in the evening of the first postoperative day for a period of ten days twice daily	
1g of paracetamol for five weeks.	
400mg of ibuprofen for four weeks.	
Life style recommendations (25 th April 2017)	
Sleep on supine position and avoid sleeping on the chest and abdomen	
Avoid lifting heavy load of more than 5kg	
Avoid sporting activities and twisting of the upper body trunk.	
Follow up chest radiographic study (12 th June 2017).	Satisfactory
Life style recommendations after the initial visit to outpatient clinic	
No contact sports such as football, basketball est.	
To engage in light physical exercise such as jogging and cycling slowly according to his pace	

Patient's information: A 12-year-old boy with his parents visited our department's pediatric cardiac and thoracic outpatient clinic at the province city hospital in the background of severe recurrent chest pain accompanied by chest tightness. The patient was tall, thin with clear consciousness denied any trauma to the chest and was also not on any medications and at the time of visit he was not in any acute distress what so ever. Patient's parents also stated that he also complained of slight difficulty in breathing in elementary school when he participates in various physical exercise classes and another day to day activities which only became intense in his 8th grade. The patient was said to have skipped physical exercise training classes few times as he complained of feeling ashamed about his physical appearance coupled with the fact that he could barely keep up with the demands of the sporting events. His parents denied any genetic or family history of any sort. At the time of examination when in the supine position, his heart rate was 76beats/min and his blood pressure was 100/70mmHg. At sitting position, heart rate was slightly increased to 82beats/min with the blood pressure at 100/75mmHg. After questioning and thorough physical examination of the patient with the obvious sunken sternum of the patient, the attending physician made a diagnosis of bilateral-symmetrical moderate PE and was admitted to the inpatient department pediatric ward wing.

Clinical findings

A chest radiographic study of both anteroposterior and lateral views was obtained, and it showed a posterior displacement at the lower end of the sternum with a normal cardiac size and no associated scoliosis. Computer tomographic result revealed patients Haller index which was at 5.845 with significant depression of the anterior chest wall at the midpoint, no rib hypoplasia nor displacement or rotation of the heart. Inpatient physical examinations were as follows; blood pressure 110/70mmHg, pulse rate -100beats/min, temperature-37°C, and respiratory rate 20/min.

Timeline

Therapeutic intervention: The deepest point of the sag on the sternum was identified first because better results are achieved when this point is lifted (Figure 1). The points in which the bar should enter and exit the chest wall where marked on the skin laterally and just medial to the highest point of the PE. A tunnel under the sternum was created with a Lorenz introducer keeping the tip of the introducer directly under the backside of the sternum avoiding injury of any sort to the pericardium and the heart. During this process, the assistant lifted the sternum with two retractors through the incisions that were prepared for the bar for easy passage of the introducer from the leading surgeon's end. The steel bar length was measured from the right midaxillary line to the left with the lateral stabilizer fixed on both sides keeping the steel bar in place and attached to the rib with the aid of a wire

steel and additional nonabsorbable sutures at the opposite ends of the bar to prevent the bar from flipping.

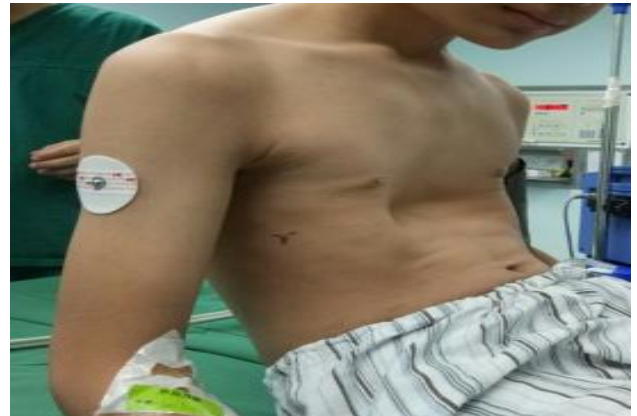

Figure 1: Patient with moderate pectus excavatum minutes before correction of the deformity.

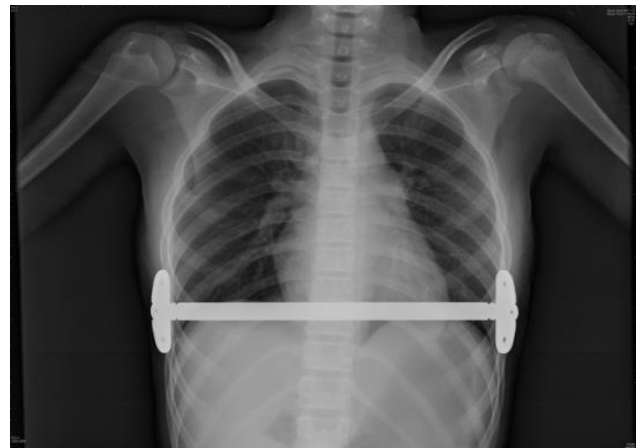


Figure 2: chest radiograph of the patient seven weeks after pectus bar removal.

Follow-up and outcomes: After surgery, the patient was immediately transferred to the postoperative anesthesia recovery unit to check if the pain management was sufficient enough before sending the patient to the intensive care unit and back to the inpatient ward with an additional oral analgesic giving in the evening of the operative day. On the first postoperative day in the ward, Oxycodone 10mg was giving twice daily spanning for a period of ten days. On the second postoperative day, an anterior-posterior chest radiograph was taken to verify if the pectus bar is in its correct position before scheduled discharge on the fourth postoperative day. He was placed on a standard regimen of paracetamol 1gm for five weeks along with 400mg of ibuprofen for four weeks and he was satisfied with the standard regimen of the postoperative pain control. The pain and surgical tolerability were great, and it was achieved by a self-made surgical and pain rating scale in our institution. He was instructed to immediately visit the hospital at any signs of discomfort or pain with the surgery.

Case 2

However, this did not occur and there were no postoperative complaints from the patient what so ever after discharge from the hospital on the fourth postoperative day. After the patient was discharged from the hospital, he was placed under various restrictions for three months such as not carrying 5kg of load or more involving the upper body trunk and avoiding sporting activities with the twisting of the upper extremities. He was also instructed not to sleep on his chest and abdomen rather in a supine position. On the seventh week after surgery, he visited the department's outpatient clinic as instructed for further routine clinical evaluation with a chest radiograph (Figure 2).

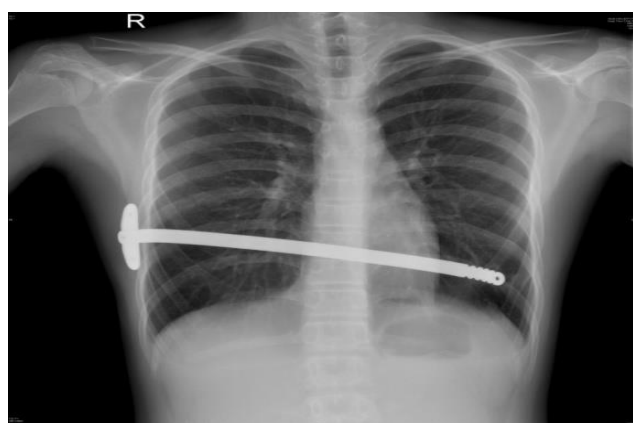

Figure 3: Chest radiograph indicating dislodgement of the supporting bar after pectus repair with slight migration towards the left hemi diaphragm.

However, after the attending physician evaluation, everything appeared in order and satisfactory and was thereafter further instructed not to engage in any physical contact sports whatsoever only to engage in light physical

and less strenuous activities like jogging slowly and riding a bicycle gradually at his own pace for the duration of eighteen months before returning for the removal of the pectus bar.

Patient's information: A 11 years old girl affected by PE with moderate to severe symmetrical deformity of the chest wall with limitations during physical activities and a Haller index of 7.231 underwent surgical correction which was performed by a board-certified thoracic surgeon using the Nuss technique who was versed and experienced with the procedure. It was carried out in a routine fashion placing the metal steel bar horizontally under the sternum with its end on the lateral sides of the chest wall fixed tight to the 7th rib with a small steel plate to the right alongside steel wires and nonabsorbable sutures. After a period of 18 months on routine plan, the patient was electively readmitted for the removal of the steel bar with no adverse symptoms on readmission. But on admission, the pre-removal chest x-ray showed a left side detachment of the metal steel bar from the side with slight dislodgment towards the left hypochondrium (Figure 3). The patient denied any form of trauma nor any other chest therapeutic interventions carried out during the past few months. Thereafter, a surgical diagnosis was made as dislodgement caused as a result of a single steel plate used.

Therapeutic intervention: A decision was made during the removal of the steel bar to create a small window with the help of an adult finocchio rib spreader on the left side for easy introduction and maneuver of surgical instruments 1cm below the anterior axillary line to the midaxillary line on the 6th intercostal space in order not to further displace the steel bar downwards intra abdominally causing fatal injuries to vessels and abdominal structures lying beneath the left hypochondrium.

Table 2: Timeline of medical history, interventions, and outcomes (case 2).

Past medical history (3 rd May 2015)	Sever recurrent chest pain, chest tightness and difficulty breathing. Bilateral symmetrical moderate to severe pectus excavatum
Current history/ diagnosis (5 th May 2017).	Surgically corrected moderate to severe congenital sternal defect [pectus excavatum type] with Nuss technique with bar dislodgement caused as a result of single steel plate used.
Clinical findings (5 th May 2017)	
Radiographic study:	Left side detachment of the metal steel bar from the side with slight dislodgment towards the left hypochondrium.
Surgical intervention (12 th May 2017).	Retraction and removal of dislodged surgically inserted pectus steel bar.
Medications/ pain control (12 th -15 th May 2017).	10mg of oxycodone at first postoperative day in divided doses. 100mg of ibuprofen for second and third postoperative day and as needed after discharge.
Postoperative chest radiography	Not carried out according to the hospital policy to minimize radiation exposure especially in pediatric patients
Life style recommendation (15 th May, 2017).	Moderate physical challenging and demanding exercise

The steel bar was retrieved and temporarily fixed to the 6th rib and the patient was returned to the routine supine position with caution. The surgery was completed in a timely fashion with the steel bar safely removed with ease alongside the steel plate and steel wires which were used to keep it from flipping during the initial procedure without any complications (Figure 4). She was discharged on the 4th postoperative day.

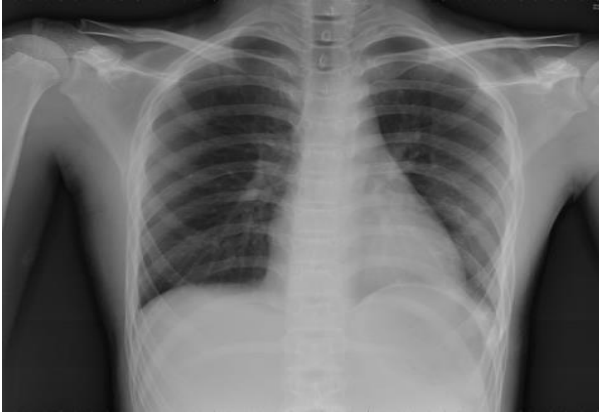

Figure 4: Chest radiograph of the patient after retrieval of the dislodged pectus bar.

DISCUSSION

PE was first described by Bauhinus, but Ebstein conducted external measurements of PE.^{21,22} He determined the depth of the malformation by calculating the diameter of the right and left thorax and the transverse diameter with his method been similar to the measurements performed today. However, both Nuss and Ravitch techniques for the repair of PE have repeatedly been in use today in its ever-increasing number still yet, data's comparing both techniques have been limited as various surgical centers routinely perform either of them as they are inexperienced to the other.²³ Despite the success rate of MIR technique in children which are richly reported in the various literature, extending this procedure to adolescents, adults, athletic persons, and asymmetric cases have remained a subject of discussion.²⁴ Recently, almost all modern techniques are based on the MRR technique, except the Nuss procedure with surgical indications for pectus repair been the cosmetic aspect of the deformity, physiological, psychological and or orthopedic postural defects, with the cosmetic aspects of utmost importance to female patients.²⁵ In addition to the cosmetic aspects of the repair, application of the MRR procedure produces better results as this technique uses inframammarian incisions thereby concealing the scars right below the breast tissue in both supine and upright positions.²⁶ Nevertheless, surgical correction of this malformation with MIR have rapidly gained acceptance over the past decade as a standard of choice for the treatment of patients with PE in an experienced pediatric and thoracic surgical center producing excellent results in both cardiopulmonary functions and quality of life.^{1,8,25} Accordingly, it's also

important to establish the impact and severity of the deformation as the surgical decision could be very challenging in these patients given the intraoperative risk with relatively variable rates of bar migration, infection, and reoperation.¹ Until recently, Surgery was the only available form of treatment using either the Nuss or the open Ravitch procedure.⁸ Various conservative treatments have been used to treat chest wall abnormalities with numerous kinds of vacuum devices of different sizes along with fitted models for women allowing selection according to an individual patient's age and size. These vacuum devices allow some patients with PE to avoid surgery, help in preparation for surgery and the device can also be useful if a surgically implantable bar has to be removed earlier than scheduled. It could also be used intraoperatively as vacuum devices are applied externally for a short period to lift the sternum away from the heart during MIR of PE to provide more working space and safely guide the bar(s) pass through the mediastinum under thoracoscopic visualization. Uniquely assumed to be effective when used as the only treatment in patients with PE, measurement of its efficiency in lifting the sternum during surgery is not known, with its known complications been petechial bleeding, hematoma and dorsalgia.²⁷ Furthermore, several synthetic, metallic and biological materials have been used to secure sternal stabilization in most PE. However, the disadvantages of these implants are excessive rigidity with the risk of erosion of adjacent vital structures which eventually lead to various catastrophic injuries, infections, immunologic reactions, migrations and lack of strength alongside the possibility of host rejection. Notwithstanding, Sternal allogeneic bone grafts have proven to be an effective and biologically well-tolerated option for sternal replacement.^{5,23,28} In addition, several reports have questioned the necessity of radiographic studies with the use of chest x-rays which are taken after instrumentation in or around the thoracic cavity which was driven by concerns for radiation exposure, particularly in the pediatric population with a retrospective study which demonstrated that the post-operative chest x-rays were unnecessary following bar placement unless respiratory symptoms were present.²⁹ Invariably also, cardiac magnetic resonance imaging is currently been the reference standard for anatomic and functional cardiac assessments as several PE defects are more than likely to impair right ventricular function.³⁰

CONCLUSION

PE is an intriguing congenital condition with a multidisciplinary approach involving cardiologists, pulmonologists, and thoracic surgeons with psychological, social and cosmetic factors been the propagating factor for most patients opting for surgical correction. An early surgical intervention at younger age around puberty is the best choice as minimal postoperative complications arise in such cases. Despite the increasing popularity of the Nuss technique, with its shorter operative time and less blood loss compared to

the Ravitch procedure, it may not be surprising that most patients would rather choose to undergo the MRR technique due to its cosmetic edge over the Nuss procedure. Hence, with such preferences in mind, it's however of utmost importance that pediatric and thoracic surgeons be vastly experienced in both procedures in the advent of such situations. In our experience, both MIR, MRR and minor open endoscopically assisted repair (MOEAR) of PE are all appropriate techniques, but the decision on which technique to apply is based on the surgeon's surgical experience and different selection criteria. In general, MIR is still used as a standard procedure for uncomplicated cases and remains an ideal therapeutic option in both childhood and adolescence with symmetric PE deformities, while MOEAR's are complementary methods with high-quality results for correction of already matured rigid skeletal structures at or beyond puberty, and for complex PE deformities. Comparatively, only the MRR had produced better results with a combined deformity of both sternal plate and the rib cage.

In light of the aforementioned methods in relation to cosmetic and shorter hospital stay, the peri-areolar technique has shown to provide excellent results with fewer complications with a growing amount of female patients preferring such procedure. In addition, patients in various surgical centers are been encouraged to try less invasive conservative treatment modalities with mild PE defects such as the vacuum bell therapy to avoid the need for surgery even though its long-term results could be far lacking as it may assist the surgeon during MRR. Ultimately, as imaging may be necessary for proper follow-up studies and further evaluations after surgery, it should be limited if possible employed at lower doses to minimize radiation exposure particularly in pediatric and young patients, because of their increased sensitivity to radiation.

Funding: No funding sources

Conflict of interest: None declared

Ethical approval: Not required

REFERENCES

- Obermeyer RJ, Goretsky MJ. Chest wall deformities in pediatric surgery. *Surg Clin North Am.* 2012;92(3):669-84.
- Brochhausen C, Turial S, Muller FK. Pectus excavatum: history, hypotheses and treatment options. *Interact Cardiovasc Thorac Surg.* 2012;14(6):801-6.
- Lawson ML, Mellins RB, Paulson JF. Increasing the severity of pectus excavatum is associated with the reduced pulmonary function. *J Pediatr.* 2011;159(2):256-61.
- Redding GJ, Kuo W, Swanson JO. Upper thoracic shape in children with pectus excavatum: impact on lung function. *Pediatr Pulmonol.* 2013;48(8):817-23.
- Funk JF, Gross C, Placzek R. Patient satisfaction and clinical results 10 years after modified open thoracoplasty for pectus deformities. *Langenbecks Arch Surg.* 2011;396(8):1213-20.
- Deviggiano A, Vallejos J, Vina N. Exaggerated Interventricular dependence among patients with Pectus Excavatum: combined assessment with cardiac MRI and chest CT. *AJR Am J Roentgenol.* 2017;1-8.
- Fonkalsrud EW, Dunn JC, Atkinson JB. Repair of pectus excavatum deformities: 30 years of experience with 375 patients. *Ann Surg.* 2000;231(3):443-8.
- Ravitch MM. The operative treatment of Pectus Excavatum. *Ann Surg.* 1949;129(4):429-44.
- Jaroszewski D, Notrica D, McMahon L, Steidley DE, Deschamps C. Current management of pectus excavatum: a review and update of therapy and treatment recommendations. *J Am Board Fam Med.* 2010;23:230-9.
- Grozavu C, Iliş M, Marin D, Pantile D, Dabelea C, Augustin T. Minimally invasive repair for pectus excavatum - aesthetic and/or functional? *Chirurgia-Bucharest.* 2013;108:70-8.
- Fokin AA, Steuerwald N, Ahrens WA, Allen KE. Anatomical, histologic, and genetic characteristics of congenital chest wall deformities. *Sem Thorac Cardiovasc Surg.* 2009;21:44-57.
- Innocenti A, Melita D, Mori F, Ciancio F, Innocenti M. Management of gynecomastia in patients with different body types. *Ann Plast Surg.* 2017;78(5):492
- Poston PM, Patel SS, Rajput M. The correction index: setting the standard for recommending operative repair of pectus excavatum. *Ann Thorac Surg.* 2014;97(4):1176-9.
- Bahadir AT, Kuru P, Afacan C, Ermerak NO, Bostanci K, Yuksel M. Validity and reliability of the Turkish version of the Nuss questionnaire modified for adults. *Korean J Thorac and Cardiovas Surg.* 2015;48:112-9.
- Steinmann C, Krille S, Mueller A, Weber P, Reingruber B, Martin A. Pectus excavatum and pectus carinatum patients suffer from lower quality of life and impaired body image: a control group comparison of psychological characteristics prior to surgical correction. *Eur J Cardio-Thorac.* 2011;40:1138-45.
- Hanna WC, Ko MA, Blitz M, Shargall Y, Compeau CG. Thoracoscopic Nuss procedure for young adults with pectus excavatum: excellent midterm results and patient satisfaction. *Ann Thorac Surg.* 2013;96:1033-8.
- Ji Y, Liu W, Chen S, Xu B, Tang Y, Wang X, et al. Assessment of psychosocial functioning and its risk factors in children with pectus excavatum. *Health Qual Life Out.* 2011;9:28.
- Bostanci K, Ozalper MH, Eldem B, Ozyurtkan MO, Issaka A, Ermerak NO, et al. Quality of life of patients who have undergone the minimally invasive

- repair of pectus carinatum. *Eur J Cardio-Thorac*. 2013;43:122-6.
19. Kuru P, Bostanci K, Ermerak NO, Bahadir AT, Afacan C, Yuksel M. Quality of life improves after minimally invasive repair of pectus excavatum. *Asian Cardiovas Thorac Ann*. 2015;23:302-7.
 20. Kanagaratnam A, Phan S, Tchanchaleishvili V. Ravitch versus Nuss procedure for pectus excavatum: systematic review and meta-analysis. *Ann Cardiothorac Surg*. 2016;5(5):409-21.
 21. Bauhinias I, Johannes SG. Observationum medicarum, rararum, Novarum, admirabilium, montrosarum, liber secundus. thoracic contents. Observation. 1594;264:516.
 22. Ebstein W. Uber die trichterbrust. *Arch Klin Med*. 1882;411-23.
 23. Johnson WR, Fedor D, Singhal S. Systematic review of surgical treatment techniques for adult and pediatric patients with pectus excavatum. *J Cardiothorac Surg*. 2014;9:25.
 24. Kelly RE, Goretsky MJ, Obermeyer R, Kuhn MA, Redlinger R, Haney TS. Twenty-one years' experience with minimally invasive repair of pectus excavatum by the Nuss procedure. *Ann Surg*. 2010;252(6):1072-81.
 25. Landolfo KP, Sabiston Jr DC. Disorders of the sternum and the chest wall. In: Sabiston DC Jr, Spencer FC, editors. *Surgery of the chest*, 6th Ed. Philadelphia, PA: Saunders; 1991:494-8.
 26. Lansman S, Serlo W, Linna O, Pohjonen T, Tormala P, Waris T, et al. Treatment of pectus excavatum with bio-absorbable polylactide plates: preliminary results. *J Pediatr Surg*. 2002;37:1281-6.
 27. Haecker FM, Sesia SB. Intraoperative use of the vacuum bell for elevating the sternum during the Nuss procedure. *J Laparoendosc Adv Surg Tech A*. 2012;22:934-6.
 28. Marulli G, Hamad AM, Cogliati E, Breda C. Allograft sternochondral replacement after resection of large sternal chondrosarcoma. *J Thorac Cardiovasc Surg*. 2010;139: e69-70.
 29. Knudsen MR, Nyboe C, Pilegaard HK. Routine postoperative chest X-ray is unnecessary following the Nuss procedure for pectus excavatum. *Interact Cardiovasc Thorac Surg*. 2013;16(6):830-3.
 30. Geva T. Is MRI the preferred method for evaluating right ventricular size and function in patients with congenital heart disease? MRI is the preferred method for evaluating right ventricular size and function in patients with congenital heart disease. *Circ Cardiovasc Imaging*. 2014;7:190-7.

Cite this article as: Iroegbu CD, Zhongxin Z, Sheng T, Jiang BO, Jingsong L. Pectus excavatum-insights into its diagnosis and the current treatment options along with its clinical outcomes: two case reports. *Int Surg J* 2018;5:756-64.

ANNEXURE: 1

Patient consent [case 1]

Name of person described in article or shown in photograph: NI Jiahao

Subject matter of photograph or article: Pectus excavatum

Journal name: International Surgery Journal.

Title of article: Pectus excavatum: insights into its diagnosis and the current treatment options along with its clinical outcomes. Two case report and a review of the literature.

Corresponding author: Iroegbu Chukwuemeka Daniel MD.

I NI SUN [insert full name] give my consent for this information about MYSELF/MY CHILD* OR WARD/MY RELATIVE, relating to the subject matter above ("the Information") to appear in the journal and associated publications.

I have seen and read the material to be submitted to the journal

I understand the following:

- (1) The Information will be published without my name attached and journal will make every attempt to ensure my anonymity. I understand, however, that complete anonymity cannot be guaranteed. It is possible that somebody somewhere - perhaps, for example, somebody who looked after me if I was in the hospital or a relative - may identify me.
- (2) The text of the article will be edited for style, grammar, consistency, and length
- (3) The Information may be published in the journal, which is distributed worldwide. The the journal goes mainly to doctors but is seen by many non-doctors, including journalists.
- (4) The Information will also be placed on the journal website.
- (5) The Information may also be used in full or in part in other publications and products published by the journal or by other publishers to whom the journal licenses its content. This includes publication in English and in translation, in print, in electronic formats, and in any other formats that may be used by the journal or its licensees now and in the future. In particular, the Information may appear in local editions of the journal or other journals and publications published overseas.
- (6) The journal will not allow the Information to be used for advertising or packaging or to be used out of context.
- (7) I can revoke my consent at any time before publication, but once the Information has been committed to publication ("gone to press") it will not be possible to revoke the consent.

Signed: Sun NI. Date: 20 September 2017.

ANNEXURE: 2

Patient consent [case2]

Name of person(s) described in article or shown in photograph: Zoujia Mie

Subject matter of photograph or article: Pectus excavatum

Journal name: International surgery journal.

Title of article: Pectus excavatum: insights into its diagnosis and the current treatment options along with its clinical outcomes. Two case report and a review of the literature.

Corresponding author: Iroegbu Chukwuemeka Daniel MD.

I Zoujia Wei [insert full name] give my consent for this information about MYSELF/MY CHILD* OR WARD/MY RELATIVE relating to the subject matter above ("the Information") to appear in the journal and associated publications.

I have seen and read the material to be submitted to the journal

I understand the following:

- (1) The Information will be published without my name attached and journal will make every attempt to ensure my anonymity. I understand, however, that complete anonymity cannot be guaranteed. It is possible that somebody somewhere - perhaps, for example, somebody who looked after me if I was in the hospital or a relative - may identify me.
- (2) The text of the article will be edited for style, grammar, consistency, and length
- (3) The Information may be published in the journal, which is distributed worldwide. The the journal goes mainly to doctors but is seen by many non-doctors, including journalists.
- (4) The Information will also be placed on the journal website.
- (5) The Information may also be used in full or in part in other publications and products published by the journal or by other publishers to whom the journal licenses its content. This includes publication in English and in translation, in print, in electronic formats, and in any other formats that may be used by the journal or its licensees now and in the future. In particular, the Information may appear in local editions of the journal or other journals and publications published overseas.
- (6) The journal will not allow the Information to be used for advertising or packaging or to be used out of context.
- (7) I can revoke my consent at any time before publication, but once the Information has been committed to publication ("gone to press") it will not be possible to revoke the consent.

Signed: Wei Zoujia Date: 20 september 2017.