

## Case Report

# Gynaecomazia in a HIV, Hepatitis B and C affected middle aged male: a case report

Ajay Kumar<sup>1\*</sup>, Sarada Khadka<sup>2</sup>, Shailesh Adhikary<sup>2</sup>

<sup>1</sup>Department of Surgery, Aseem Health Care and Trauma Centre, Muzaffarpur, Bihar, India

<sup>2</sup>Department of Surgery, BPKIHS, Dharan, Nepal

**Received:** 25 November 2017

**Revised:** 01 January 2018

**Accepted:** 04 January 2018

### \*Correspondence:

Dr. Ajay Kumar,

E-mail: [drajay2006@gmail.com](mailto:drajay2006@gmail.com)

**Copyright:** © the author(s), publisher and licensee Medip Academy. This is an open-access article distributed under the terms of the Creative Commons Attribution Non-Commercial License, which permits unrestricted non-commercial use, distribution, and reproduction in any medium, provided the original work is properly cited.

## ABSTRACT

Gynaecomazia is benign proliferation of male breast tissue. Asymptomatic gynaecomazia has a trimodal age distribution, occurring in neonatal, pubertal, and elderly males causing considerable anxiety to the patients. Although it is a common disease but its presentation in middle age is rare, which demands thorough investigations to look for underlying cause. The patient 42-year gentleman presented with bilateral enlarged breasts gradually progressive for two years. He did not experience any pain or discharge from nipples. He was an intravenous drug abuser, and has had pulmonary tuberculosis treated 14 years back. He also had infection by human immunodeficiency virus for nine years and was treated with anti-retroviral therapy. He was also tested positive for HBsAg and anti-HCV. To best of literature search, we could find only few case reports related to gynaecomazia in Nepal, neither from eastern region nor as a side effects of drugs. Also, gynaecomazia related to ART or anti-tubercular drugs were reported within few months or a year of commencement of therapy. Similarly, cases with multiple risk factor exposure have not been often reported.

**Keywords:** ART, Gynaecomazia, HIV, Hepatitis C

## INTRODUCTION

Gynaecomazia is defined as a benign proliferation of male breast tissue. Asymptomatic gynaecomazia is very common and has a trimodal age distribution, occurring in neonatal, pubertal, and elderly males.<sup>1</sup> In Nepal, gynaecomazia comprises 2.5% of all breast lumps.<sup>2</sup> It is usually caused by increased estrogen activity, decreased testosterone activity, or by the use of numerous medications and can cause considerable anxiety to the patients.<sup>3</sup>

In HIV-infected individuals, the estimated prevalence ranges from 2 to 3% and it may be associated with the use of potent antiretroviral therapy.<sup>4</sup> The differential

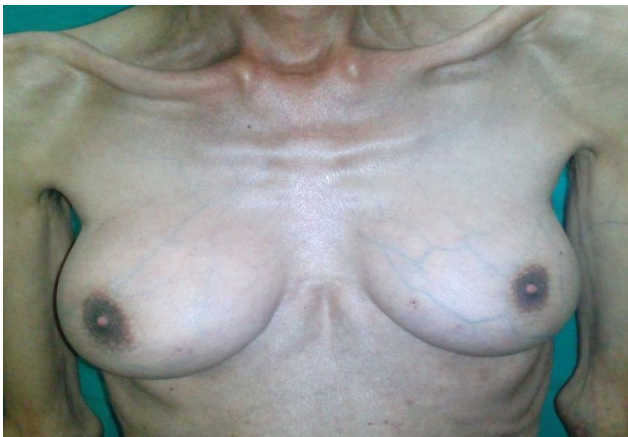diagnoses of palpable breast mass in males include pseudogynecomastia, breast cancer, and numerous other benign conditions. Imaging and laboratory tests are done to exclude neoplasms and endocrinopathies; and may facilitate a cost-effective diagnosis. If results of all studies are normal, idiopathic gynaecomazia is diagnosed.

Although it is a common disease but its presentation in middle age is rare, which demands thorough investigations to look for underlying cause. To best of literature search, we could find only few case reports related to gynaecomazia in Nepal, neither from eastern region nor as a side effects of drugs. Also, gynaecomazia related to ART or anti-tubercular drugs were reported

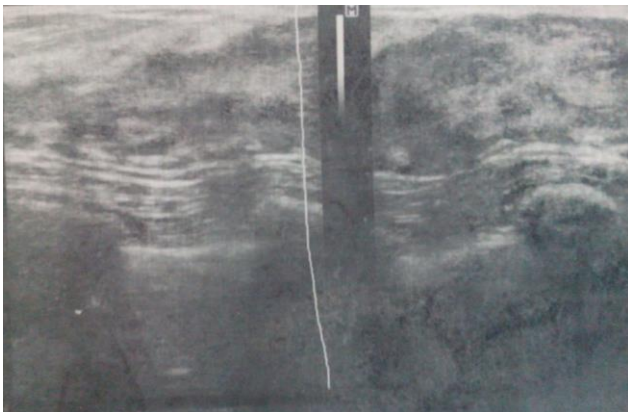
within few months or a year of commencement of therapy. Similarly, cases with multiple risk factor exposure have not been often reported.

### CASE REPORT

A 42-year gentleman attended our clinic with the presenting complaints of enlarged breasts on both sides. It had started increasing in size gradually two years earlier. He did not experience any pain or discharge from nipples. He was an intravenous drug abuser, and has had pulmonary tuberculosis treated 14 years back. He also had infection by human immunodeficiency virus for nine years and was treated with anti-retroviral therapy (Tenofovir, Lamivudine, and Efavirenz).



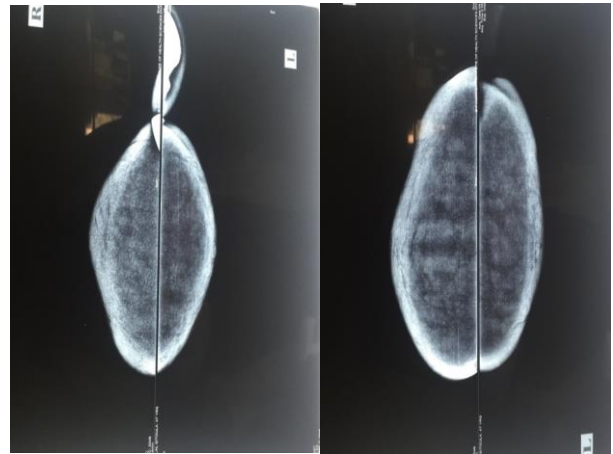
**Figure 1: Middle aged man with bilateral gynecomazia.**



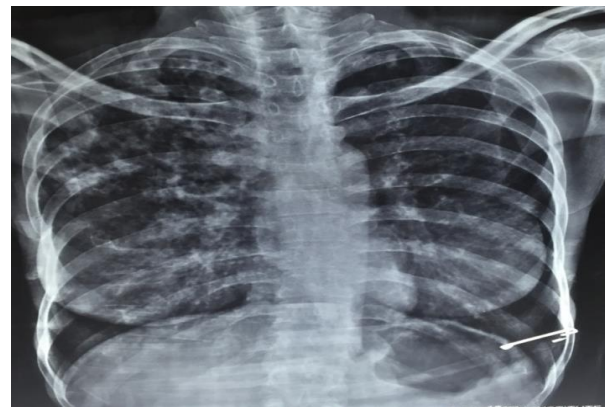
**Figure 2: USG showing dense fibro-glandular tissue suggesting gynecomazia.**

There was no other relevant past medical history. He looked cachexic with body mass index of 12.78kg/m<sup>2</sup>. He had bilateral, symmetrical, elastic, and concentric swellings of both breasts, without discrete nodules or skin changes. Lymphadenopathy was not detected in the axilla or neck. On abdominal assessment there was hepatomegaly. He had small testicles. Rest of the physical examination was normal. There were no

stigmata of chronic liver disease. Complete blood counts showed neutrophilia (84%), elevated erythrocyte sedimentation rate but liver enzymes were within normal limits. Ultrasonography showed prominent fibroglandular tissue on both sides, suggestive of gynecomazia. Mammography showed no evidence of mass, calcification or architectural distortion (BI-RADS category I) for bilateral breasts. Fine needle aspiration cytology showed benign ductal epithelial cells, with intact myoepithelial cells.



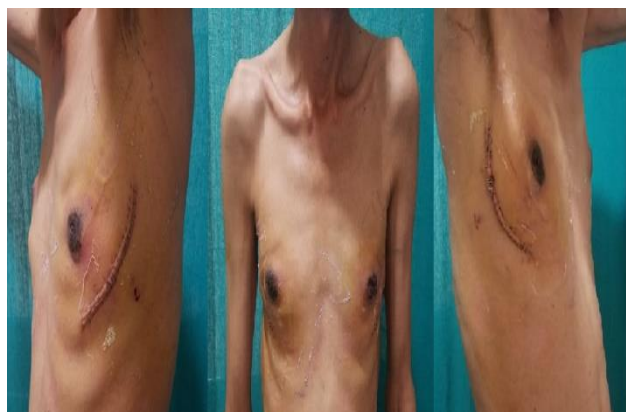**Figure 3: Right and Left mammogram: Skin shows no thickness or edema, nipple not retracted. Fibroglandular tissue and muscles appears normal. No e/o mass, calcifications or architectural distortion. Axillary region appears normal.**



**Figure 4: Chest radiograph showing post-tubercular changes in the form of fibrosis.**

Hormonal assay showed low testosterone level (0.59ng/ml) with elevated luteinizing hormone (18.7miu/ml), thyroid function test was normal. Sputum for acid fast bacilli was negative but genexpert was positive for mycobacterium. He tested positive for human immunodeficiency virus, hepatitis B surface antigen and anti-hepatitis C virus. Pulmonologist consultation was done, and anti-tubercular therapy was started. He was called after 6 weeks for pre-anaesthetic check-up. He

underwent sub-cutaneous mastectomy. Post-operative period was uneventful.



**Figure 5: Post-operative state.**

## DISCUSSION

Gynaecomazia, is defined as a benign proliferation of breast tissue in males. There are two broad categories: physiological gynaecomazia (common) and pathological gynaecomazia (uncommon). Physiological gynaecomazia is self-limiting and occurs in newborns, adolescents, and the elderly.<sup>5</sup> The prevalence of asymptomatic gynaecomazia is 60 to 90% in neonates, 50 to 60% in adolescents, and up to 70% in men aged 50 to 69 years.<sup>3</sup> It has to be distinguished from pseudogynecomastia and lipomastia, which are both forms of fat accumulation in the breasts. Lipomastia is part of the lipodystrophy syndrome. Breast palpation can help to distinguish fat accumulation in the breasts from true gynaecomazia. In gynaecomazia, typically a soft, elastic or firm disk-shaped mass, that is concentric with the nipple-areola, can be palpated with the patient lying flat on his back. Uncommonly, benign tumours and breast cancer can also cause breast enlargement in males.

Once the presence of gynaecomazia is established, a differential diagnosis of its causes needs to be considered. The pathological causes can be further divided up into three subcategories, namely testosterone deficiency, increased oestrogen production, and drug-induced breast enlargement. Testosterone deficiency can occur in HIV infection. Causes of excess oestrogen include  $\beta$ -HCG-producing tumours (eg. testicular cancers), chronic liver disease, and malnutrition.

The pathogenesis of and the risk factors for gynaecomazia among HIV-infected men remain poorly understood. Possible mechanisms for gynaecomazia in HIV infected males are hypogonadism (as evidenced by a significantly lower free testosterone level) and drug therapy (e.g. anti-tuberculous drugs). Lipomastia/pseudogynaecomastia may appear as part of the HAART associated lipodystrophy syndrome.<sup>6</sup>

With the introduction of highly active antiretroviral therapy (HAART), breast enlargement emerged as a side effect. The incidence of gynaecomazia at 2 years is 2.8% in patients treated with highly active antiretroviral therapy.<sup>4</sup> The mean delay on appearance of gynaecomazia following initiation of HAART is 9 months.<sup>6</sup> In several other studies associations between gynaecomazia and specific antiretroviral drugs, including stavudine and efavirenz, have been reported.<sup>5</sup> In most cases, gynaecomastia cases reported occurred after prolonged efavirenz exposure. Efavirenz is known to be associated with gynaecomazia, as when switched from efavirenz, gynaecomazia improved/resolved in the majority. The proposed mechanism from in vitro data is that efavirenz mimics the effects of oestrogen on breast tissue. Two other hypothesized mechanisms have been suggested for ART-associated gynaecomazia are: a) immune restoration may increase breast tissue oestrogen availability, and b) efavirenz has been shown to increase the area under the curve of ethinyl oestradiol by at least 37%, thereby elevating the oestrogen-androgen ratio.<sup>7,8</sup> Opportunistic infection, lymphoma, Kaposi's sarcoma and pseudoangiomatous stromal hyperplasia (PASH) form part of the further differential diagnosis.<sup>6</sup>

It was also found that gynaecomazia among HIV-infected patients is related to hypogonadism, rather than to an adverse effect of antiretroviral drugs, while other study report that lipodystrophy and chronic hepatitis C are independent factors associated with gynaecomazia.<sup>9</sup>

Gynaecomazia among HIV-infected men is an uncommon condition with a prevalence (2-3%) similar to that reported in the general male population.<sup>2,3</sup> In contrast, hypogonadism among HIV-infected adult men seems to be a condition that has been underestimated in frequency, and it was an independent factor associated with gynaecomazia.<sup>8</sup>

In the reported case, patient was exposed to numerous risk factors like drugs, HCV infection and hypogonadism. He took anti-tubercular drugs twelve years before the onset of symptoms and taking Efavirenz based ART for seven years before he noticed breast swelling, which differs from most of the studies. Duration of HBV, HCV infection and hypogonadism was unknown to the patient, until he visited our hospital. This demonstrates the importance of appearance of delayed adverse drug effects and multifactorial pathophysiology of gynaecomazia.

*Funding: No funding sources*

*Conflict of interest: None declared*

*Ethical approval: Not required*

## REFERENCES

1. Braunstein GD. Gynecomastia. *N Engl J Med.* 2007;357(12):1229-37.

2. Kumar R. A Clinicopathologic Study of Breast Lumps in Bhairahwa, Nepal. *Asian Pacific J Cancer Prev.* 2010;(11):855-8.
3. Johnson RE, Murad H. Gynecomastia: Pathophysiology, Evaluation, and Management. *Mayo Clin Proc.* 2009;84(11):1010-5.
4. Piroth L, Grappin J, Petit M, Buisson M, Duong M, Chavanet P, Portier H. Incidence of gynecomastia in men infected with HIV and treated with highly active antiretroviral therapy. *Scand J Infect Dis.* 2001;33:559-60.
5. Kwekwesa A. Breast enlargement in Malawian males on the standard first-line antiretroviral therapy regimen: case reports and review of the literature. *Malawi Med J.* 2015;27(3):115-7.
6. Meerkotter. Gynaecomastia associated with highly active antiretroviral therapy (HAART). *Radiol Case.* 2010;4(7):34-40.
7. Biglia A, Blanco JL, Martínez E, Domingo P, Casamitjana R, Sambeat M, et al. Gynecomastia among HIV-infected patients is associated with hypogonadism: a case-control study. *Clin Infect Dis.* 2004;39(10):1514-9.
8. Njuguna C, Swart A, Blockman M, Maartens G, Chisholm B, Stewart A, et al. Cases of antiretroviral-associated gynaecomastia reported to the National HIV and Tuberculosis Health Care Worker Hotline in South Africa. *AIDS Res Therap.* 2016;13(1):40.
9. Biglia A. Gynecomastia among HIV-infected patients is associated with hypogonadism: a case-control study. *Clin Infect Dis.* 2004;39:1514-9.

**Cite this article as:** Kumar A, Khadka S, Adhikary S. Gynaecomazia in a HIV, Hepatitis B and C affected middle aged male: a case report. *Int Surg J* 2018;5:735-8.