

Case Report

Giant retroperitoneal teratoma displacing kidney causing acquired crossed non-fused renal ectopia: rare case report

Monika Gupta*, Ravi Gupta

¹Department of GI, HPB and Minimal Invasive Surgery, ²Department of Urology and Renal Transplant, Narayana Multi speciality Hospital, Pratap Nagar Jaipur, Rajasthan, India

Received: 23 November 2017

Accepted: 28 December 2017

***Correspondence:**

Dr. Monika Gupta,

E-mail: guptamons1506@gmail.com

Copyright: © the author(s), publisher and licensee Medip Academy. This is an open-access article distributed under the terms of the Creative Commons Attribution Non-Commercial License, which permits unrestricted non-commercial use, distribution, and reproduction in any medium, provided the original work is properly cited.

ABSTRACT

This is a rarest of rare case of surgical resection of giant retroperitoneal teratoma in a 15 yr old female child, causing displacement of left kidney to right by its huge volume (45X30X25cm= 33750cm³), making it appear like acquired crossed confused renal ectopia. Teratomas can occur anywhere in abdomen. Ovary being most common site followed by retroperitoneum. The most common age group is <1yr of age but they can present in any age. There are various case reports describing giant teratomas of various sizes in children and adults. Largest reported size is of 35x35cm size in a 33 yr old female. The case author has operated is rare case ever reported of 'most voluminous retroperitoneal teratoma in 15 yr old female' with displacement of all intra-abdominal structures by its volume. Tumor was 45x30x25cm with 12kg weight. When presented patient had complaints of vague discomfort and extreme abdominal distension progressive over last 1 yr. Patient underwent surgery -Excision of tumor, which needed dissection from superior mesenteric artery and vein, splenic vein, pancreas, retroperitoneum, splenic vein, diaphragm and left kidney. Left kidney was rotated to right side, causing it to appear like 'acquired crossed confused renal ectopia' The left kidney was safely replaced to its original position in left renal fossa. The histopathology of tumor was of mature teratoma with no evidence of malignancy. Patient remained symptom free and recurrence free during 5 yrs follow up. Mature cystic teratomas are benign in nature they can attain enormous size in abdomen and can displace any intrabdominal structure. Surgeons should be aware that these big tumors can be resected with preservation of displaced structures in abdomen. Careful surgery is essential for preservation of abdominal organs and to ensure quality of life of patient.

Keywords: Acquired crossed renal ectopia, Giant teratoma, Most voluminous, Mature teratoma, Retroperitoneal teratoma

INTRODUCTION

This is a rarest of rare case of giant retroperitoneal teratoma in a 15 yr old female child, causing displacement of left kidney to right by its huge volume (45X30X25cm=33750cm³), making it appear like 'acquired crossed nonfused renal ectopia'. Tumor resected 5 yrs back and patient is free of any symptoms or recurrence in 5 yrs of follow up. This patient presented to us when she was 15 yrs old with progressive abdominal distension for last 1yr, no h/o vomiting, severe

pain, anorexia, obstipation or sudden distension. Patient had h/o reduced oral intake due to space occupying mass lesion in abdomen. On examination patient had normal vitals, anemia +nt, P/A -mass was extending from 5cm below costal margin till left iliac fossa and on right side 10 cm below costal margin till just above RIF, her abdomen was massively protuberant, full of firm, nontender mass, non-ballotable, non-compressible. Bowel sounds present. Patient had not attained menarche, there was no previous surgeries reported.

CASE REPORT

On admission patient was found to have Hb-5.2gm/dl which was corrected preoperatively with 4 units of blood transfusion. Patient already had a CECT which showed well encapsulated cystic solid mass. CECT abdomen was repeated which showed large retroperitoneal mass of solid cystic nature with extension from just behind stomach and liver above till left and right iliac region, there was complete displacement of left kidney towards right side with left renal vein and artery rotating towards right to supply displaced left kidney (Figure 1 and 2). The mass was occupying $\frac{3}{4}$ th of abdominal cavity (Figure 1 and 2). Serum tumor markers were -AFP-2.43ng/ml, HCG-1.20miu/ml, CEA- 0.50ng/ml, CA 125-97u/ml.

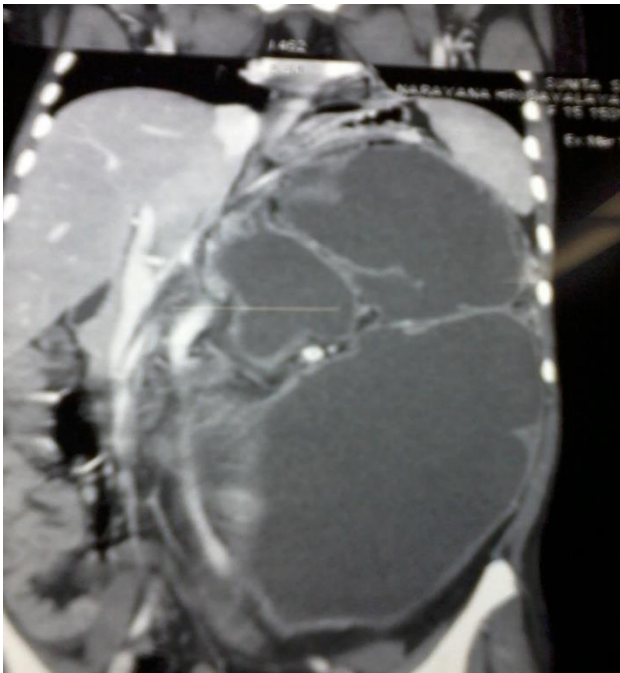

Figure 1: CECT showing massive solid cystic mass, well encapsulated.

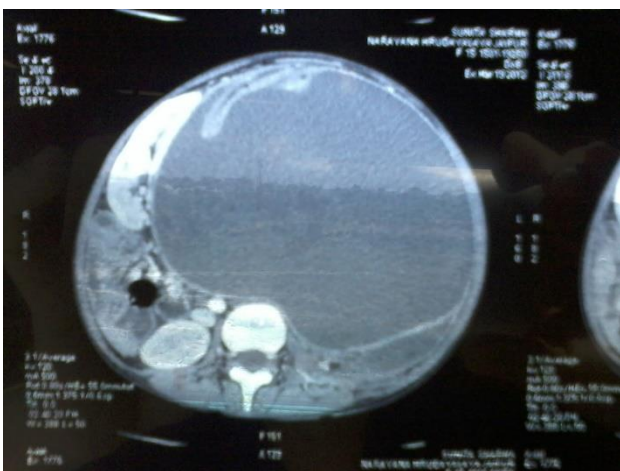

Figure 2: Massive teratoma causing acquired crossed nonfused renal ectopia.

After full discussion with radiologist and urologist (2nd author of the report) about the nature of mass, its encapsulation, vascularity, organ of origin, options related to preserving rotated left kidney and possible structures which may need sacrifice, it was decided to excise the mass. In preoperative assessment there was no active intratumoral bleed /no major vascular supply/vascular origin, there was no s/o malignancy as encapsulation of mass was present all over. The only thing in mind was to respect the huge mass safely if benign and give her best chance for cure. Nephrectomy consent was well explained preoperatively.

The preoperative challenges in this case were:

- To differentiate Giant vascular hemangioma, intraabdominal malignancy, cystic teratoma.
- To rule out malignancy, to confirm encapsulation of mass in order to ascertain resectability.
- To rule out vascular nature of this tumor and intracystic bleed.
- To preserve intraabdominal organs mainly displaced left kidney, SMA, SMV, SV, RA, RV, mesocolic vessels and prevent intestinal injury.

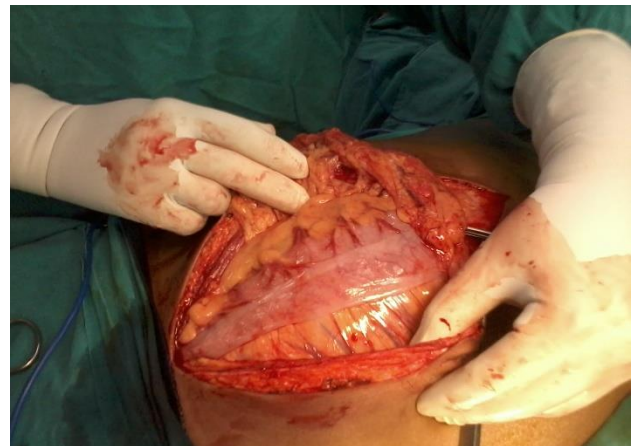


Figure 3: On opening of abdomen, over stretched transverse and sigmoid colon over massive retroperitoneal teratoma.

After full evaluation, preoperative assessment and counseling of parents about possible need of left nephrectomy, patient underwent surgery. Surgery done was excision of tumor, dissecting it from SMA, SMV, SV, pancreas, retroperitoneum and left kidney, safely preserving all structures. After dissection of RV and RA from capsule of tumor (Figure 4), left kidney was rotated rt from left side and safely replaced to its original position in left renal fossa (Figure 5).

Due to its massive volume whole transverse, descending and sigmoid colon was over stretched on front of tumor (Figure 3). Tumor needed controlled decompression by suction of blood and liquid content before starting dissection from surrounding structures the opening from

which contents suctioned was repaired with silk to avoid leakage of contents. The mobile kidney was fixed with sutures in left renal fossa. Incision extended from xiphoid till pubic symphysis (Figure 6).

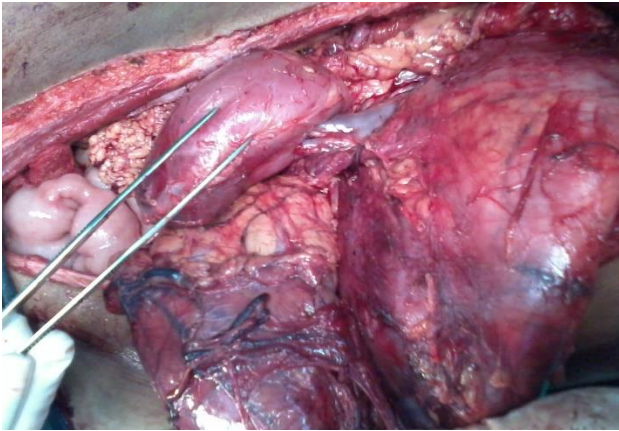


Figure 4: Rotated left kidney to right being dissected from decompressed tumor.

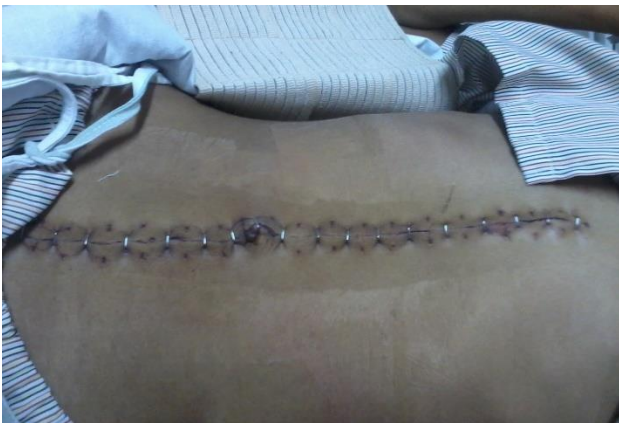

Figure 5: Abdomen after excision of tumor showing left kidney replaced to left renal fossa.

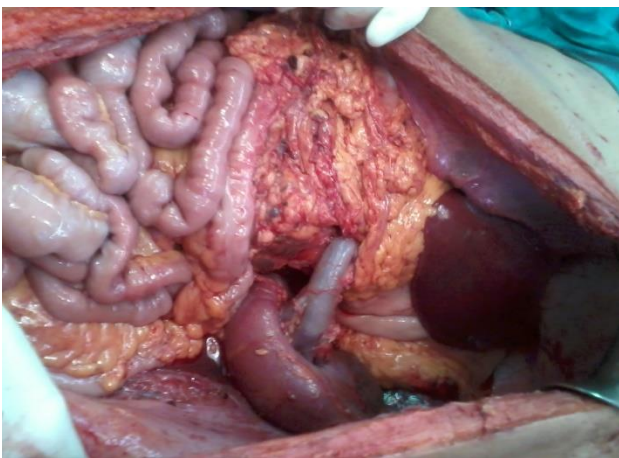

Figure 6: Final postoperative pic showing incision from xiphoid till symphysis pubis.

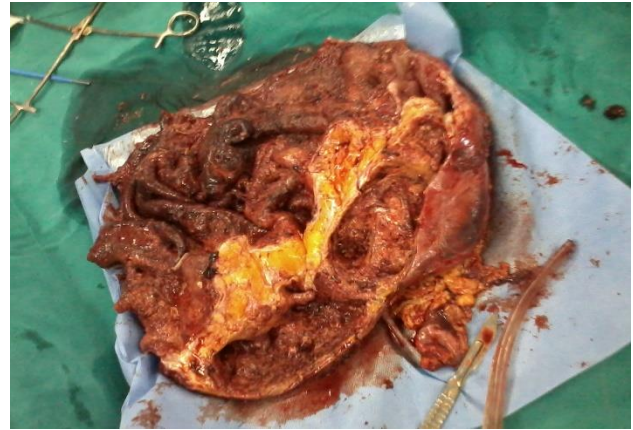

Figure 7: Teratoma on cut section.

Surgery lasted for 4 hours and total blood loss was 400ml. After removal the contents were weighed 12kg including solid and liquid material. The gross appearance of mass is shown (Figure 7). The final status of abdomen after removal of mass is as shown (Figure 5). The tumor mainly consisted of thick walled mass with multiloculated appearance with sebaceous material, hair, skin, cartilage, bone as contents. The histopathology of tumor was of mature teratoma having cartilage, skin, hair, sebaceous material as a content and components, there was no evidence of malignancy.

Postoperatively patient had tachycardia and anemia on day 1 which was treated with blood and FFP transfusion and higher antibiotics. On day 3 oral diet was started and well tolerated, initially drain had sero-sanguinous drainage about 700cc on day 1 which reduced to 100cc/day and removed on day 9. Drain fluid amylase was normal. Patient was discharged on day 10.

DISCUSSION

The mostcommon types of GCT are: teratomas, germinomas, endodermal sinus tumor or yolk sactumors, choriocarcinoma and embryonalcarcinoma. Teratomas are considered to be the most prevalent type of germ cell tumors in children.¹ Retroperitoneal teratomas are rare and account for only 4% of all primary teratomas. They have bimodal peak of incidence, most commonly reported in 1yr of life and rarely in early adulthood. In a large series published by AK Sharma et al from Jaipur India, 75 children were included under 12 yrs of age, 75% presented within 1st year.² Teratomas can occur anywhere in abdomen, as 15% of teratomas are extragonadal. There have been reports of mature teratoma in ovaries, pouch of doughlas, abdominal wall, stomach, adrenal, kidney, pancreas, spleen, retrorectal and merentric. When present in retroperitoneum they can be arising from adrenal gland or from retroperitoneum itself. There are report of adrenal origin of mature teratoma.^{3,4} Most of benign teratomas are asymptomatic and attain enormous size before presentation.

As for the diagnosis of these tumors, radiographic evaluations are of a great importance. Ultrasound can distinguish between cystic and solid components and CT scan /MRI can guide about components, invasion of surrounding structures present or not, vascularity and encapsulation. Serum tumors markers may be elevated in teratomas AFP, CEA and CA-19-9. These markers can be used for monitoring successful treatment or relapse of the tumor in the patients.⁵

Surgical excision and histopathological examination of mature (benign) teratoma is required for a definitive diagnosis.⁷ When present for long duration there can be malignant changes in mature cystic teratoma in form of squamous cell carcinoma, gliomatosis peritoni, adenocarcinoma, carcinoid. The diagnosis of malignant change can be done when sudden growth is observed in already existing abdominal mass or after final histopathology. There can be gliomatosis peritoni arising from mature cystic teratoma if left untreated.⁶ In this case cut section revealed multiloculated fleshy mass with sebaceous contents with skin, hair and bony mass. There was sebaceous material, keratinised epithelium, hair and cartilage in histopathological examination, with no evidence of malignant change.

These tumors are asymptomatic and gradually increase in size. Due to lack of symptoms and availability of space in peritoneal cavity, they attain enormous size when present. Various case reports have mentioned different tumor sizes and weight. Till now the maximum size reported in literature is of mature cystic teratoma in a 33 yr old lady, extending from pancreas upto pelvis about 35x35cm size (weight not mentioned) and of 22x17x7cm size and 1.6kg weight, in a 39 yr old lady, at rt adrenal region.^{5,8} Considering volume-33,750cm³, weight 12kg vs age of patient the case is probably largest ever reported in a child as young as 15 yrs of age. There was 10kg fluid and 2kg solid mass in tumor (Figure 5). The size of tumor was so huge that it caused displacement of nearly all structures in abdomen except liver (Figure 1). Tumor was displacing SMA and SMV to right side with rt border of tumor adherent to superior mesenteric vessels. Superiorly it was causing displacement of pancreas towards anterior and superior direction with SMV-PV junction overstretched by upper border of capsulated tumor. Being in retroperitoneum it caused left kidney, left renal vein and artery to displace and reach a position on anterior to rt kidney (Figure 2). The transverse mesocolon, descending colon and sigmoid colon was extremely overstretched over tumor (Figure 3). Left laterally it was adherent to diaphragm.

Although renal teratomas have been rarely reported author dont consider this tumor to be renal origin as its described in literature. For it to be classified as renal teratoma it should be contained in renal capsule. In this case tumor was not arising in kidney it originated in retroperitoneum and due to extremely large size it displaced left kidney and its hilum to right side casing it

appears like 'acquired crossed nonfused renal ectopia'.¹⁰ Various renal migration anomalies are congenital such as simple renal ectopia - abnormal position of the kidney in the cranial or caudal direction on same side of origin. There are 4 different recognized types of simple renal ectopia:

- Pelvic or sacral kidney
- Lumbar or iliac ectopic kidney
- Superior ectopic kidney (subdiaphragmatic)
- Thoracic kidney located above the diaphragm and in the chest

The most common renal fusion anomaly is the horseshoe kidney in which the 2 renal masses are fused together in the midline.¹¹ Crossed renal ectopia is a rare congenital anomaly, where one of the kidneys crosses the midline and lies opposite to the site of its normal ureteral insertion. Ninety percent of crossed ectopic kidneys are fused to their ipsilateral uncrossed kidney (1:7000).¹¹ Crossed renal ectopia without fusion is extremely rare (1 in 75,000), only 1 reported in literature.¹¹ In this case the finding is of rarest variety of acquired crossed renal ectopia which is not reported in literature anywhere. After dissection from tumor the native left kidney could be brought to original position without having any distortion of its hilum (Figure 5).

Primary adrenal teratomas are rare neoplasms that typically present as large, left-sided retroperitoneal mass.³ Laparoscopic excision is possible in teratoma esp if mature teratoma is suspected. There are reports of laparoscopic /retroperitoneoscopic resection of adrenal teratoma.^{8,9} In this case tumor was not originating from adrenal gland. Although author do laparoscopic surgery for G I tract tumors, but the approach varies case to case.⁴ In this case laparoscopy was not planned seeing extremely huge volume of tumor with no space in abdomen for creation of pneumoperitoneum (Figure 4).

Patient was followed up for 5 yrs and remained asymptomatic and recurrence free during follow up.

Lessons learnt

Careful surgery in most massive tumors can save intraabdominal organs, can give reasonable quality of life to the patient. The operated child is now free of disfiguring abdominal tumor, at present she is 20 yrs of age and she is studying in medical college pursuing nursing course.

CONCLUSION

Teratomas can reach giant size with displacement of kidney anterior to them causing it to appear like crossed non-fused renal ectopia. One should evaluate respectability of massive tumors with appropriate imaging in coordination with radiologists. Author hereby conclude a rare case of most voluminous and heavy

retroperitoneal teratoma being safely excised and followed up for 5 yrs.

Funding: No funding sources

Conflict of interest: None declared

Ethical approval: Not required

REFERENCES

1. Khaleghnejad-Tabari A, Mirshemirani A, Rouzrokh M, Mohajerzadeh L, Khaleghnejad-Tabari N, Hasas-Yeganeh S. Pediatric germ cell tumors; A 10-year experience. *Iranian J Pediatr.* 2014;24(4):441.
2. Sharma AK, Sharma CS, Gupta AK. Teratomas in pediatric age group: experience with 75 cases. *Indian Pediatr.* 1993 May;30(5):689-94.
3. Kuo EJ, Sisk AE, Yang Z. Adrenal Teratoma: A Case Series and Review of the Literature. *Endocr Pathol.* 2017 Jun;28(2):152-8.
4. Li H, Zhao T, Wei Q. Laparoscopic resection of a huge mature cystic teratoma of the right adrenal gland through retroperitoneal approach: a case report and literature review. *World J Surg Oncol.* 2015 Nov 18;13:318.
5. Hassan P, Fahimeh A, Alipour-faz A. Primary retroperitoneal mature cystic teratoma in an adult: A case report. *Int J Surg Case Rep.* 2016;28:285-8.
6. Nanda S, Kalra B, Arora B, Singh S. Massive mature solid teratoma of the ovary with gliomatosis peritonei. *Aust N Z J Obstet Gynaecol.* 1998 Aug;38(3):329-31.
7. Walid S, Ricchetti GA, Parvanta L, Giant RC. Mature Primary Retroperitoneal Teratoma in a Young Adult: Report of a Rare Case and Literature Review, 4 case reports in surgery. 2014;930530:5.
8. Li S, Li H, Ji Z, Yan W, Zhang Y. Primary adrenal teratoma: Clinical characteristics and retroperitoneal laparoscopic resection in five adults. *Oncology letters.* 2015 Nov 1;10(5):2865-70.
9. Dong-Dong T, Xian-Sheng Z, Zong-Yao H. Case Report. A giant primary retroperitoneal mature cystic teratoma in right adrenal region in a 39-year-old female. *Int J Clin Exp Med.* 2014;7(6):1611-3.
10. Idrissi-Serhrouchni K, El-Fatemi H, El madi A. Primary renal teratoma: a rare entity. *Diagn Pathol.* 2013;8:107.
11. Al-Hamar ME, Cabr, Khan K. Crossed nonfused renal ectopia with variant blood vessels: a rare congenital renal anomaly. *Radiol Case Rep.* 2017 Mar;12(1):59-6.

Cite this article as: Gupta M, Gupta R. Giant retroperitoneal teratoma displacing kidney causing acquired crossed nonfused renal ectopia: rare case report. *Int Surg J* 2018;5:723-7.