

Original Research Article

Clinical outcome after liver resection for colorectal versus non-colorectal metastasis: a comparative study

Ashraf M. El-Badry, Omar Abdelraheem*

Department of General Surgery, Sohag University Hospital, Sohag University, Egypt

Received: 18 November 2017

Accepted: 25 November 2017

***Correspondence:**

Dr. Omar Abdelraheem,

E-mail: dromar_1818@yahoo.com

Copyright: © the author(s), publisher and licensee Medip Academy. This is an open-access article distributed under the terms of the Creative Commons Attribution Non-Commercial License, which permits unrestricted non-commercial use, distribution, and reproduction in any medium, provided the original work is properly cited.

ABSTRACT

Background: Liver resection is the only curative treatment option for specific types of metastatic neoplasms. Comparative studies on the clinical outcome of liver resection for colorectal liver metastasis (CRLM) and non CRLM (N-CRLM) in Egypt remain inadequate.

Methods: Medical records of patients who underwent liver metastasectomy (April 2013-May 2017) at Sohag University Hospital were reviewed. Patients were categorized according to the origin of the primary tumor into CRLM versus N-CRLM. Demographic, clinical, operative and histopathologic data, postoperative surgical complications and survival were analyzed.

Results: Twenty-six patients (15 CRLM and 11 N-CRLM) were retrospectively enrolled. N-CRLM group comprised metastatic gall bladder (6), pancreas (2), breast (1) lung (1) and recurrent ovarian (1) cancers. There was no significant difference regarding age or gender predilection. The complication score in CRLM group was not significantly different compared with N-CRLM patients. However, subgroups of multivisceral resections showed significantly higher grades of postoperative complications compared with sole liver resection in both groups. Elderly patients (>70-year-old) exhibited high risk of morbidity compared with younger patients. Early post-operative mortality within the first month was 7.7% (2 patients died, one per each group). After a mean follow up of 32 months, the overall survival rate among patients with CRLM and N-CRLM was 75% and 64% respectively.

Conclusions: Liver resection for CRLM and N-CRLM can be safely accomplished. Multivisceral resection and advanced age were associated with increased severity of postoperative complications irrespective of the location of primary neoplasm.

Keywords: Colorectal, Cancer, Liver metastasis, Non-colorectal

INTRODUCTION

Current advances in surgical procedures, diagnostic and interventional imaging, anesthesia and intensive care, and adjuvant therapy resulted in remarkable improvement of the clinical outcome of liver metastasectomy.^{1,2} The scope of potentially curable patients with CRLM was expanded by application of innovative surgical strategies such as two-step liver resection, associating liver partitioning and ligation of the portal vein and ultrasonography-guided single-stage hepatectomy.³ The use of radiofrequency

energy, ultrasonic waves and pressurized water jet devices enabled easier division of the liver parenchyma during liver resection.⁴ Intra-operative blood loss has been diminished by the application of low central venous pressure (CVP) anesthesia and different inflow/outflow hepatic blood flow occlusion techniques.⁵

The introduction of targeted pharmacologic therapy, based on RAS/RAF mutations, in patients with CRLM has improved the response rates to adjuvant chemotherapy and prolongation of survival.^{6,7} Patients

with colorectal cancer and synchronous liver metastasis require multimodal management that includes surgery, chemotherapy and radiotherapy. Three options are available depending on the timing of surgery: the traditional 'primary-first', simultaneous 'combined liver-colorectal' resection and reverse 'liver-first' approach. The later strategy may commence with liver resection "true liver-first" or alternatively by upfront chemotherapy followed by liver metastasectomy.⁸

Strategies of downsizing and downstaging of CRLM by systemic and intra-arterial infusion of neoadjuvant chemotherapy has resulted in inclusion of several patients in the curative treatment plans who were otherwise incurable.^{9,10} The therapeutic advantages of liver resection for N-CRLM became increasingly recognized during the last two decades.¹¹ In selected patients, liver metastasectomy for non-colorectal non-neuroendocrine secondary tumors from the ovary, pancreas, breast, kidney and stomach may provide comparable survival rates with resection of CRLM.^{11,12} Since 2012, the surgical oncology program at Sohag University has extended the scope of clinical services to include patients with primary and metastatic liver tumors. In this study, the incidence, clinical presentation, surgical approaches and clinical outcome of surgical management of patients with CRLM will be compared to those with N-CRLM.

METHODS

Patients who underwent liver resection (April 2013-May 2017) at the Sohag University Hospital were identified. The medical records of adult (age >18 years), non-cirrhotic, non-cholestatic patients with American Society of Anesthesiologists (ASA) score of I who were treated electively by liver resection for metastatic liver neoplasms were retrieved and analysed.

Preoperative workup

Preoperative clinical evaluation comprised medical history, clinical examination and relevant laboratory work-up. A standard panel of tumor markers including carcino-embryonic antigen, alfa fetoprotein (α -FP) and carbohydrate antigen 19:9 (CA 19:9) was investigated. The levels of other tumor markers were selectively determined in specific cases. All patients were examined by ultrasonography of the liver and triphasic abdominal computed tomography (CT) and contrast enhanced chest CT. Liver metastasectomy was deemed feasible if sufficient size of future liver remnant with adequate arterial and portal inflow and hepatic venous outflow and biliary drainage could be secured. Complete tumor resection (R0) was concluded if at least one-centimetre tumor-free resection margin was microscopically proven.

Anesthesia, analgesia and surgical interventions

Analgesia was attained via epidural catheter inserted at T9-T10 level. General anesthesia was induced by

propofol and maintained with isoflurane. The same surgical team carried out consistently all liver and other visceral resection procedures. The peritoneal cavity was entered via bilateral subcostal incision. Using self-retaining abdominal retractor facilitated wide exposure and thorough exploration of the abdominal cavity. Hepatic parenchymal transection was carried out under portal triad (inflow) occlusion after clamping of hepatooduodenal ligament.

Various techniques of inflow occlusion were used (continuous occlusion, intermittent clamping, or ischemic preconditioning) consistent with intra-operative assessment of the liver parenchyma by the surgical team on case-by-case basis. Crushing of the parenchyma by small artery clamp was the standard method of parenchyma transection in all cases. Intrahepatic bile ducts and vessels measuring 3mm or more were clipped or ligated while smaller vessels were cauterized using bipolar diathermy. Hepatic veins were transected over vascular clamps and controlled by running sutures in most patients.

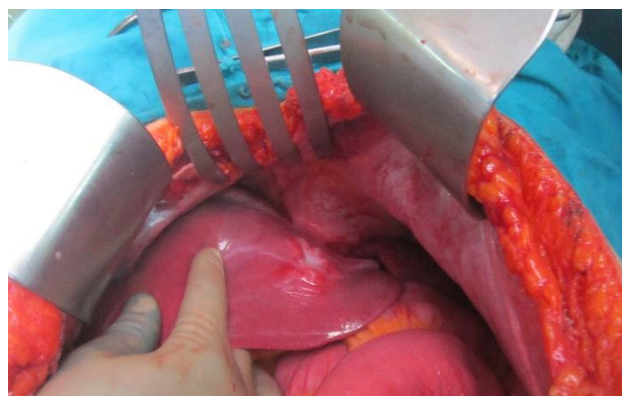


Figure 1: Metastatic right colon cancer (involving parts from segments II and III).

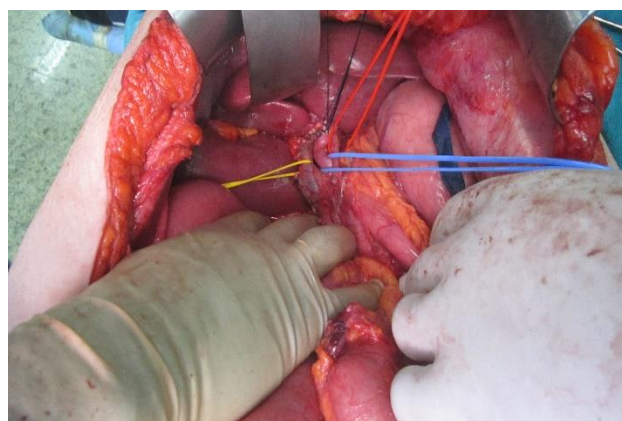


Figure 2: Hilar dissection showing the hepatic artery, portal vein and common bile duct (red, blue and yellow vessel loops, respectively).

Vascular stapler was used for transection/closure of the hepatic veins only in a few patients (Figures 1 to Figure

4). In all patients, low CVP (less than 5mm H₂O) was maintained during hepatic transection to minimize hepatic venous back flow with satisfactory urine output (at least 30ml/hour). The term multivisceral resection was assigned when liver resection was carried out with excision of the primary tumor in a single operation (excluding gall bladder cancer with liver-limited metastasis, which was considered sole liver resection due to the intimate anatomic relationship between the liver and gall bladder).

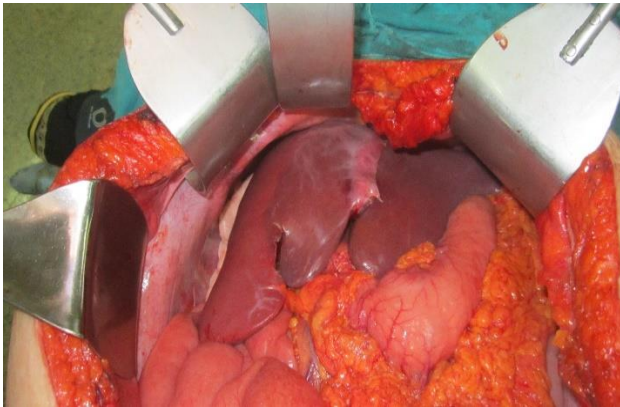

Figure 3: Ischemia of the left lobe (after control of the left hepatic artery and left portal vein).

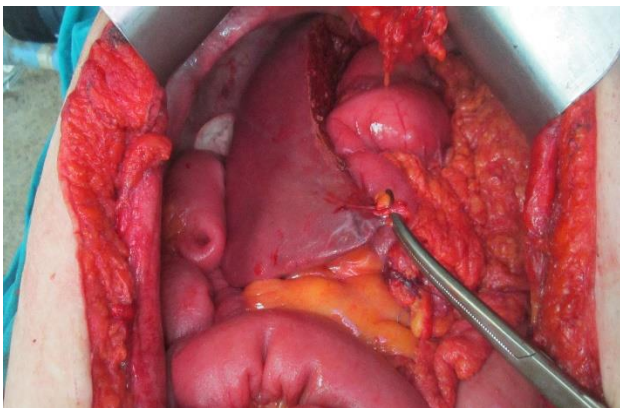


Figure 4: Anatomic left hemihepatectomy completed.

Assessment of postoperative events and statistical analysis

Postoperative complications were thoroughly registered in all patients. Surgical morbidity and mortality within the same hospital admission or during the first postoperative 30 days were considered “surgery-related”. Postoperative complications were ranked according to Clavien-Dindo classification into five grades.^{13,14} The study concluded an overall score of postoperative complications (ranging from one to seven) for each patient by allotting one point to each of grades I, II, IIIa, IIIb, IVa, IVb and V in ascending order, respectively. Statistical analysis was carried out using student's T test using Graph Pad Prism 5. Significant difference between groups was concluded if p value was <0.05.

RESULTS

Preoperative demographic and clinical data

Twenty-six patients were enrolled with median age of 52 (range: 24-74) years and slight predilection toward male gender. Indications for liver resection were metastatic malignant neoplasms which comprised CRLM (total 15, colonic origin 13, rectal origin 2) and N-CRLM (11 patients in total). The N-CRLM group included 6 metastatic gall bladders, 2 pancreatic, one breast, one lung, and one recurrent ovarian cancer. Preoperative demographic and clinical data are shown in Table 1.

Table 1: Preoperative data.

Parameter	n	%
Demographic and clinical characteristics		
Male gender	14/26	54
Smoking	11/26	42
Abdominal pain	21/26	81
Anorexia	15/26	58
Weight loss	12/26	46
Prior abdominal surgery	4/26	15
Preoperative chemotherapy (CRLM)	3/26	12
Diabetes	4/26	15
Indication for liver resection		
CRLM	15/26	58
N-CRLM	11/26	42
Timing of metastasis in relation to initial presentation		
CRLM group		
Synchronous	8/15	
Metachronous	7/15	
N-CRLM group		
Synchronous	10/11	
Metachronous	1/11	
Multidisciplinary management plans for synchronous metastasis		
CRLM group (total = 8)		
Single-stage resection	6/8	
Two-stage resection: standard approach ‘liver second’	1/8	
Two-stage resection: reverse approach ‘liver first’	1/8	
N-CRLM group (total=10)		
Single-stage resection	10/10	
Repeat ‘second’ liver resection (total = 2)		
Recurrent CRLM (1 colonic, 1 rectal)	2	

(n) number of patients, (%) percentage from total number of patients.

Surgical interventions

Operative time ranged from 180 to 420 (median: 210) minutes. Multivisceral (single-stage resection of the liver and other organ(s)) was carried out in 11 patients (6 with CRLM, 2 pancreas cancers, 1 lung cancer, 1 recurrent ovarian cancer, and 1 gall bladder cancer with

diaphragmatic mass). Operative data were shown in Table 2.

Table 2: Operative data.

Parameter	n.	%
Multivisceral (liver-other organ(s))* resection	11/26	42%
CRLM group		
Colon	5/26	19%
Rectum	1/26	4%
N-CRLM group		
Pancreas	2/26	8%
Gall bladder and diaphragm	1/26	4%
Lung and diaphragm	1/26	4%
Ovary	1/26	4%
Technique of liver parenchyma transection		
Crushing clamp	22/26	85%
Dissecting sealer	4/26	15%
Anatomic versus non-anatomic liver resection		
Anatomic resection	17/26	65%
Non-anatomic resection	9/26	35%
Extent of liver resection		
Major (≥ 3 segments)	19/26	73%
Minor (< 3 segments)	7/26	27%
Portal triad occlusion		
Continuous	2/26	8%
Intermittent	21/26	80%
Ischemic preconditioning	3/26	12%
Central venous pressure (cm/H ₂ O) [§]	4 (1-6)	
Blood loss (ml) [†]	650 (250-950)	
Red blood cell transfusion (unit) ^{§†}	2 (0-4)	

(*) synchronous metastasis (excluding gall bladder cancer with metastasis confined to the liver), (n.) number of patients, (%) percentage from total number of patients, ([§]) median (Range), ([†]) significantly lower with anatomic resection.

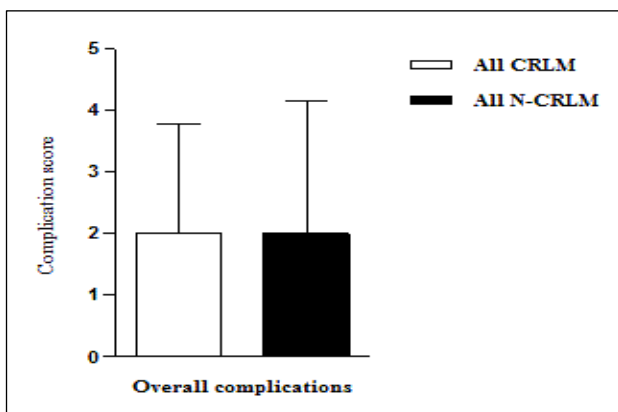


Figure 5: Complication score in CRLM versus N-CRLM.

Surgical complications

Postoperatively, grades of complications showed wide array of variations that ranged from no adverse event,

minor complications, major complications and in-hospital death. A summary of postoperative complications according to the points that we have assigned to each of Clavien-Dindo system of postoperative complications is shown in Table 3.

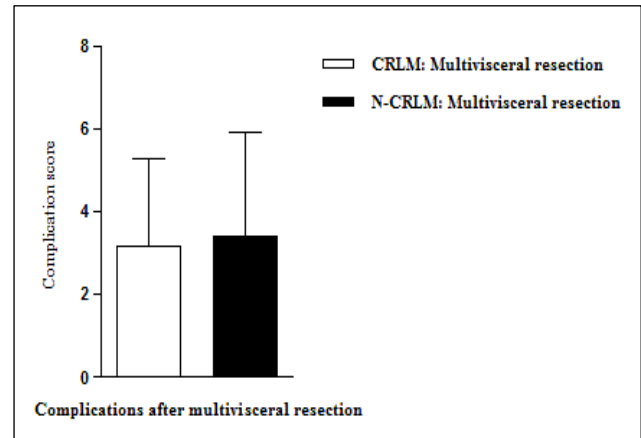


Figure 6: Complication score after multivisceral resection in CRLM versus N-CRLM.

Overall, the complication score was not significantly different between CRLM versus N-CRLM groups (Figure 5). Similarly, among CRLM patients the subgroup of multivisceral resections did not exhibit significantly different score of postoperative complications compared with N-CRLM (Figure 6).

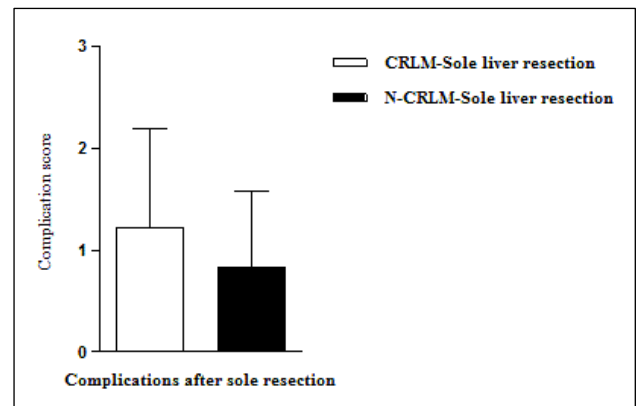


Figure 7: Complication score after sole liver resection in CRLM versus N-CRLM.

Moreover, patients who underwent sole liver resection in CRLM group were not significantly different with regard to postoperative complication score in comparison with those in the N-CRLM group (Figure 7).

However, further subgroup analysis demonstrated that multivisceral resection was associated with increased postoperative complication score compared with sole liver resection in both CRLM and N-CRLM groups (Figures 8 and 9).

Impact of systemic factors on postoperative complications

Patients with age more than 70 years (three patients) exhibited higher score of postoperative complications

(median 5; range 3-7) compared with younger patients (median, 3; range 1-7), $p < 0.001$. The origin of primary tumor (colon/rectum versus other organs), diabetes and preoperative chemotherapy were not associated with significant increase in morbidity.

Table 3: Postoperative complications.

Description of the highest postoperative complication (treatment, intervention)	Complication grade	Complication score
Group 1: Colorectal liver metastasis (CRLM)		
Wound infection (opening at bedside)	I	1
Intra-abdominal bleeding (re-laparotomy)	IIIb	4
Hypoalbuminemia (transfusion of fresh frozen plasma)	II	2
Respiratory tract infection (antibiotics)	II	2
Intra-abdominal abscess (drainage)	IIIa	3
Death due to duodenal leak and sepsis	V	7
Wound infection (opening at bedside)	I	1
None	None	0
Wound infection (opening at bedside)	I	1
Prolonged ileus (medical treatment)	I	1
Anemia (transfusion of packed RBCs)	II	2
Anemia (transfusion of packed RBCs)	II	2
Wound infection (opening at bedside)	I	1
None	None	0
Drainage of biloma	IIIa	3
Group 2: Non-colorectal liver metastasis (N-CRLM)		
Repeated vomiting (antiemetics)	I	1
Anemia (transfusion of packed RBCs)	II	2
Respiratory failure (mechanical ventilation in ICU)	IVb	5
Hypoalbuminemia (transfusion of fresh frozen plasma)	II	2
Death due to respiratory failure and sepsis	V	7
None	None	0
Prolonged ileus (medical treatment)	I	1
Wound infection (opening at bedside)	I	1
None	None	0
Prolonged ileus (medical treatment)	I	1
Respiratory tract infection (antibiotics)	II	2

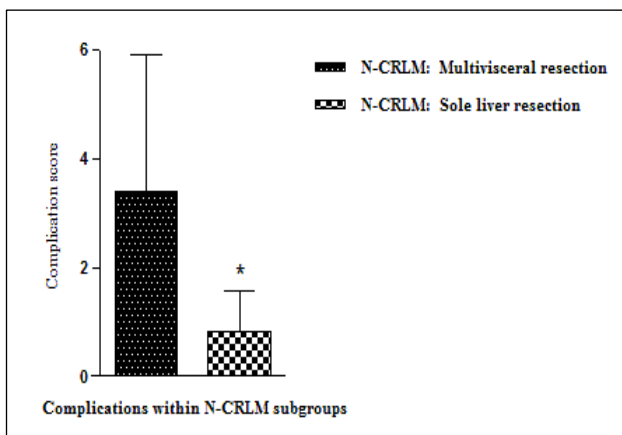


Figure 8: Complication score after multivisceral versus sole liver resection in N-CRLM group.

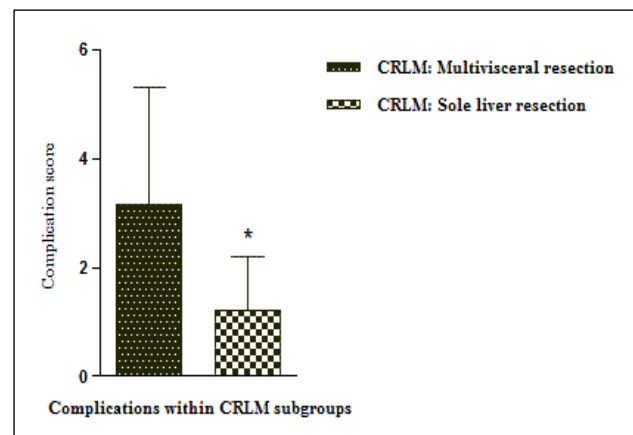


Figure 9: Complication score after multivisceral versus sole liver resection in CRLM group.

Early postoperative mortality

Two patients died within the first 30 days postoperatively. One patient was 42-year-old male who died on day 25, after multivisceral resection for CRLM (liver bisegmentectomy, extended right hemicolectomy, and right nephrectomy) due to sepsis following anastomotic leak. The other N-CRLM patient (73-year-old male) died after multivisceral resection (liver bisegmentectomy, right lower lung lobectomy and excision with mesh repair of the diaphragm) on postoperative day 9 due to severe sepsis and multiple organ failure.

Survival

After a mean follow up of 32 (range: 6-50) month, 12 patients out of 16 were alive in CRLM group compared with 7 out of 11 in the N-CRLM group. The reduced overall survival rate among N-CRLM compared with CRLM patients (64% versus 75%, respectively) was related to recurrent disease and complications of chemotherapy.

DISCUSSION

This study provides a comprehensive analysis on the clinical presentation, surgical management, complications and mortality after liver resection for CRLM compared with N-CRLM at a single center in Southern Egypt.

Overall, twenty-six patients with diverse types of metastatic liver neoplasms were surgically treated with curative intent. There was no remarkable difference regarding the incidence of liver metastasis in males compared with females. The number of patients who were eligible for liver metastasectomy due to distant spread of malignant colonic and rectal neoplasms was higher than that of patients with metastatic cancers originating from other organs. More than one fourth of our patients were smokers. Abdominal pain, anorexia and weight loss were the predominant symptoms associated with liver metastasis. The rates of synchronous (8/15) versus metachronous (7/15) metastasis were comparable in the CRLM group. In sharp contrast, synchronous metastasis was found in almost all cases (10/11) of N-CRLM (from gall bladder, pancreas, lung, and ovary) except one patient with metachronous metastasis from breast cancer.

We offered the majority of patients with N-CRLM the option of curative surgery if, in addition to other surgical and medical prerequisites, the secondary tumors were confined to the liver.¹⁵ Metastatic gall bladder carcinoma was the most frequent variety among N-CRLM patients. Preoperative imaging failed to recognize metastasis to the peritoneal lining of the right side of the diaphragm in one patient who underwent radical resection of the gall bladder, liver metastases and right hemi-diaphragm. Of note, gall bladder cancer is usually diagnosed at advanced

stage due to aggressive biological features and incompetence of screening test.¹⁶

Simultaneous pancreatico-duodenectomy (Whipple procedure) and resection of liver metastasis from pancreatic head cancer was reported to be not associated with increased postoperative complications.¹⁷ We reported on two cases of pancreatico-duodenectomy and segmental liver resection owing to uncertain diagnosis by preoperative imaging and lack of intra-operative frozen section biopsy. In both patients, pancreatic metastasis was confirmed on postoperative histopathological examination. The option of liver metastasectomy in two cases of N-CRLM (breast and recurrent ovarian cancer) was supported by the relatively long interval between resection of the primary tumor and the appearance of liver metastasis in the former and the concurrent tumor recurrence and liver metastasis, in the later case. Both varieties were reported to be associated with long term survival after liver resection.¹⁸

Reports on liver resection from lung metastasis remain scarce. In a study on the relation between survival rates and specific organ metastasis from lung cancer, Tamura et al demonstrated that liver metastasis was associated with unfavourable prognosis.¹⁹ However, long term survival after liver resection for metachronous metastasis from lung cancer were reported.^{20,21} We performed multivisceral resection in an elderly patient with locally-advanced lung cancer (that involved the diaphragm and liver segment VII). Postoperatively, liver functions were normalized on postoperative day 5, however sepsis following severe respiratory tract infection was the direct cause of postoperative death.

We considered different plans for tackling synchronous CRLM including standard "primary-first", combined (liver-visceral) and reverse "liver-first" approaches.⁸ However, most of patients with synchronous CRLM underwent combined resection due to the relatively small number of metastatic deposits which justified the option of upfront liver resection without neo-adjuvant therapy.²² This strategy conforms with the current guidelines which allow combined resections if liver metastasectomy is deemed easy due to low burden of metastasis.²³ The "primary first" approach was applied in one patient with symptomatic colon cancer and multiple metastatic deposits in the liver. Postoperative chemotherapy has successfully downsized the diameter and number of liver metastases and therefore enabled sufficient future liver volume after metastasectomy. A beneficial downsizing effect of chemotherapy in similar situation has been previously recommended.^{23,24} The reverse "liver first" strategy was applied in one patient with asymptomatic rectal adenocarcinoma to provide opportunity to eradicate the rapidly growing metastasis prior to neoadjuvant therapy for the primary tumor.^{24,25}

In this study, the term multivisceral resection denoted combined resection of the primary and metastatic liver

cancer. We applied this descriptive definition on all patients with single stage liver-visceral resections except five patients with metastatic gall bladder cancer which was confined to the liver (due to the close anatomical location of the gall bladder to the liver). Multivisceral resection was carried out in almost 50% of patients with N-CRLM compared with slightly more than one third of patients with CRLM. Published data on the results of combined liver-visceral resections on the severity of postoperative complications are contradictory.²⁶⁻²⁸ In this study, patients who underwent multivisceral resections exhibited higher grades of postoperative complications compared with those who had sole liver resection. However, no significant difference could be documented between subgroups of patients in CRLM versus N-CRLM groups who underwent multivisceral resection. Previous studies showed increased surgical complications in the setting of combined versus staged resection of CRLM particularly if major liver resection is performed.^{8,29}

Advanced age was regarded as risk factor for increased postoperative complications following liver resection.³⁰ Among our patients, we had only three patients who were aged over seventy years. Compared with the remaining patients, this subgroup was fragile and showed remarkably higher score of postoperative complications. However, we could not document a negative effect of diabetes or preoperative chemotherapy. These finding should be considered with caution due to the heterogeneity and relatively small number of patient subgroups. During a mean follow-up of 32 (range: 6-50) months, overall survival was 75% (3 patients died) in CRLM compared with 64% (4 patients died) in N-CRLM group. Decreased survival in the later group was related to disease recurrence and side effects of chemotherapy. Previous reports demonstrated longer survival after liver resection for CRLM compared with N-CRLM, however our results should be interpreted with caution due to the relatively small number of patients and short follow-up.^{31,32}

CONCLUSION

In conclusion, our results demonstrate that liver resection can be safely accomplished in CRLM and N-CRLM patients. Multivisceral resections and advanced age were associated with increased severity of postoperative complications regardless the location of primary neoplasm.

Funding: No funding sources

Conflict of interest: None declared

Ethical approval: The study was approved by the Institutional Ethics Committee

REFERENCES

1. Al Bandar MH, Kim NK. Current status and future perspectives on treatment of liver metastasis in

- colorectal cancer (Review). *Oncol Rep.* 2017;37(5):2553-64.
2. Takemura N, Saiura A. Role of surgical resection for non-colorectal non-neuroendocrine liver metastases. *World J Hepatol.* 2017;9(5):242-51.
3. Torzilli G, Adam R, Viganò L, Imai K, Goransky J, Fontana A, et al. Surgery of Colorectal Liver Metastases: Pushing the Limits. *Liver Cancer.* 2016;6(1):80-9.
4. Aragon RJ, Solomon NL. Techniques of hepatic resection. *J Gastrointest Oncol.* 2012;3(1):28-40.
5. Moggia E, Rouse B, Simillis C, Li T, Vaughan J, Davidson BR, et al. Methods to decrease blood loss during liver resection: a network meta-analysis. *Cochrane Database Syst Rev.* 2016;10:CD010683.
6. Feng QY, Wei Y, Chen JW, Chang WJ, Ye LC, Zhu DX, et al. Anti-EGFR and anti-VEGF agents: important targeted therapies of colorectal liver metastases. *World J Gastroenterol.* 2014;20(15):4263-75.
7. Veen T, Søreide K. Can molecular biomarkers replace a clinical risk score for resectable colorectal liver metastasis? *World J Gastrointest Oncol.* 2017;9(3):98-104.
8. Ihnát P, Vávra P, Zonča P. Treatment strategies for colorectal carcinoma with synchronous liver metastases: Which way to go? *World J Gastroenterol.* 2015;21(22):7014-21.
9. Samaras P, Breitenstein S, Haile SR, Stenner-Liewen F, Heinrich S, Feilchenfeldt J, et al. Selective intra-arterial chemotherapy with floxuridine as second- or third-line approach in patients with unresectable colorectal liver metastases. *Ann Surg Oncol.* 2011;18(7):1924-31.
10. Wang CC, Li J. An update on chemotherapy of colorectal liver metastases. *World J Gastroenterol.* 2012;18(1):25-33.
11. Gandy RC, Bergamin PA, Haghighi KS. Hepatic resection of non-colorectal non-endocrine liver metastases. *ANZ J Surg.* 2017;87(10):810-4.
12. Clarke NAR, Kanhere HA, Trochsler MI, Maddern GJ. Liver resection for non-colorectal non-neuroendocrine metastases. *ANZ J Surg.* 2016.
13. Dindo D, Demartines N, Clavien P-A. Classification of Surgical Complications. *Ann Surg.* 2004;240(2):205-13.
14. Clavien PA, Barkun J, de Oliveira ML, Vauthey JN, Dindo D, Schulick RD, et al. The Clavien-Dindo classification of surgical complications: five-year experience. *Ann Surg.* 2009;250(2):187-96.
15. Schiergens TS, Lüning J, Renz BW, Thomas M, Pratschke S, Feng H, et al. Liver resection for non-colorectal non-neuroendocrine metastases: where do we stand today compared to colorectal cancer? *J Gastrointest Surg Off J Soc Surg Aliment Tract.* 2016;20(6):1163-72.
16. Kanthan R, Senger JL, Ahmed S, Kanthan SC. Gallbladder Cancer in the 21st Century. *J Oncol.* 2015. Available at

- <http://www.ncbi.nlm.nih.gov/pmc/articles/PMC4569807/>. Accessed 3 September 2017.
17. Shi HJ, Jin C, Fu DL. Preoperative evaluation of pancreatic ductal adenocarcinoma with synchronous liver metastasis: Diagnosis and assessment of unresectability. *World J Gastroenterol*. 2016;22(45):10024-37.
 18. Fitzgerald TL, Brinkley J, Banks S, Vohra N, Englert ZP, Zervos EE. The benefits of liver resection for non-colorectal, non-neuroendocrine liver metastases: a systematic review. *Langenbecks Arch Surg*. 2014;399(8):989-1000.
 19. Tamura T, Kurishima K, Nakazawa K, Kagohashi K, Ishikawa H, Satoh H, et al. Specific organ metastases and survival in metastatic non-small-cell lung cancer. *Mol Clin Oncol*. 2015;3(1):217-21.
 20. Di Carlo I, Grasso G, Patane' D, Russello D, Latteri F. Liver metastases from lung cancer: is surgical resection justified? *Ann Thorac Surg*. 2003;76(1):291-3.
 21. Nagashima A, Abe Y, Yamada S, Nakagawa M, Yoshimatsu T. Long-term survival after surgical resection of liver metastasis from lung cancer. *Jpn J Thorac Cardiovasc Surg*. 2004;52(6):311-3.
 22. de Haas RJ, Adam R, Wicherts DA, Azoulay D, Bismuth H, Vibert E, et al. Comparison of simultaneous or delayed liver surgery for limited synchronous colorectal metastases. *Br J Surg*. 2010;97(8):1279-89.
 23. Adam R, de Gramont A, Figueras J, Kokudo N, Kunstlinger F, Loyer E, et al. Managing synchronous liver metastases from colorectal cancer: a multidisciplinary international consensus. *Cancer Treat Rev*. 2015;41(9):729-41.
 24. Lam VWT, Laurence JM, Pang T, Johnston E, Hollands MJ, Pleass HCC, et al. A systematic review of a liver-first approach in patients with colorectal cancer and synchronous colorectal liver metastases. *HPB*. 2014;16(2):101-8.
 25. Ali SM, Pawlik TM, Rodriguez-Bigas MA, Monson JRT, Chang GJ, Larson DW. Timing of Surgical Resection for Curative Colorectal Cancer with Liver Metastasis. *Ann Surg Oncol*. 2017;1-6.
 26. Khan K, Wale A, Brown G, Chau I. Colorectal cancer with liver metastases: Neoadjuvant chemotherapy, surgical resection first or palliation alone? *World J Gastroenterol WJG*. 2014;20(35):12391-406.
 27. Abelson JS, Michelassi F, Sun T, Mao J, Milsom J, Samstein B, et al. Simultaneous Resection for Synchronous Colorectal Liver Metastasis: the New Standard of Care? *J Gastrointest Surg Off J Soc Surg Aliment Tract*. 2017;21(6):975-82.
 28. Inoue Y, Imai Y, Osumi W, Shimizu T, Asakuma M, Hirokawa F, et al. What is the optimal timing for liver surgery of resectable synchronous liver metastases from colorectal cancer? *Am Surg*. 2017;83(1):45-53.
 29. Fahy BN, Fischer CP. Synchronous resection of colorectal primary and hepatic metastasis. *J Gastrointest Oncol*. 2012;3(1):48-58.
 30. Sulpice L, Rayar M, Campillo B, Pery C, Guillaud A, Meunier B, et al. Advanced age remains an achilles heel for liver resections. *World J Surg*. 2014;38(4):918-26.
 31. Kanas GP, Taylor A, Primrose JN, Langeberg WJ, Kelsh MA, Mowat FS, et al. Survival after liver resection in metastatic colorectal cancer: review and meta-analysis of prognostic factors. *Clin Epidemiol*. 2012;4:283-301.
 32. Maeda Y, Shinohara T, Katayama T, Futakawa N, Hamada T. Hepatectomy for liver metastases in non-colorectal, non-neuroendocrine cancer patients. The survival benefit in primary unresectable cases. *Int J Surg*. 2015;22:136-42.

Cite this article as: El-Badry AM, Abdelraheem O. Clinical outcome after liver resection for colorectal versus non-colorectal metastasis: a comparative study. *Int Surg J* 2018;5:390-7.