

## Case Report

# Imaging features of superior mesenteric artery syndrome: a rare vascular compression disorder

Naina Suresh\*, Murali Nanjundan, Sundari Natarajan, Subhashree Chandrasekaran

Department of Radio diagnosis, Coimbatore Medical College Hospital, Coimbatore, Tamilnadu, India

**Received:** 29 January 2016

**Revised:** 01 February 2016

**Accepted:** 29 February 2016

### \*Correspondence:

Dr. Naina Suresh,

E-mail: [nainasuresh88@gmail.com](mailto:nainasuresh88@gmail.com)

**Copyright:** © the author(s), publisher and licensee Medip Academy. This is an open-access article distributed under the terms of the Creative Commons Attribution Non-Commercial License, which permits unrestricted non-commercial use, distribution, and reproduction in any medium, provided the original work is properly cited.

## ABSTRACT

Superior mesenteric artery (SMA) syndrome is an extremely rare acquired vascular compression disorder with a prevalence of around 0.1-0.3%. The transverse or D3 segment of the duodenum crosses between the aorta and SMA between the Aortomesentric angle (AMA) maintained by the retroperitoneal fat. Various clinical scenarios causing reduction in the AMA make the patient vulnerable to the syndrome. Two young female patients referred to the emergency department with history of abdominal pain and vomiting were imaged with ultrasonography and Contrast enhanced Computed Tomogram (CT) of the abdomen and pelvis with CT abdominal angiography. The Aortomesentric angle (AMA) on sagittal MPR MIP images and the Aortomesentric distance (AMD) on axial images was calculated. Both the patients had similar imaging findings which included gross dilatation of the stomach with circumferential gastric wall thinning and gastric rugal flattening, dilated duodenum upto the transverse or D3 segment with abrupt narrowing of the third part of duodenum at the level of SMA crossing. The AMD calculated on axial images between the SMA anteriorly and the aorta posteriorly at the point where the duodenum crosses the aorta and the AMA calculated on sagittal MPR MIP images were reduced. SMA syndrome is a rare acquired vascular compression disorder due to decreased AMA due a myriad of clinical scenarios. Multidetector CT with angiography is the imaging modality of choice. Ultrasonography and upper gastrointestinal barium studies serve as additional diagnostic tools. Initial treatment is conservative with fluid and electrolyte resuscitation. The surgical option of choice is laparoscopic Duodenojejunostomy.

**Keywords:** SMA syndrome, Aortomesentric angle, Aortomesentric distance, Vascular compression syndrome

## INTRODUCTION

SMA syndrome is an extremely rare acquired vascular compression disorder. It was originally described by Rokitsky.<sup>1</sup> It is synonymously called as Cast syndrome/Arterio mesenteric duodenal compression syndrome/Wilkie's syndrome due to the phenomenal contribution by Wikie by publishing the largest case series based on 75 cases.<sup>1</sup> The disorder has an extreme rare occurrence with only 400 cases described in literature with a prevalence of around 0.1-0.3%.<sup>2</sup>

The SMA forms an angle with the aorta called the Aorto mesentric angle (AMA). The transverse or D3 segment of the duodenum crosses between the aorta and the proximal SMA at the L3 level and is surrounded by retroperitoneal fat which provides a "cushion" for the duodenum maintaining the AMA.<sup>1-3</sup> Various clinical scenarios predispose the patient to the syndrome due to reduction of the AMA.

## METHODS

Two patients presenting to the emergency department were evaluated.

### **Patient 1**

A twenty year old female presented to the emergency department at Coimbatore Medical College Hospital with history of abdominal pain for duration of 1 week, associated with bilious vomiting and low grade fever. The abdominal pain was localized to the epigastrium & periumbilical region and was aggravated on lying supine. The patient had normal bowel and bladder habits and menstrual history.

The patient gave a past history of similar complaints requiring hospitalization elsewhere two years back. The patient was not evaluated in detail, was managed conservatively & discharged. The patient sustained a road traffic accident at the age of eight years and underwent bilateral lower limb amputation (left-below knee and right-syme's amputation). She has also been on irregular treatment for peptic ulcer disease for the past 5 years.

### **Patient 2**

An eighteen year old female presented with history of abdominal pain and non-bilious vomiting to the emergency department of Coimbatore Medical College Hospital for duration of 1 week.

The patient had nil significant past history.

## **RESULTS**

### **Patient 1**

#### *Physical examination*

The patient was extremely asthenic (Body weight-38 kgs) She was pale. Systemic examination revealed minimal epigastric tenderness with no palpable mass per abdomen. Rest of the systems were within normal limits.

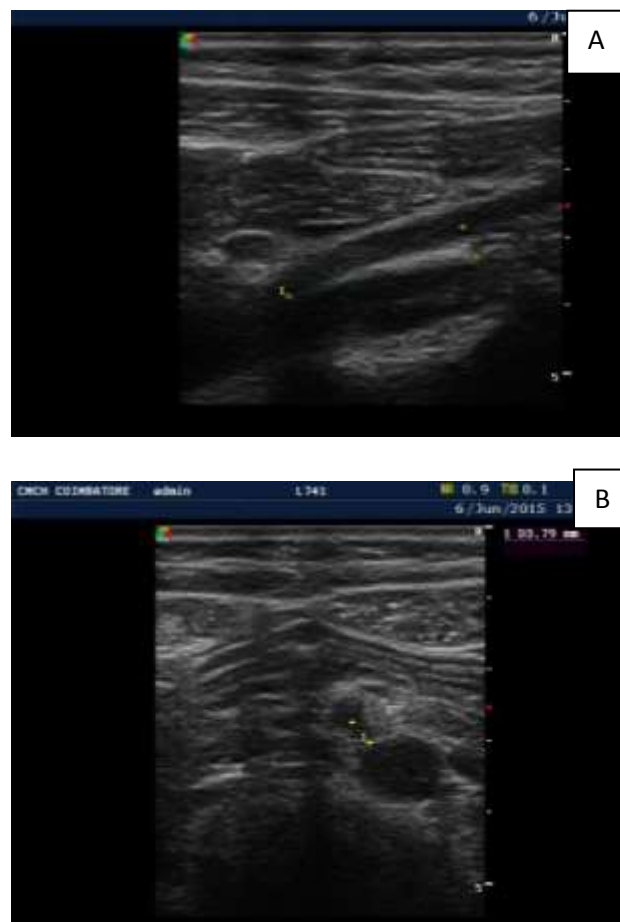#### *Laboratory workup*

Complete hemogram revealed a picture of nutritional anaemia (Hemoglobin 9g/dL, RBC  $3.97 \times 10^6/\text{mm}^3$ , MCV – 76.3 fL). Other laboratory Investigations including renal function tests, liver function tests, serum electrolytes, ECG and chest X-Ray were within normal limits.

#### *Imaging workup*

Patient was referred to the Department of Radiodiagnosis for an imaging work up. A sonographic evaluation of the abdomen & pelvis was done which revealed the following findings; grossly dilated stomach and proximal duodenum with collapsed distal bowel loops. Acute angulation of the Superior mesenteric artery (SMA) with relation to the aorta was also noted. There was no free fluid in the peritoneal cavity and the rest of

the abdominal organs were within normal limits (Figure 1).



**Figure 1: Grey scale abdominal sonographic image at the level of origin of SMA from the AA.**

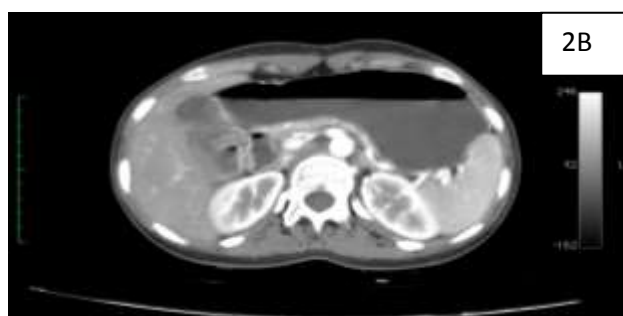
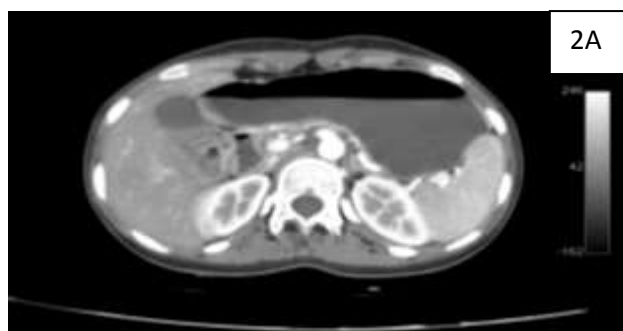
**A: Longitudinal section at the level of the origin of SMA from the aorta with narrow AMA.**

**B: Transverse section at the level of SMA and aorta revealing decreased AMD (SMA superior mesenteric artery; AA abdominal aorta; AMA aortomesentric angle; AMD aortomesentric distance).**

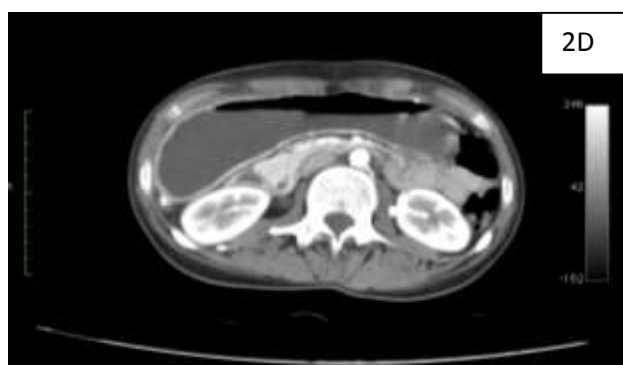
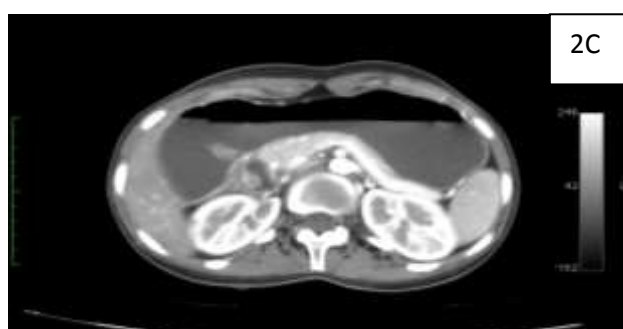
The patient was then referred for a Computed Tomogram (CT) of the Abdomen & Pelvis with CT abdominal angiography in view of a vascular compression disorder. The scanning was performed on a 'Toshiba' Multislice helical Scanner-'Alexion' model TSX-033A.

With intravenous iodinated contrast administration and oral water the patient underwent the scanning uneventfully.

The following findings were observed; the stomach showed gross dilatation with circumferential gastric wall thinning and gastric rugal flattening, dilated duodenum upto the transverse or D3 segment. The third part of the duodenum showed abrupt narrowing at the level of SMA crossing (Figure 2).



**Figure 2: Axial contrast enhanced computed tomogram (intravenous contrast and oral water) images. A: Grossly dilated fluid filled stomach with circumferential wall thinning and rugal flattening B: section caudal to the figure 2a reveals grossly distended stomach.**



**Figure 2: Axial contrast enhanced computed tomogram (intravenous contrast and oral water) images. C: Gross gastric and duodenal dilatation upto the transverse/d3 segment. D: Abrupt narrowing of the duodenum at the level of SMA crossing (SMA superior mesenteric artery).**

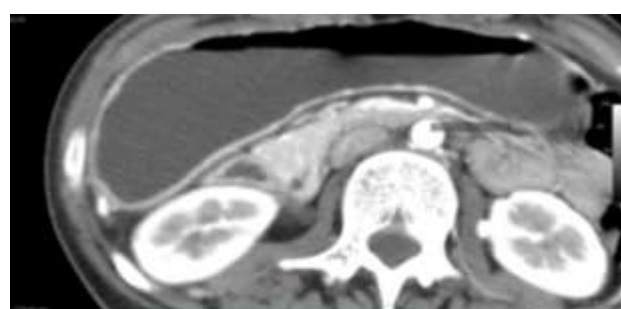
CT Abdominal angiography revealed abnormally acute angulation of the SMA with a decreased Aorta-SMA distance. The Aorta-SMA distance called as the aortomesentric distance (AMD) was calculated on axial images between the SMA anteriorly & the Aorta posteriorly at the point where the duodenum crosses the aorta. The angle between the Aorta & the SMA was calculated as the aortomesentric angle (AMA) on sagittal MPR MIP images. The AMD & AMA measured 4mm and 130 respectively (Figure 3,4)

#### *Upper gastrointestinal barium study*

The patient underwent an upper gastrointestinal barium study which revealed grossly contrast distended stomach & proximal duodenum with trickle of contrast into the distal bowel indicating partial obstruction (Figure 5).



**Figure 3: CT Abdominal angiography, sagittal MPR MIP images at the origin of the SMA from the AA. A: Reduced AMA between the AA and the SMA, the AMA measured 13 degrees. B: Zoomed view of image a showing reduced AMA. (SMA superior mesenteric artery; AA abdominal aorta; AMA aortomesentric angle).**



**Figure 4: CT abdominal angiography axial image at the level of SMA and AA.**

AMD calculated between the SMA anteriorly & the AA posteriorly at the point where the duodenum crosses the AA, AMD measures 4 mm

(SMA Superior Mesenteric Artery; AA Abdominal aorta; AMD Aortomesentric distance)

#### *Upper gastrointestinal endoscopy*

Upper Gastrointestinal endoscopy revealed findings of pangastritis with mucosal breaks seen involving fundus, body & antrum.

With the above findings of pronounced gastric & duodenal dilatation upto its third segment with acute angulation of the SMA, reduced AMD & narrow AMA, collapsed distal bowel loops in an asthenic young female with no other cause of extrinsic duodenal compression – a diagnosis of SMA syndrome was made.

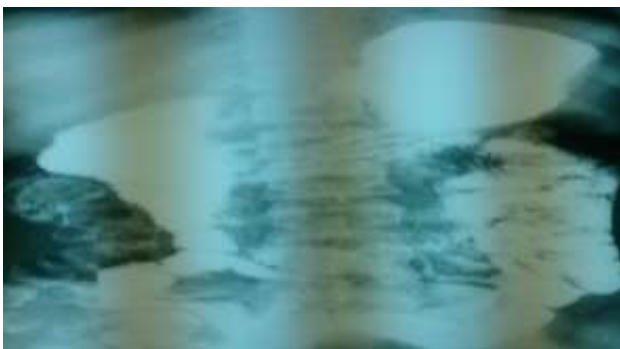#### **Patient 2**

Laboratory Workup: Within Normal Limits

#### *Imaging Workup*

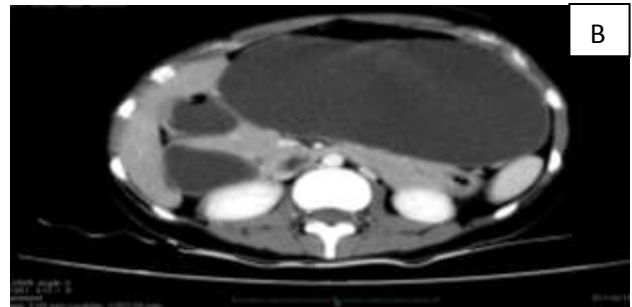
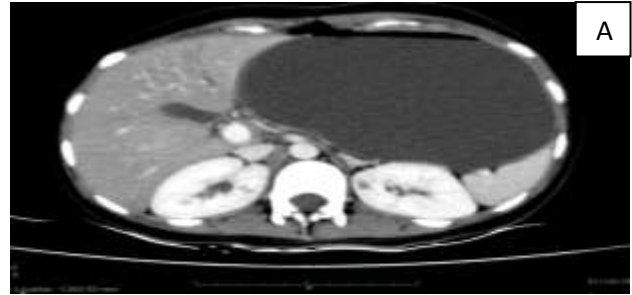The patient was referred to the Department of Radiodiagnosis for a Computed Tomogram (CT) of the Abdomen & Pelvis with CT abdominal angiography in view of a vascular compression disorder.

Contrast enhanced CT with Intravenous iodinated contrast and oral water was performed uneventfully, axial and coronal reformed images were obtained. The findings were as follows; gross dilatation of the stomach and proximal duodenum. There was circumferential gastric wall thinning & gastric rugal flattening with dilated duodenum upto the transverse or D3 segment. The third part of the duodenum showed abrupt narrowing at the level of SMA crossing (Figure 6, 7, 8).

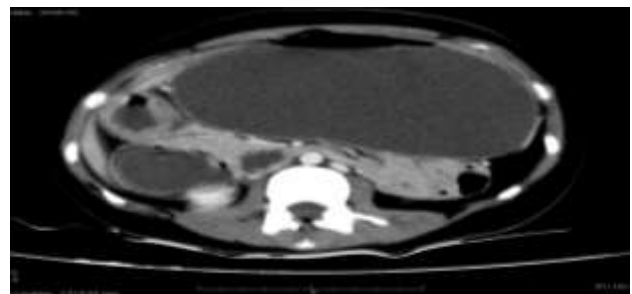


**Figure 5: Upper gastrointestinal barium study (supine).**

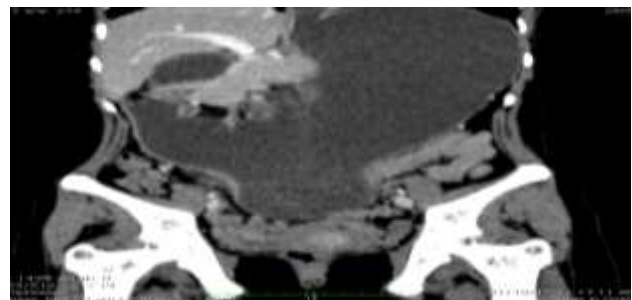
Contrast distended stomach and proximal duodenum, Trickle of contrast into the distal bowel noted indicating partial obstruction, no extrinsic impression seen



**Figure 6: Axial contrast enhanced computed tomogram (intravenous contrast and oral water) images. A: Stomach distended with water, gross gastric dilatation with circumferential gastric wall thinning and gastric rugal flattening; B: Section Caudal to the figure 6A reveals stomach distended with water with gastric dilatation.**

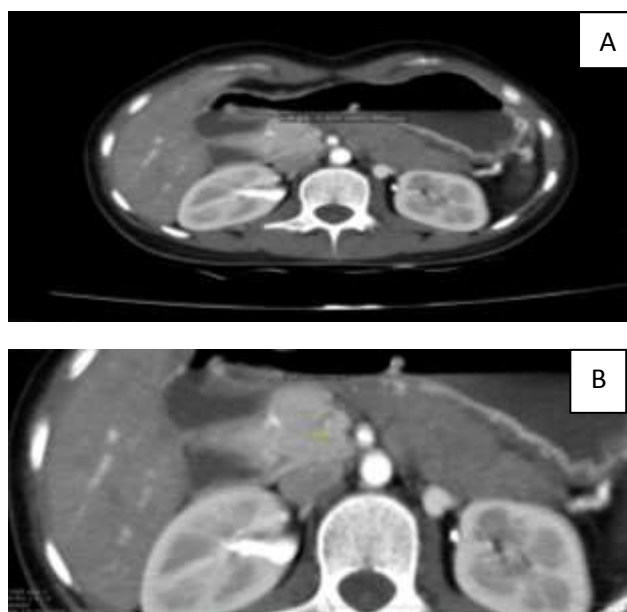


**Figure 7: Axial contrast enhanced computed tomogram (intravenous contrast and oral water) images. Gross duodenal dilatation up to the transverse or D3 segment with abrupt narrowing of the duodenum at the level of SMA crossing. (SMA superior mesenteric artery).**



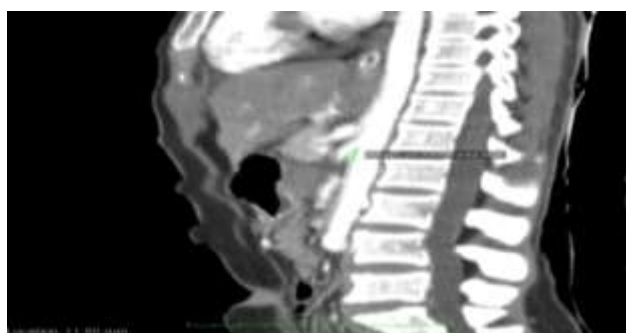
**Figure 8: Contrast enhanced Computed Tomogram Coronal reformed image. Gross gastric and duodenal dilatation with collapsed distal bowel loops.**





**Figure 9: CT abdominal angiography axial images at the level of SMA and AA. A: AMD calculated between the SMA anteriorly & the AA posteriorly at the point where the duodenum crosses the AA, AMD measures 4.1 mm; B: Zoomed view of image A showing reduced AMD. (SMA Superior Mesenteric Artery; AA Abdominal aorta; AMD Aortomesentric distance)**

CT Abdominal angiography revealed abnormally acute angulation of the SMA with a decreased Aorta-SMA distance. The aortomesentric distance (AMD) on axial images and the aortomesentric angle (AMA) on sagittal MPR MIP images was calculated. The AMD & AMA measured 4.1 mm and 200 respectively (Figure 9, 10).



**Figure 10: CT abdominal angiography, sagittal MPR MIP images at the origin of the SMA from the AA reduced AMA between the AA and the SMA, the AMA measured 20 degrees (SMA superior mesenteric artery; AA abdominal aorta; AMA aortomesentric angle).**

With the above findings of gastric & proximal duodenal dilatation up to its third segment with acute angulation of the SMA, reduced AMD & narrow AMA, collapsed distal bowel loops in a young female with no other obvious cause of extrinsic duodenal compression-a diagnosis of SMA syndrome was made.

## DISCUSSION

SMA syndrome is an extremely rare acquired vascular compression disorder. It was originally described by Rokitsansky.<sup>1</sup> It is synonymously called as Cast syndrome/Arterio mesenteric duodenal compression syndrome/Wilkie's syndrome due to the phenomenal contribution by Wikie by publishing the largest case series based on 75 cases.<sup>1</sup> The disorder has an extreme rare occurrence with only 400 cases described in literature with a prevalence of around 0.1-0.3%.<sup>2</sup>

### Etiopathogenesis

The SMA is a direct branch of the abdominal aorta at the L1-L2 level. It courses anteriorly & inferiorly forming an angle with the aorta called the Aorto mesentric angle (AMA).<sup>1</sup> The transverse segment or D3 segment of the duodenum crosses between the aorta & the proximal SMA at approximately the L3 level<sup>1</sup> and is surrounded by retroperitoneal fat which provides a "cushion" for the duodenum maintaining the AMA.<sup>1,2</sup>

### Clinical Scenario's

The following clinical scenario's should raise a suspicion to diagnose SMA syndrome. Constitutional factors viz., individuals with a thin body habitus, exaggerated lumbar lordosis and abdominal wall laxity.<sup>1-3</sup> Any cause of rapid and severe weight loss causing depletion of mesenteric fat thereby reducing the AMA viz., hypercatabolic states including cancer cachexia, burns, trauma, surgery, anorexia nervosa and malabsorption states.<sup>1,2</sup> Various spinal deformities and trauma due to increased mesenteric tension on the AMA and those on body/hip spica cast due to external abdominal compression are also predisposed to the above disorder. Anatomic anomalies like abnormally high and fixed position of the ligament of treitz or an unusually low origin of the SMA.<sup>1,2</sup> Unusual causes of the syndrome include traumatic aneurysms of the SMA, abdominal aortic aneurysms and familial, neonatal or recurrent variants of the syndrome.<sup>1</sup>

### Clinical Presentation

The disorder is common in females from the first to fourth decade. The patients can present with post prandial epigastric pain & fullness, nausea, vomiting, weight loss and anorexia causing a self-perpetuating viscous cycle of further weight loss & mesenteric fat depletion.<sup>1,2,3</sup> The symptoms seem to be typically relieved when the patient is in the left lateral decubitus, prone or knee chest position as these maneuvers are thought to reduce the small bowel mesenteric tension at the AMA and are aggravated in the supine position.<sup>1,2</sup>

The disorder is associated with peptic ulcer disease in 25-45% of the patients.<sup>1</sup>

## Imaging Workup

The traditional imaging methods for diagnosis included a combination of upper gastrointestinal barium study and a conventional mesenteric angiography for evaluation of the gastro intestinal tract & vascular anatomy.<sup>1-4</sup>

### Upper GI barium study

The study reveals findings of a dilated stomach & proximal duodenum with delayed gastroduodenal emptying and antiperistaltic waves proximal to the obstruction rarely, an extrinsic vertical impression on the third portion of the duodenum due to its compression by the SMA can be visualized. There is relief of obstruction with postural change to the left lateral decubitus, prone or knee chest position. In severe cases, barium may fail to pass through the obstructed duodenum.<sup>1,2</sup>

### Role of MDCT

Computed Tomography is the diagnostic modality of choice as it allows simultaneous evaluation of the mesoaoartic vascular anatomy and gastrointestinal evaluation in terms of transverse duodenal compression and proximal dilatation. It also aids to exclude other causes of duodenal obstruction.<sup>1-3,5</sup>

It is best performed in the late angiographic phase to allow simultaneous depiction of the vascular anatomy & the bowel wall morphology.

The use of positive oral contrast agents may be avoided in patients with severe obstruction. In addition sagittal MPR images are needed to evaluate the AMA.<sup>1-3,6</sup>

CT shows dilated stomach and duodenum up to the transverse or D3 segment. An accepted cut off to suggest duodenal dilatation would be a duodenal diameter of more than 3 cm. There are no such values suggested for gastric dilatation, hence one should look for indirect signs such as gastric rugal fattening, circumferential gastric wall thinning and visualization of the gastric antrum at the level of the portal hilus anterosuperior to the main portal vein.<sup>1,-3,5,6</sup>

### Measurements

The AMA should be measured on sagittal MPR MIP images and the diagnostic range for SMA syndrome falls within 6-22° (Normal AMA : 28° - 65°) Axial images at the level of duodenal crossing of the aorta are needed to compute the AMD and the diagnostic range for the syndrome is 2-8 mm (Normal 10-34 mm).<sup>1-3,5</sup>

### Upper GI Scopy

Upper GI endoscopy helps exclude mechanical causes of duodenal obstruction. It is also used as an adjunct to sonography in diagnosing the disorder in children.<sup>3</sup>

## Abdominal ultrasonography

Useful in the acute setting to demonstrate gastric and duodenal dilatation and to measure the angle of the superior mesenteric artery and the aortomesenteric distance. When combined with endoscopy, this may offer as an alternative way to diagnose superior mesenteric artery syndrome in children to avoid other tests with a risk of radiation exposure.<sup>4,6</sup>

## Differential Diagnosis

The disorder should be differentiated from other causes of megaduodenum or duodenal ileus including diabetes mellitus, collagen vascular diseases, chronic idiopathic intestinal pseudo obstruction and mechanical obstruction secondary to peptic ulcer disease or duodenal web.<sup>7</sup>

## Complications

The disorder predisposes the patient to electrolyte imbalances (hypokalemia, hyponatremia, metabolic alkalosis), dehydration, malnutrition, oliguria, hypotension and aspiration pneumonia.<sup>7,8</sup>

## Treatment

For acute & initial presentations, treatment is conservative. Prompt fluid & electrolyte resuscitation is done with nasojejunal feeding to bypass the obstruction. Nutritional support is essential to replenish the retroperitoneal fat.<sup>7</sup> Patient mobilization to the left lateral decubitus, kneechest or prone position can provide relief of symptoms.<sup>7,8</sup>

## Surgical management

Surgical management is reserved for individuals not responding to 4-6 weeks of vigorous conservative management, patients with severe weight loss, associated peptic ulcer disease and significant duodenal dilatation.<sup>8,10</sup>

The procedure of choice with the highest success rates of 86% is Laparoscopic duodenojejunostomy. Other options include gastrojejunostomy and duodenal derotation procedure (Strong's procedure).<sup>8-10</sup>

*Funding: None*

*Conflict of interest: None*

*Ethical approval: The study was approved by the institutional ethics committee*

## REFERENCES

1. Lamba Ramit, Tanner T, Sekhon Simran, McGahan P, Corwin T, Lall G. Multidetector CT of Vascular Compression Syndromes in the Abdomen and Pelvis. *Radiographics*. 2014;34(1):93-115.
2. Fong KKJ, Poh ACC, Tan AGS, Ranu T. Imaging Findings and Clinical Features of Abdominal

- Vascular Compression Syndromes. *Am J Roentgenol.* 2014;203(1):29-36.
3. Konen E, Amitai M, Apter S, Garniek A, Gayer G, Nass S, Itzhak Y. CT angiography of superior mesenteric artery syndrome. *Am J Roentgenol.* 1998;171(5):1279-81.
  4. Neri S, Signorelli SS, Mondati E, Pulvirenti D, Campanile E, Di Pino L et al. Ultrasound imaging in diagnosis of superior mesenteric artery syndrome. *J Intern Med.* 2005;257(4):346-51.
  5. GA Agrawal, PT Johnson, EK Fishman. Multidetector row CT of superior mesenteric artery syndrome. *J Clin Gastroenterol.* 2007;41(1):62-5.
  6. Birsan U, Aykut A, Gokhan K, Yasemin B, Sefa G, Cagatay D, Kuzey A. Superior mesenteric artery syndrome: CT and ultrasonography findings. *Diagn Interv Radiol.* 2005;11:90-5.
  7. Welsch T, Büchler MW, Kienle P. Recalling superior mesenteric artery syndrome. *Dig Surg.* 2007;24(3):149-56.
  8. Merrett ND, Wilson RB, Cosman P, Biankin AV. Superior mesenteric artery syndrome: diagnosis and treatment strategies. *J Gastrointest Surg.* 2009;13(2):287-92.
  9. Lee TH, Lee JS, Jo Y, Park KS, Cheon JH, Kim YS, Jang JY, Kang YW. Superior mesenteric artery syndrome: where do we stand today? *J Gastrointest Surg.* 2012;16(12):2203-11.
  10. Wyten R, Kely CJ, Falk GL. Laparoscopic duodenojejunostomy for the treatment of superior mesenteric artery (SMA) syndrome: case series. *J Laparoendosc Adv Surg Tech A.* 2010;20(2):173-6.

**Cite this article as:** Suresh N, Nanjundan M, Natarajan S, Chandrasekaran S. Imaging features of superior mesenteric artery syndrome: a rare vascular compression disorder. *Int Surg J* 2016;3:975-81.