

Case Report

Dermoid of spermatic cord diagnostic dilemma

Sagar Ramesh Ambre*, Anuradha Dnayanmote, Mayank Chakraborty, Omkar Shirke,
Shubhi Bhatnagar, Shrrey Akhil

Department of Surgery, Dr. DY Patil Medical College, Pimpri, Pune, Maharashtra 411018, India

Received: 13 September 2017

Revised: 04 October 2017

Accepted: 07 October 2017

***Correspondence:**

Dr. Sagar Ramesh Ambre,

E-mail: sagarmssurgery@gmail.com

Copyright: © the author(s), publisher and licensee Medip Academy. This is an open-access article distributed under the terms of the Creative Commons Attribution Non-Commercial License, which permits unrestricted non-commercial use, distribution, and reproduction in any medium, provided the original work is properly cited.

ABSTRACT

Dermoid cyst of spermatic cord is extremely rare pathology. We present the case of 25-year-old male who presented with a right groin lump, thought to be a hernia. The swelling was reducible and cough impulse was positive. There was a lump found close to the right groin apart from hernia. After dissection it was seen as protruding out superficial ring and was attached to the spermatic cord. The final histopathological analysis gave the diagnosis of a dermoid cyst.

Keywords: Dermoid, Hernia, Indirect sac, Inguino scrotal region, Spermatic cord

INTRODUCTION

spermatic cord dermoid is an extremely rare pathology state seen at general surgery. There are benign and malignant masses can be seen, like hernia, hydrocele, varicocele, abscess etc. Any mass needs to be exploration.¹

Spermatic cord lesion can be due to causative factor like trauma or tumours.² hernia or any other inguino scrotal region swelling are difficult to differentiate from other causes on examination.³ in our case patient present as indirect inguinal hernia with palpable lump in groin, on intraoperative we found lump attached to spermatic cord; with indirect sac also present.

CASE REPORT

A 25-year-old man presented to our surgery opd with the history of a swelling in the inguinal region. He gives history of the swelling for 2 years which increases on standing and decreases by its self on lying down, swelling also increases on coughing. There were no other comorbidities. He was otherwise healthy with no history of

any similar swelling in the past. On examination 4cm swelling was there in the right inguinal region, cough impulse was present and on deep ring occlusion test swelling did not appear medial to occluding finger that gave our diagnosis of indirect inguinal hernia. There was another similar palpable swelling in the root of the scrotum which is mobile, non-tender firm in consistency, skin over the swelling was normal; it was non-transilluminating, and non-fluctuating. So, depending on examination finding we thought it to be lipoma or a hydrocele of the cord.

On abdominal examination, it was soft and non-tender. Both testies were normal. Ultra-sonogram showed presence of right groin mass consisting of cystic lesion measuring approximately 6* 2.5cm, and indirect sac was noted. No other features suggestive of any underline malignancy. Later, patient underwent exploration for inguinal hernia with exploration of spermatic cord with differential diagnosis of lipoma or encysted hydrocele of the cord. During surgery we noticed indirect sac and single firm mass on spermatic cord, of size measuring approx 4cm within the inguinal canal.

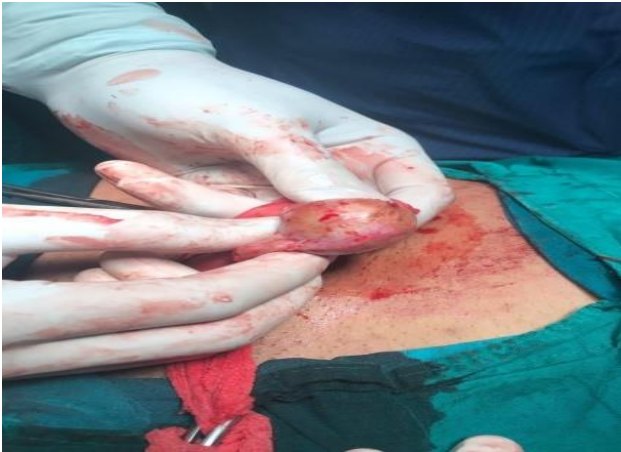

Figure 1: Intraoperative photo of cyst.

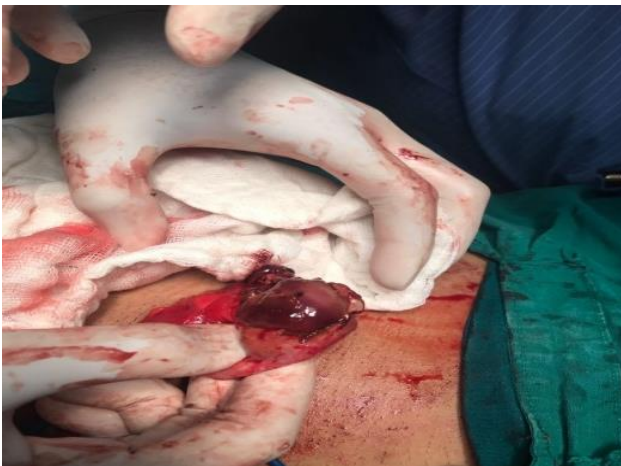

Figure 2: Cyst opened intraoperatively.

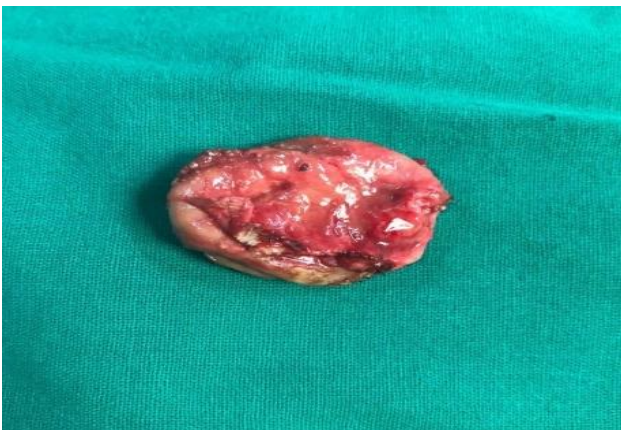

Figure 3: In toto cyst wall.

On mass dissection it was easily separated from the cord. The mass was excised and sent for histopathological examination, we also found indirect sac was transfixied and mesh placement were done.

On histopathological examination diagnosis was given of "Dermoid Cyst". Section showed thin walled cystic

structures lined keratinizing squamous epithelium. Sebaceous gland was also seen, there was no evidence of any malignancy. The surrounding fatty connective tissue contained no residual or atrophic testicular tissue. The patient had uneventful recovery.

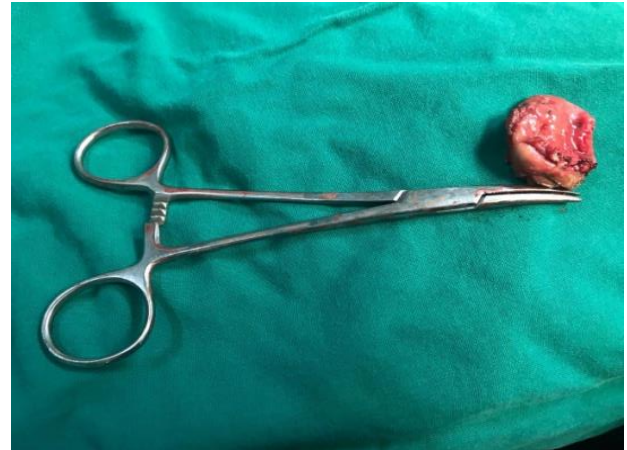

Figure 4: Cyst photo post- op.

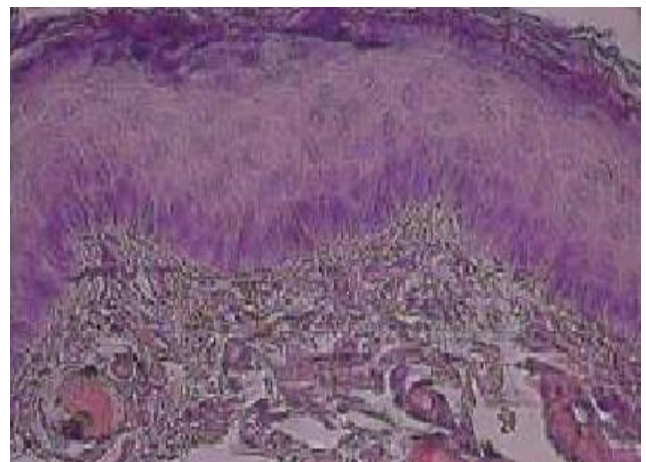


Figure 5: HPE suggestive of a dermoid cyst.

DISCUSSION

Patients with groin swelling, the first diagnosis would be inguinal hernia.⁴ other causes of groin swelling includes hydrocele, femoral hernia, undescended testes, femoral lymph node, lipoma of cord, spermatocele, femoral artery aneurysm, sphenava varix, varicocele, thrombophelbitis of long sephanous vein.⁵ Dermoid cyst of spermatic cord is a rare cause of groin swelling till now 11 cases reported to date.⁶ We present a case of dermoid cyst of spermatic cord in a 25year old man. Dermoid cyst of spermatic cord should be considered as a part of differential diagnosis of inguinal masses.^{5,6} We present the first case in adult inguinal hernia with dermoid cyst in our hospital and 12th case reported to date. Dermoid is a term given to a cyst lined by squamous epithelium.⁷ Dermoid cyst are congenital lesion that results when epithelium trapped during fetal midline closure. Dermoid cyst seen in nasal

tip, forehead, behind the ear, intracranial, intraspinal, perispinal, intra-abdominal, ovary, omentum, neck. Dermoid cyst is the sequestration of skin along the lines of embryonic closure. A dermoid cyst is teratoma that contains mature skin, hair follicles, sweat gland, long hair, pockets of sebum, blood, fat, bone, nails, teeth, eyes, cartilage, thyroid tissue. It is rarely malignant.⁸

Histological a wall of cyst consists of all components of skin, hair, sweat and sebaceous gland, It also demonstrates squamous epithelium, epocrine glands, pilosebaceous unit. Dermoid cyst of spermatic cord is not thought to be painful.⁹

Dermoid cyst are always benign lesions, in symptomatic cases surgical excision is the only treatment.^{10,11} No case of malignant transformation has been reported till date.¹²

CONCLUSION

Dermoid cyst is a rare in the groin. The diagnosis may be a dilemma. Groin dermoid cyst requires surgical excision and histopathological confirmation. Dermoid cyst of spermatic cord should be kept in mind as a part of the differential diagnosis.

Funding: No funding sources

Conflict of interest: None declared

Ethical approval: Not required

REFERENCES

1. Bhosale PR, Patnana M, Viswanathane, Szklarukj. The inguinal canal anatomy and imaging features of common and uncommon masses Radiographics. 2008 May;28:819-35.
2. Ragheb D, Higgins JL. Ultrasonography of the scrotum. Journal of ultrasound in medicine. 2002 Feb 1;21(2):171-85.
3. Permi HS. Liposarcoma of spermatic cord presenting as indirect inguinal hernia-a rare case report. Instructions to authors 81 Nujhs Declaration and Copyright Transfer Form. 2011 Sept;1(1-3):63-5.
4. Aslam MZ, Kheradmund F, Patel NS, Turner G, Cranston D. Dermoid cyst of the spermatic cord: a rare cause of benign inguinal lump. Canadian Urological Association Journal. 2009 Aug;3(4):E29.
5. Jhonstone JM, Rintal RF, Unusual case of inguinal mass. BMJ. 1970;2:179.
6. Prada-arias M, Oritz Rey JA, Fernandez Eire P, Montero Sanchez M, Lema Carril A, Segade Andrade R. Dermoid cyst of spermatic cord in children source; Department of Pediatric Surgery, Complejo hospitalario universitario de vigo (chuui), sergas, 36204 vigo (pontevedra); Spain J Pediatric Surge. 2010;45:2058-60.
7. Israel MS. Development of tumors and tumor-like lesions. General Pathology, 6th Ed. Edinburgh (UK): Churchill Livingstone. 1987:370-386.
8. Freedberg. Fitzpatrick's dermatology in general medicine; 6th Ed; Mc GrawHill. ISBN 0-07-IQ8076-0; 2003.
9. Ghosh DP. Dermoid cyst of spermatic cord. J Indian Med Assoc. 1980;74:18-9.
10. Leeming R, Olsen M, Ponsky JL. Inguinal dermoid cyst presenting as an incarcerated inguinal hernia. J Ped Surg. 1992;27:117-8.
11. Brightmore T. Dermoid cyst of inguinal canal simulating a strangulated inguinal hernia. BR J Clin Pract. 1971;25:191.
12. Wegner HEH, Herbest H, Diekmann KP. Para testicular epidermoid cyst and ipsilateral spermatic cord dermoid cyst; case report and discussion of pathogenesis, diagnosis and treatment. J Urol. 1994;152:2101-3.

Cite this article as: Ambre SR, Dnayanmote A, Chakraborty M, Shirke O, Bhatnagar S, Akhil S. Dermoid of spermatic cord diagnostic dilemma. Int Surg J 2017;4:3776-8.