

## Original Research Article

# The relationship between primary tumour thicknesses in cancers of the oral cavity to subsequent lymph node metastasis

Ahmed Fawzy<sup>1\*</sup>, Waleed Ali Al zaqri<sup>2</sup>, Mohamed Sabry<sup>1</sup>, Ahmed Sabry<sup>1</sup>, Hosam El Fol<sup>1</sup>,  
Ahmed El Kased<sup>1</sup>

<sup>1</sup>Department of General Surgery, Faculty of Medicine, Menoufia University, Egypt

<sup>2</sup>Department of Oral and maxillofacial Surgery, Faculty of Dentistry, Yemen

**Received:** 03 August 2017

**Accepted:** 12 August 2017

### \*Correspondence:

Dr. Ahmed Fawzy,

E-mail: [drahmedfawzy9@gmail.com](mailto:drahmedfawzy9@gmail.com)

**Copyright:** © the author(s), publisher and licensee Medip Academy. This is an open-access article distributed under the terms of the Creative Commons Attribution Non-Commercial License, which permits unrestricted non-commercial use, distribution, and reproduction in any medium, provided the original work is properly cited.

## ABSTRACT

**Background:** Elective dissection of cervical lymph nodes in oral cavity cancers gives very precious data on its pathological state, judge for adjuvant therapy requirement plus its therapeutic effect but it has its morbidities that cannot be condoned. Tumor thickness (TT) in oral cavity cancers show an increasing value to be one of the most important and reliable factors that have a great relationship to regional node involvement.

**Methods:** Forty-three patients with T1, T2 oral cavity squamous cell carcinoma with clinically and radiologically negative cervical L.Ns underwent elective neck dissection and the relation between the tumor thickness and the nodal metastasis was monitored. Tumor thickness was estimated preoperatively by using the intra-oral ultrasound and confirmed by histopathology postoperatively.

**Results:** Only 12 out of 43 neck dissections (27.9%) showed positive L.Ns metastasis of primary tumor. The excised number of L.Ns ranged from 15 to 31 with mean±SD (21.58±3.59) L.Ns. The (TT) ranged from 1.4 mm to 7.8 mm. Our statistical results showed that there is a cutoff point which was 4 mm where (TT) > 4 mm showed significant results with histologically found positive cervical node metastasis compared to (TT) ≤4 mm specimens.

**Conclusions:** Relationship of tumor thickness to lymph node metastasis was found to be significant as shown by this study. Our results clearly demonstrate that conservative elective neck dissection is indicated in patients with stage I/II oral cavity carcinoma whose tumors are > 4 mm in thickness as they mostly have latent metastasis.

**Keywords:** Oral cavity cancer, Tumor thickness, Cervical node metastasis

## INTRODUCTION

Cancers of the oral cavity ranks as one of the ten most frequently diagnosed cancers in the world with 363,000 new oral and pharyngeal cancer cases and almost 200,000 deaths annually worldwide. The World Health Organization predicts a continuing worldwide increase in the number of cases of oral cancer for the next several decades. In 2006, there were 31,000 new oral and pharyngeal cancers diagnosed in the United States,

representing approximately 3% of all cancers.<sup>1</sup> Elective node dissection provides valuable pathologic information on the status of cervical lymph nodes and helps to determine the need for adjuvant therapy. It also has a therapeutic effect by removing pathologically undetectable cancer cells lodged in the lymphatics between the primary tumor and the first-echelon lymph nodes. However, many patients are subjected to treatment that they do not require; such treatment may remove or destroy a barrier to cancer spread, and there is a

morbidity associated with elective treatment.<sup>2</sup> So the need to predict the risk of lymph node metastases in clinically N0 patients with oral cancer is very important in treatment planning for the neck.<sup>3</sup>

The risk for cervical node metastases is influenced by characteristics of the primary tumor such as location, size, histological grading and surgical margins which showed a significant association with Lympho-vascular and peri-/endoneural invasion, nodal involvement, status of the surgical margins, and therefore the overall prognosis and survival.<sup>4</sup>

Worse prognosis is expected in patients with nodal disease this worsens with the presence of extra-capsular spread. The incidence of occult lymph node metastasis in early stage tumors (T1/T2) has been reported to be between 27%-40%.<sup>5</sup>

It has been proposed that tumor emboli are difficult to form or pass in the small-caliber lymphatics of superficial areas while in the wider the lymphatics of deep tissue this is much easier to occur, so tumor thickness plays a vital role in lympho-vascular invasion.<sup>6,7</sup>

Tumor thickness has been shown with growing evidence to be one of the most important and reliable features in predicting regional node involvement and patient survival in oral cavity cancers.<sup>3,8</sup> It is now widely accepted that thickness is more accurate predictor of sub-clinical nodal metastasis, local recurrence and survival than tumor size.<sup>9</sup>

Depth of invasion is defined as distance between normal mucosal surface and the deepest point of invasion. A precise clinically optimal tumor thickness cut-off point is not established yet.<sup>10</sup> In a meta-analysis, sixteen relevant studies were examined for the cut-off tumor thickness points (3, 4, 5 and 6mm). There was a statistically significant difference between the 4 mm and 5 mm tumor thickness cut-off points and cervical lymph node involvement in oral squamous cell carcinoma (OSCC).<sup>9,10</sup>

Conventional tomography (C.T.), magnetic resonance (M.R.I.), and ultrasonography (U/S) are diagnostic tools used for preoperative assessment of tumor thickness and neck nodes.<sup>11</sup>

Brekel et al, introduced the main advantages of (U/S) than (C.T.) or (M.R.I) that it can be easily combined with fine-needle aspiration biopsy (FNAB) resulting in a specificity of 100% for the combined technique of ultrasound guided fine-needle aspiration biopsy also recent literature suggests that intra-oral ultrasound is an acceptable alternative to MRI for assessment of tumor thickness.<sup>12,13</sup>

Sureshkannan et al, proved that (U/S) was a reliable and valuable tool for metastatic lymph node screening in head and neck cancer patients.<sup>14</sup> It is a non-invasive, easy to handle and cost effective diagnostic method. (U/S)

performed better than clinical palpation in detecting cervical metastatic nodes.

In this study, we intend to offer our expertise in the relationship of tumor thickness in oral cavity carcinoma to subsequent lymph node metastasis.

## METHODS

During the period from January 2011 to June 2017, forty three patients with stage I and II oral cavity squamous cell carcinoma with clinically and radiologically negative cervical lymph nodes (T1, T2 / N0) underwent primary tumour resection and elective neck dissection in Al Menoufia University Hospitals and the relation between the primary tumor thickness and the nodal metastasis was monitored.

After obtaining the patients' consent, they underwent the surgery under general anesthesia after history taking, complete clinical, imaging and laboratory examinations.

For estimation of TT and assessing the cervical L.Ns state the Pts. were referred to a highly specialized radiology center in Cairo where they underwent the intraoral U/S by special superficial intraoral U/S probe. At the same time, all Pts. underwent neck U/S in the same center and when the radiologist had any doubt about presence of metastatic cervical lymph nodes and can't give us a sharp final diagnosis these Pts. were sent to the MRI scanning. The diagnosis was confirmed by histopathology postoperatively.

Inclusion criteria included proven oral cancer by histopathology (oral squamous cell carcinoma), Clinical negative neck node, stage I and II oral carcinoma. Pts. who didn't receive previous radio or chemo therapy and de-novo cases with good general condition allowing major surgical procedure.

We excluded from this study all patients with clinical stage III and IV oral cancer or lesions secondary to another primary site, patients with recurrent disease, patients performed excisional biopsy, and patients with history of radiotherapy or chemotherapy for tumors in the head and neck.

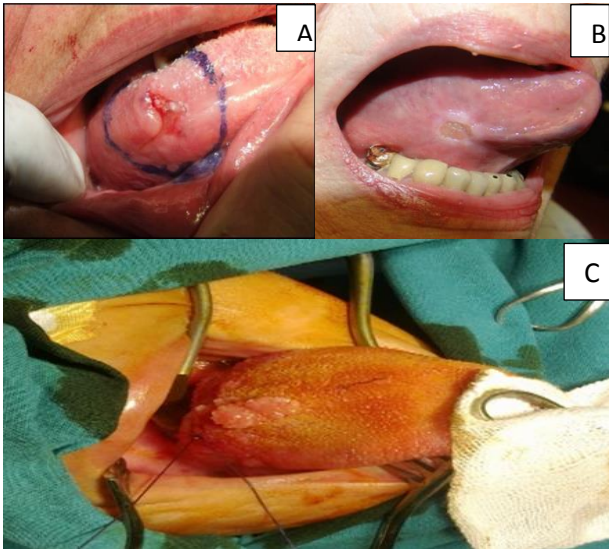
**Table 1: Sex distribution among studied group (N=43).**

Sex	Studied group (N=43)	
	No.	%
Male	29	67.4
Female	14	32.6

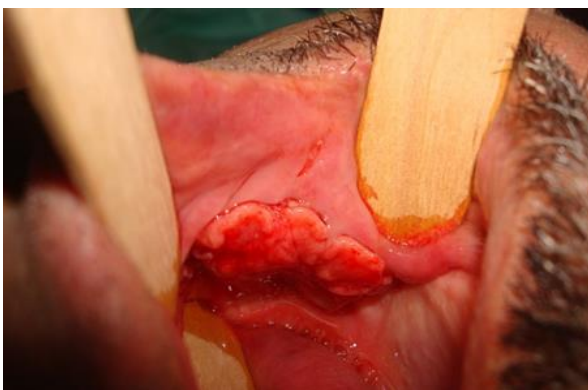
The studied groups were 43 patients; 29 males (67.4%) and 14 females (32.6%) with male to female ratio 2.07:1, the age of the patient ranged from 38-72 years old with a mean of 54.6 years old (Table 1,2).

**Table 2: Mean age of studied group (N=43).**

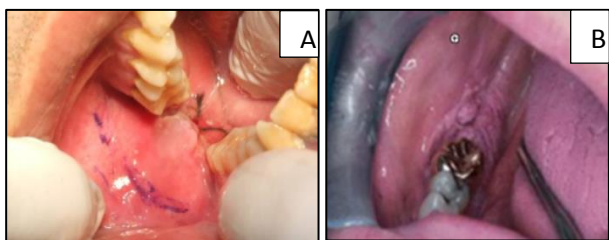
Age / years	Studied group (N=43)
Mean	54.6
SD	8.28
Minimum	38
Maximum	72



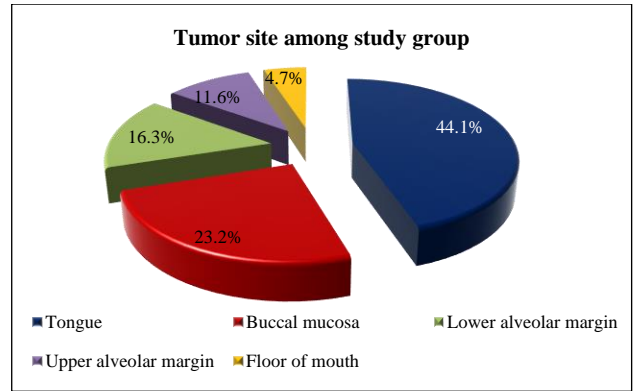
**Figure (1): Different tongue lesions. A) Lesion at the lateral surface of the tongue; B) Lesion at the ventral surface of the tongue; C) Lesion at the dorsum of the tongue.**



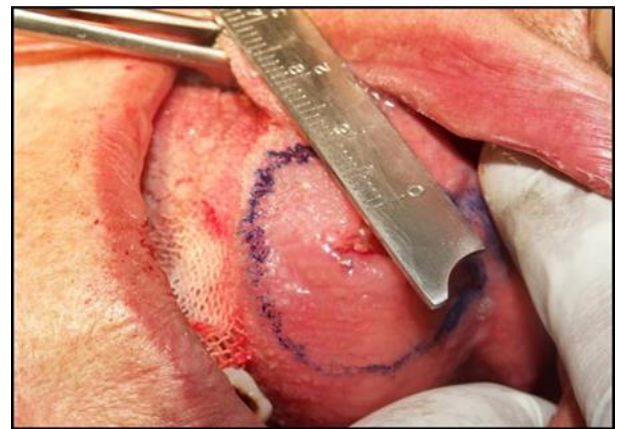**Figure 2: Lesion in buccal mucosa of right cheek.**



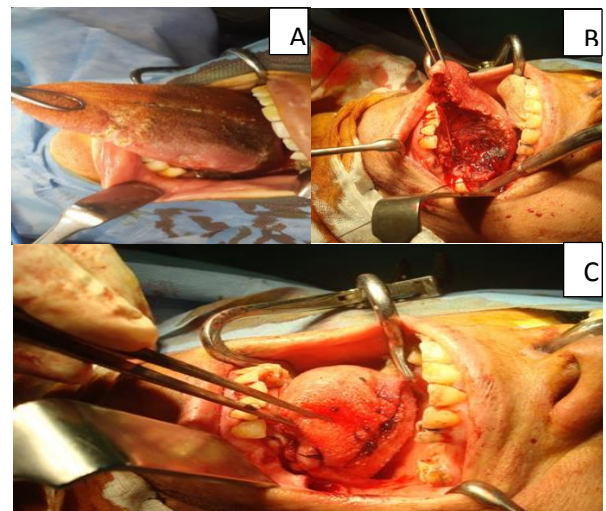
**Figure 3: A) lesion in alveolar ridge of right retro-molar region; B) A slightly white nodular ulceration of the retro-molar region.**



**Figure 4: Distribution of tumour site among study group.**



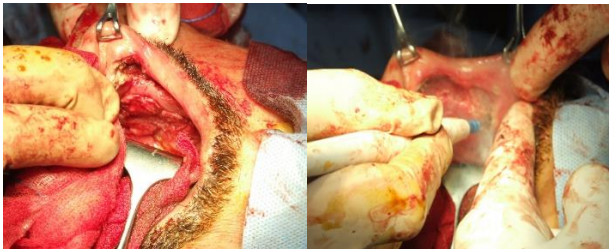**Figure 5: Safety margin 10 mm.**



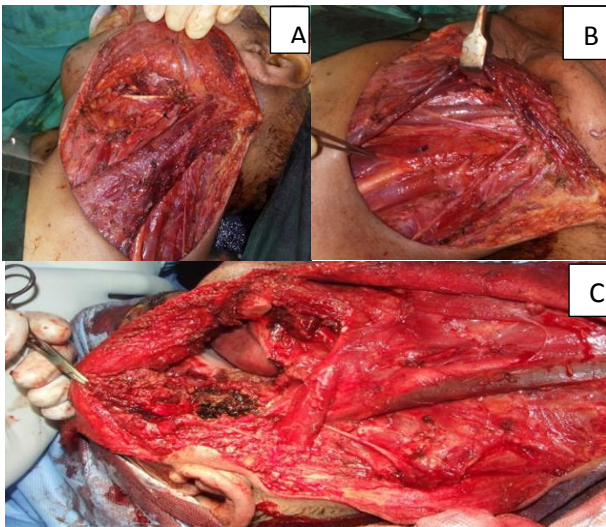
**Figure 6: Partial tongue resection and defect closure; A) Marking of incision site; B) Excision of the lesion; C) Closure of tongue defect.**

Tumor site was the tongue in nineteen (19) patient (44.1%), buccal mucosa in ten (10) patients (23.2%), lower alveolar margin in seven (7) patients (16.3%), upper alveolar margin in five (5) patients (11.6%), floor

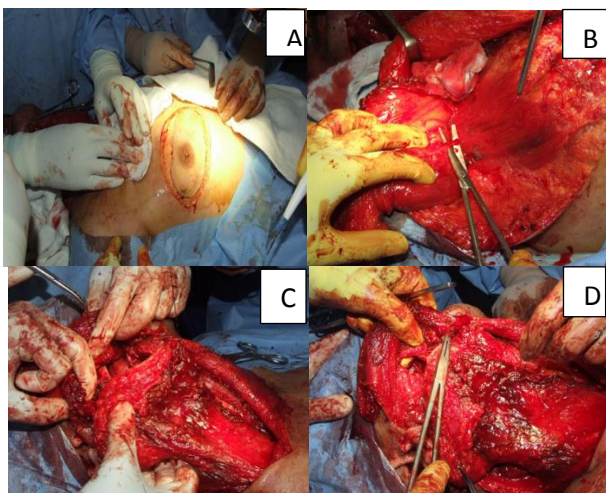
of the mouth in two (2) patients (4.7%) (Figures 1, 2, 3 and 4).



**Figure 7: Buccal carcinoma resection.**



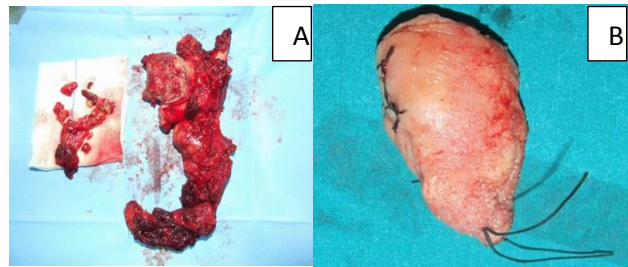
**Figure 8: Neck dissections; (A, B) With preservation of sternomastiod muscle; C) Without preservation of sternomastiod muscle.**



**Figure 9: Reconstruction of resultant defect; A) Marking of flap; B) Identification of the perforator; C) Positioning of the flap; D) Closure of oral cavity defect.**

Resection of primary tumor site with 10 mm safety margin (Figure 5, 6 and 7) and elective neck dissection

was done with suitable reconstruction of resultant defect if needed (Figure 8, 9). Then the specimens were sent for pathological assessment (Figure 10), data collected and statistically analyzed.



**Figure 10: Specimens; A) Primary lesion combined with mandiblectomy and neck dissection specimen; B) Partial glossectomy.**

## RESULTS

### Statistical analysis

Data were collected, tabulated, statistically analyzed using an IBM personal computer with Statistical Package of Social Science (SPSS) version 20 where the following statistics were applied.

*Descriptive statistics:* in which quantitative data were presented in the form of mean ( $\bar{X}$ ), standard deviation (SD), range, and qualitative data were presented in the form numbers and percentages.

*Analytical statistics:* used to find out the possible association between studied factors and the targeted disease. The used tests of significance included:

*Student t-test:* is a test of significance used for comparison between two groups having quantitative variables.

*The ROC (receiver operating characteristic) curves (Figure 11):* This procedure used to evaluate the performance of classification schemes in which there is one variable of two categories by which subjects are classified. They were constructed by calculating the sensitivities and specificities of the variable. The cutoff value with the highest accuracy was selected as the diagnostic cutoff points.

- Sensitivity, specificity, positive and negative predictive value, and diagnostic accuracy were calculated according to the following formulas:
- Sensitivity=  $a / (a+c)$
- Specificity=  $d / (b+d)$
- Accuracy=  $(a+d) / (a+b+c+d)$
- Negative predictive value=  $d / (c+d)$
- Positive predictive value=  $a / (a+b)$ .

Where a= true positive cases; b= false positive cases; c= false negative cases; d= true negative cases.

**Table 3: Tumour characters among studied group (N=43).**

Tumor characters	Studied group (N=43)	
	No.	%
<b>Tumor site</b>		
Tongue	19	44.1
Buccal mucosa	10	23.2
Lower alveolar margin	7	16.3
Upper alveolar margin	5	11.6
Floor of mouth	2	4.7
<b>Clinical stage of tumour</b>		
T1N0	17	39.5
T2N0	26	60.5
<b>Pathological stage of tumour</b>		
T1N0	15	34.9
T1N1	2	4.7
T2N0	16	37.2
T2N1	10	23.2
<b>Lymph node metastasis</b>		
Negative	31	72.1
Positive	12	27.9
<b>Grade of tumor</b>		
Grade 1 (Well differentiated)	33	76.7
Grade 2 (Moderately differentiated)	8	18.6
Grade 3 (Poorly differentiated)	2	4.7
Grade 4 (Undifferentiated)	0	0

**Table 4: Number of excised L.Ns during cervical lymphadenectomy surgery.**

L.Ns count	Number of harvested L.Ns
Mean	21.58
SD	3.59
Minimum	15
Maximum	31

The different primary tumour sites, difference between clinical and pathological stages of the tumours, state of L.Ns metastasis where nearly 28% of Pts. showed latent pathological metastasis were illustrated in Table 3. Lastly

**Table 6: Diagnostic validity of tumor thickness in detection of lymph node metastasis.**

Cutoff point	Sensitivity	Specificity	Positive predictive value	Negative predictive value	Diagnostic accuracy
4.4mm	92%	100%	100%	97%	98%

The maximum tumour thickness for negative L.Ns was 4 mm and the lowest tumour thickness for positive L.Ns was 4.3 mm with highly significant difference between

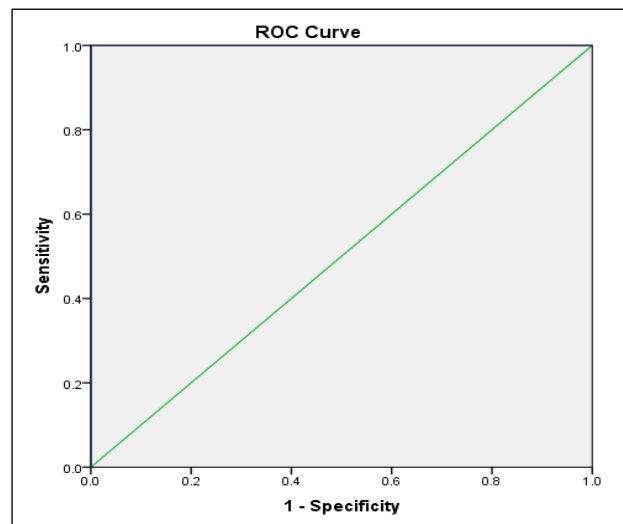
it also described the degree of differentiation of the primary tumour with well differentiated tumour (>75% cell differentiation) in 33 patients (76.6%) of tumours, moderately differentiated tumour (50-75% cell differentiation) in 8 patients (18.6%), poorly differentiated tumour (25-50% cell differentiation) in 2 patients (4.7%), with no un differentiated tumour (<25% cell differentiation).

The maximum count of harvested L.Ns during cervical lymphadenectomy was 31 L.Ns while the minimum count was 15 L.Ns with mean±SD (21.58±3.59) L.Ns (Table 4).

**Table 5: Relation between tumour thickness and lymph node metastasis among studied group (N=43).**

Tumour thickness/ mm	Lymph node metastasis		t-test	P value
	Positive (N=12)	Negative (N=31)		
Mean±SD	5.55±1.07	2.88±0.75	9.22	0.001 (HS)
Range	4.3 - 7.8	1.10 - 4.0		

HS: Highly significant



AUC (Area under the curve = 100)

**Figure 11: The ROC (receiver operating characteristic) curve.**

ranges for negative nodes (1.1-4 mm) and positive nodes (4.3-7.8 mm) (Table 5).

The statistical tumour thickness cutoff point was 4.4 mm with sensitivity 92%, specificity 100%, positive predictive value 100%, negative predictive value 97%, and diagnostic accuracy 98% (Table 6, Figure 11).

The tumor thickness of patients included in current study ranged from 1.1 mm to 7.8 mm with mean 3.63 mm and (Table 7).

**Table 7: Mean tumour thickness among studied group.**

Tumor thickness/ mm	Studied group (N=43)
Mean	3.63
SD	1.47
Minimum	1.1
Maximum	7.8

**DISCUSSION**

Oral cancer is one of the 10 most frequent cancers worldwide, with about three-quarters of all cases occurring in the developing countries. In Central and Southeast Asia, it accounts for up to 40% of all cancers

whereas in most industrialized countries it is relatively uncommon, accounting for less than 4%.<sup>15</sup>

Despite advances in surgery and radiation therapy, there is little improvement in survival rate of oral cancer which is nearly 50-55% for 5 years. This is primarily because of metastatic disease at regional and distant sites, through local recurrence and second primary tumors. Lymphatic metastasis in the neck is a significant problem in patients with SCC. In fact, metastasis to cervical lymph nodes occurs more frequently from the tongue than from any other primary tumor site in the oral cavity. Primary SCC spreads through lymphatic channels to the lymph nodes of the cervical region. Involved nodes usually are firm, non-tender and enlarged during palpation. Several studies, however, have shown a high rate of occult nodal metastasis (20-40%) in SCC patients with no evidence of regional spread on clinical or radiographic evaluation.<sup>1</sup>

The clinical aspects and preoperative tests are not completely reliable to detection of cervical occult metastases nodes. The presence of occult node metastases of early-stage tumors in the clinically negative neck has been reported in 20% to 44% of cases.<sup>16,17</sup>

**Table 8: Tumour thickness cut-off values and lymph node metastasis in early (T1 and T2) squamous cell carcinoma of the oral tongue.**

Author and year	Number of patients	Clinical N-stage	Thickness Cut-Off	Lymph node metastasis	P-value
Woolgar JA	50	N0-N2c	10mm	≥ 10 mm:75% < 10 mm: 0%	<0.0001
Yuen APW	72	N0	3mm	> 3 mm: 50% ≤ 3 mm: 8.3%	0.031
Kurokawa	50	N0	4mm	≥ 4 mm: 37.5% < 4 mm: 2.9%	0.01
O-Charoenrat	50	N0	5mm	> 5 mm: 64% ≤5 mm: 37.5%	0.003
Lim SC	56	N0	4mm	≥4 mm: 45% < 4 mm: 5%	0.009
Kane SV	48	N0	5mm	≥5 mm: 33.3% < 5 mm: 11.1%	0.101
Tai SK	190	N0-n2c	5mm	> 5 mm: 43.7% ≤5 mm: 12.7%	0.023
Tai SK	201	N0	6mm	> 6 mm: 27.4% ≤6 mm: 16.4%	0.035
Matos	74	N0	7mm	> 7 mm: 51.0% ≤7 mm: 0.0%	<0.0001

The failure in management of neck was the most significant problem, despite the fact that more than half of those with early primary tumors had elective neck dissection. It seemed clear that tumour stage alone was not reliable for predicting which of N0 oral cancer patients were at greatest risk for cervical metastasis. For

this reason, Spiro and his colleagues were retrospectively assessed the impact of tumor thickness using an optical micrometer to measure the thickness in millimeters of the excised tumors in routinely prepared paraffin sections. They found the increasing in tumor thickness, rather than

tumor stage, had the best correlation with treatment failure and survival.<sup>18</sup>

Several studies showed the tumor thickness is an important factor in cervical metastasis of squamous cell carcinoma of the tongue and floor of the mouth, lower lip, soft palate, and oral cavity.<sup>19</sup>

Pentenero and his colleagues reviewed of the studies analyzing “tumour thickness”/“depth of invasion” in predicting regional metastases and survival. They found “tumour thickness”/“depth of invasion” is a reliable parameter for predicting regional nodal involvement and survival in oral squamous cell carcinoma.<sup>8</sup>

To avoid of subjected to potential morbidity of elective neck dissection in the patients with primary tumor and N0 neck, there is debate about the optimum tumor thickness that indicated for elective neck dissection.<sup>19</sup>

The aim of this study was to evaluate the clinic-pathologic factors that determine the cut-off thickness of tumor which metastases to cervical lymph node according to our experience.

There are many techniques used for measuring the tumor thickness. Several studies compared intra-oral ultrasound (US) with magnetic resonance imaging (MRI) or computed tomography (CT).

In 1989, Iro and Nitsche showed that using a miniaturized transducer enables the depiction of tumours of the anterior tongue and the floor of the mouth without artefacts.<sup>20</sup> They found this method to be superior to conventional US for this region and more accurate for the estimation of tumour thickness.<sup>3,19</sup>

US thus seem to be the optimal technique in patients with no limited mouth opening or base of tongue involvement. US measurement is more reliable than MRI for the measurement of tumour thickness, especially in superficial lesions.<sup>20,21</sup> This correlate with our work by use ultrasound as preoperative indicator for measuring the tumor thickness in oral cavity cancers.

There is wide controversial about the cutoff thickness of tumour that may help in determination the cervical lymph node metastasis in N0 patient.

Pentenero et al, were shown the tumour thickness to be an important parameter for predicting nodal metastases and for survival.<sup>8</sup> They found that the cut-off thickness predicting neck metastasis and survival varied from 1.5 mm to 10 mm. Thus, it remains difficult to choose a reliable cut-off point for elective neck treatment and /or adjuvant radiotherapy.

In retrospective study for analyzed tumour thickness in 92 patients treated with surgery for tongue and floor of mouth carcinomas. It was concluded that for clinically

N0 oral cancer, elective neck dissection was indicated in patients with depth invasion of more than 2 mm because in these tumors the risk of metastases reached 40%.<sup>3,18</sup>

On the other hand, study did by Fukano et al, showed that tongue tumours exceeding 5 mm carried a risk of 65% for neck metastases, whereas those infiltrating 5 mm or less had a risk of only 6%.<sup>22</sup>

Yuen et al, showed in their study that tumour thickness is prognostic for both nodal and local recurrence in oral carcinomas.<sup>23</sup> They showed the variation in the tumor thickness and its effect on the neck metastasis. A tumour thickness less than 3 mm, had 0% local recurrences and had 8% nodal metastases; tumor thickness of more than 3 mm and up to 9 mm had 44% subclinical nodal metastasis and 7% local recurrence; tumour thickness of more than 9 mm had 53% subclinical nodal metastasis and 24% local recurrence.

Spiro et al, showed the local recurrence occurred in 5% of the group of tumours with thickness <2 mm (2/40), 9% (3/35) within the group 3-8 mm thick and 25% (4/17) for the group with thickness > 9 mm.<sup>18</sup> Local recurrence occurred significantly more in the group with tumour thickness of more than 8 mm, at P-value =0.035. Yet more factors like perineural invasion, radical operation, postoperative treatment and N-staging should also be considered in relation to local recurrence.<sup>23</sup>

In superficial lesions with tumour thickness less than 7 mm, some studies followed the rule of, a wait-and-see policy is only warranted but only if regular follow-up using US guided aspiration of the neck is ensured.<sup>24,25</sup>

Mücke et al, highlight the importance of tumor thickness as a predictive variable in tongue cancer.<sup>26</sup> Specifically, a cut-off point of 8 mm allowed for a more accurate and statistically precise prediction of lymph node metastasis. Their study was done on 492 patients who had a median follow-up of 70 months with squamous cell carcinomas of the tongue.

Cheng et al, found that the TT is a more reliable method for cervical LN metastasis than tumour volume also the optimal TT cutoff is 8.5 mm for the prediction of LN metastases.<sup>27</sup>

There are many investigations showed the variation in tumour thickness cut-off values and lymph node metastasis in early (T1 and T2) squamous cell carcinoma of the oral tongue from 1999 to 2014 (Table 8). Woolgar et al, documented that with TT is 10 mm or more the LNs metastasis were found in 75% of his 50 Pts.<sup>28</sup> with highly significant results (P value = <0.0001). Yuen and his colleagues found that with TT less than or equal 3 mm the LNs metastasis were 8.3% while with TT more than 3 mm it was 50% in their study over 72 Pts.<sup>23</sup> Also, Kurokawa et al, documented in their study over 50 Pts.<sup>29</sup> Occurrence of metastasis in 37.5% with TT ≥ 4 mm

compared to 2.9% when TT less than 4 mm with significant results (P value = 0.01). O-Charoenrat et al, founded in their study over 50 Pts.<sup>30</sup> that with TT is more than 5 mm the incidence of metastasis was 64% compared to 37.5% if TT is equal or less than 5 mm with significant results (P value = 0.003). Lim et al, documented in their study over 56 Pts.<sup>31</sup> that with TT more than or equal 4 mm the L.Ns metastasis were 45% while it was 5% with TT less than 4 mm with significant results (P value = 0.009). Kane SV and his colleagues, found in their study over 48 Pts.<sup>32</sup> That with TT more than or equal 5 mm the L.Ns metastasis were 33.3% compared to 11.1% for tumours less than 5 mm. Tai et al, documented that over 190 Pts. with N0-n2c there were L.Ns metastasis in 43.7% when TT was more than 5 mm compared to 12.7% when the TT was equal or less than 5 mm with significant results (P value = 0.023).<sup>33</sup> Tai et al, showed in over 201 Pts. with N0 documented that the incidence of positive L.Ns metastasis were 27.4% in Pts. with TT more than 6 mm compared to 16.4% in Pts.<sup>34</sup> With TT less than or equal to 6 mm with significant results (P value = 0.035). Matos and his colleagues, in 2014 found in their study over 72 Pts.<sup>35</sup> that with TT more than 7 mm the incidence of positive L.Ns metastasis were 51% compared to zero % if TT was less than or equal 7 mm with highly significant results ( P value = <0.0001) (Table 8).

Wang and Veivers, stated despite some previous evidence for a 4-mm tumour thickness cut-off in oral tongue SCCs, thinner tumours (2-3.9 mm) can also have a propensity for cervical node metastasis.<sup>36</sup> Patients in this category require close monitoring for regional recurrence if they do not have a neck dissection.

We suggest 4 mm. TT as it was the maximum thickness in our study without metastases. Also, there is statistical high significantly difference at this range (1.1-4), (4.3-7.8). Lastly the most important is the statistical cutoff point which was 4.4 mm with sensitivity 92%, specificity 100%, positive predictive value 100%, negative predictive value 97%, and diagnostic accuracy 98%. And as it difficult to reach very accurate thickness by U/S also to be in safe side we suggest 4 mm as the last negative border in clinically negative nodes patients and any tumor thickness more than 4.0 mm in clinically negative nodes patients should undergo elective neck dissection.

Similar to our findings, Huang et al, conducted a meta-analysis for sixteen studies were selected from 72 potential studies, yielding a pooled total of 1136 patients.<sup>9</sup> Data were examined for the following tumour thickness cutoff points: 3 mm (4 studies, 387 patients), 4 mm (9 studies, 778 patients), 5 mm (6 studies, 367 patients), and 6 mm (4 studies, 488 patients). There was a statistically significant difference between the 4-mm and 5-mm tumor thickness cutoff points. They concluded the optimal tumor thickness cutoff point was 4 mm was a strong predictor for cervical lymph-node involvement.

Khan et al, determined the relationship of tumour thickness of oral lesions with metastasis in neck on 58 oral squamous cell carcinoma patients having the median age of 46 (39-55) years.<sup>37</sup> They found the positive presence of lymph node in neck with primary tumors having a size of more than 4 mm by use CT scan of neck with contrast this compatible with our finding.

The main limitation with our study was the number of included patients.

## CONCLUSION

Neck dissection in spite of having a great value by giving precious pathological data and its own therapeutic effect in Pts. with cancers of the oral cavity but it also has much morbidities. The aim of this study was to find a scale or solution or even to pave the way to a little extent so as to avoid doing it for Pts. who do not need it relying on scientific base. Our results clearly demonstrate that conservative elective neck dissection is indicated in patients with Stage I/II oral cavity carcinoma whose tumours are > 4 mm in thickness as they mostly have latent metastasis. Pts. with TT equal or less than 4 mm can avoid neck dissection with close post-operative follow up. Obviously more research, including large, prospective studies, is needed before this modality will be widely accepted.

*Funding: No funding sources*

*Conflict of interest: None declared*

*Ethical approval: This study had been done after taking approval from the ethical committee of Faculty of Medicine in Al Menoufia University and the competent authority of Al Menoufia University Hospitals. Written consent was obtained from every patient for publication of this research and accompanying images*

## REFERENCES

1. Sano D, Myers JN. Metastasis of squamous cell carcinoma of the oral tongue. *Cancer and Metastasis Reviews.* 2007;26:645-62.
2. ÖNerci M, Yilmaz T, Gedikoğlu G. Tumor thickness as a predictor of cervical lymph node metastasis in squamous cell carcinoma of the lower lip. *Otolaryngol Head Neck Surg.* 2000;122:139-42.
3. Lodder WL, Teertstra HJ, Tan B, Pameijer FA, Smeele EL, van Velthuysen MLF, et al. Tumour thickness in oral cancer using an intra-oral ultrasound probe. *European Radiol.* 2011;21:98-106.
4. Scully C, Bagan J. Oral squamous cell carcinoma overview. *Oral Oncol.* 2009;45:301-8.
5. Sharma P, Shah S, Taneja C, Patel AM, Patel MD. A prospective study of prognostic factors for recurrence in early oral tongue cancer. *J Clin Diagn Res. JCDR.* 2013;7:2559.



6. DiTroia J. Nodal metastases and prognosis in carcinoma of the oral cavity. *Otolaryngol Clin North Am.* 1972;5:333-42.
7. Fagan JJ, Collins B, Barnes L, D'Amico F, Myers EN, Johnson JT. Perineural invasion in squamous cell carcinoma of the head and neck. *Arch Otolaryngol Head Neck Surg.* 1998;124:637-40.
8. Pentenero M, Gandolfo S, Carozzo M. Importance of tumor thickness and depth of invasion in nodal involvement and prognosis of oral squamous cell carcinoma: a review of the literature. *Head Neck* 2005;27:1080-91.
9. Woolgar JA. Histopathological prognosticators in oral and oropharyngeal squamous cell carcinoma. *Oral Oncol.* 2006;42:229-39.
10. Huang SH, Hwang D, Lockwood G, Goldstein DP, O'sullivan B. Predictive value of tumor thickness for cervical lymph-node involvement in squamous cell carcinoma of the oral cavity. *Cancer.* 2009;115:1489-97.
11. Curtin HD, Ishwaran H, Mancuso AA, Dalley RW, Caudry DJ, McNeil BJ. Comparison of CT and MR imaging in staging of neck metastases. *Radiol.* 1998;207:123-30.
12. Brekel MW, Castelijns JA, Stel HV, Golding RP, Meyer CJ, Snow GB. Modern imaging techniques and ultrasound-guided aspiration cytology for the assessment of neck node metastases: a prospective comparative study. 1993;250:11-7.
13. Law CP, Chandra RV, Hoang JK, Phal PM. Imaging the oral cavity: key concepts for the radiologist. *Br J Radiol.* 2011;84:944-57.
14. Sureshkannan P, Vijayprabhu, John R. Role of ultrasound in detection of metastatic neck nodes in patients with oral cancer. *Indian J Dent Res.* 2011;22:419-23.
15. Rodrigues V, Moss S, Touraine H. Oral cancer in the UK: to screen or not to screen. *Oral Oncol.* 1998;34:454-65.
16. Fakhri AR, Rao RS, Borges AM, Patel AR. Elective versus therapeutic neck dissection in early carcinoma of the oral tongue. *Am J Surg.* 1989;158:309-313.
17. Sparano A, Weinstein G, Chalian A, Yodul M, Weber R. Multivariate predictors of occult neck metastasis in early oral tongue cancer. *Otolaryngol Head Neck Surg.* 2004;131:472-6.
18. Spiro RH, Huvos AG, Wong GY, Spiro JD, Gnecco CA, Strong EW. Predictive value of tumor thickness in squamous carcinoma confined to the tongue and floor of the mouth. *Am J Surg.* 1986;152:345-50.
19. Asakage T, Yokose T, Mukai K, Tsugane S, Tsubono Y, Asai M, et al. Tumor thickness predicts cervical metastasis in patients with stage I/II carcinoma of the tongue. *Cancer.* 1998;82:1443-8.
20. Iro H, Nitsche N. Intra-oral sonography in neoplasms of the mouth and base of the tongue. *HNO.* 1989;37:329-32.
21. Shintani S, Yoshihama Y, Ueyama Y, Terakado N, Kamei S, Fijimoto Y, et al. The usefulness of intraoral ultrasonography in the evaluation of oral cancer. *Int J Oral Maxil Surg.* 2001;30:139-43.
22. Fukano H, Matsuura H, Nakamura HYS. Depth of invasion as a predictive factor for cervical lymph node metastasis in tongue carcinoma. *Head Neck.* 1997;19:205-10.
23. Yuen PWA, Lam KY, Lam LK, Ho CM, Wong A, Chow TL, et al. Prognostic factors of clinically stage I and II oral tongue carcinoma - a comparative study of stage, thickness, shape, growth pattern, invasive front malignancy grading, Martinez-gimeno score, and pathologic features. *Head Neck.* 2002;24:513-20.
24. van den Brekel, Stel HV, Castelijns JA, Croll GJ, Snow GB. Lymph node staging in patients with clinically negative neck examinations by ultrasound and ultrasound-guided aspiration cytology. *Am J Surg.* 1991;162:362-6.
25. Van den Brekel MW. US-guided fine-needle aspiration cytology of neck nodes in patients with N0 disease. *Radiol.* 1996;201:580.
26. Mücke T, Kanatas A, Ritschl LM, Koerdt S, Tannapfel A, Wolff KD, et al. Tumor thickness and risk of lymph node metastasis in patients with squamous cell carcinoma of the tongue. *Oral Oncol.* 2016;53:80-4.
27. Hu H, Cheng XQ, Xu, Wu FY, Tyan YS, Tsai CH, et al. Predicting the prognosis of oral tongue carcinoma using a simple quantitative measurement based on preoperative MR imaging: tumor thickness versus tumor volume. *AJNR Am J Neuroradiol.* 2015;2.
28. Woolgar JA. T2 carcinoma of the tongue. The histopathologist's perspective. *Br J Oral Maxillofac Surg.* 1999;37:187-93.
29. Kurokawa H, Yamashita Y, Takeda S, Zhang M, Fukuyama H, Takahashi T. Risk factors for late cervical lymph-node metastases in patients with stage I or II carcinoma of the tongue. *Head Neck.* 2002;24(73):1-6.
30. O-Charoenrat P, Pillai G, Patel S, Fisher C, Archer D, Eccles S, et al. Tumour thickness predicts cervical nodal metastases and survival in early oral tongue cancer. *Oral Oncol.* 2003;39:386-90.
31. Lim SC, Zhang S, Ishii G, Endoh Y, Kodama K, Miyamoto S, et al. Predictive markers for late cervical metastasis in stage I and II invasive squamous cell carcinoma of the oral tongue. *Clin Cancer Res.* 2004;10:166-72.
32. Kane SV, Gupta M, Kakade AC, Cruz AD. Depth of invasion is the most significant histological predictor of subclinical cervical lymph-node metastasis in early squamous carcinomas of the oral cavity. *Eur J Surg Oncol.* 2006;32:795-803.
33. Tai SK, Li WY, Chu PY, Chang SY, Tsai TL, Wang YF et al. Risks and clinical implications of perineural invasion in T1-2 oral tongue squamous cell carcinoma. *Head Neck.* 2012;34:994-1001.
34. Tai SK, Li WY, Yang MH, Chu PY, Chang SY, Tasi LT, et al. Perineural invasion as a major

- determinant for the aggressiveness associated with increased tumor thickness in T1-2 oral tongue and buccal squamous cell carcinoma. *Ann Surg Oncol.* 2013;20:3568-74.
35. Luongo de Matos L, Manfro G, Vieira dos Santos R, Stabenow E, Sobroza de Mello E, Alves VAF, et al. Tumor thickness as a predictive factor of lymph node metastasis and disease recurrence in T1N0 and T2N0 squamous cell carcinoma of the oral tongue. *Oral Surg Oral Med Oral Pathol Oral Radiol.* 2014;118:209-17.
  36. Wang K, Veivers D. Tumour thickness as a determinant of nodal metastasis in oral tongue carcinoma. *ANZ J Surg.* 2016.
  37. Khan SA, Zia S, Naqvi SU, Hatem A, Adil SO, Hussain M. Relationship of oral tumor thickness with the rate of lymph node metastasis in Neck based on CT Scan. *Pak J Med Sci.* 2017:353-7.

**Cite this article as:** Fawzy A, Al zaqri WA, Sabry M, Sabry A, El Fol H, El Kased A. The relationship between primary tumour thicknesses in cancers of the oral cavity to subsequent lymph node metastasis. *Int Surg J* 2017;4:2957-66.