

Case Report

Volvulus of gall bladder: case report

Rajneesh Kumar*, Ankur Hastir, Ramandeep Singh Walia, Subhash Goyal

Department of Surgery, Punjab Institute of Medical Science (PIMS), Jalandhar, Punjab, India

Received: 28 July 2017

Accepted: 27 August 2017

***Correspondence:**

Dr. Rajneesh Kumar,

E-mail: dr Rajneeshkumar@gmail.com

Copyright: © the author(s), publisher and licensee Medip Academy. This is an open-access article distributed under the terms of the Creative Commons Attribution Non-Commercial License, which permits unrestricted non-commercial use, distribution, and reproduction in any medium, provided the original work is properly cited.

ABSTRACT

Gall bladder volvulus or twisting is a rare condition and occurs due to rotation of gall bladder. Preoperative diagnosis is exception and usually misdiagnosed as cholecystitis before surgery. It is potentially fatal condition unless diagnosed and treated early leading to gangrene and biliary peritonitis. It has been reported in only about 500 cases in the literature ranging in age given 2-100 years old. We report a rare case of middle aged female 56 years old with volvulus of gall bladder having concomitant cholelithiasis treated with laparoscopic cholecystectomy.

Keywords: Cholecystectomy, Cholelithiasis, Gall bladder volvulus, Torsion

INTRODUCTION

Gall bladder volvulus is a rare and difficult to diagnose clinically as well radiologically was first described by Wendel in 1898.¹ More than 400 cases are reported in literature.^{1,2} Volvulus of gall bladder is more common in elderly females between 7th and 8th decades and female to male ratio of 3:1.³ Causes has been attributed to anatomical variations of gall bladder mesentery and loss of visceral fat, as well mesentery with cystic duct and artery known as floating gall bladder.⁴⁻⁷ when there is strong peristaltic movement or when the stomach contracts, intestines may turn and curl the gall bladder. Morbidity and mortality reported are low among cases of gall bladder torsion that have been diagnosed and treated early.⁸ Delayed or missed diagnosis and treatment increase patient mortality. Symptoms vary depending on severity of disease.

Although recent advance in radiology help to diagnose many diseases, abdominal computed tomography (CT) and ultrasonography (USG) remains non-specific in diagnosing volvulus of gall bladder. Coronal magnetic resonance imaging (MRI) and magnetic resonance colangio-pancreatography (MRCP) and HIDA

(hepatoinodiacetic acid) scan are helpful in making the diagnosis of volvulus of gall bladder. We report as case of gall bladder volvulus with cholelithiasis treated by laparoscopic cholecystectomy and review of gall bladder volvulus.

CASE REPORT

A 56-year-old female reported in OPD with ultrasound diagnosis of acute cholecystitis with cholelithiasis. Patient was having history of pain for last 2 days which was dull and was associated with vomiting.

Clinically patient was pyrexia with no acute distress with stable vital signs. Abdomen was soft, mildly distended and tenderness in right upper quadrant and a positive Murphy's sign.

After routine investigations for laparoscopic cholecystectomy next day patient was taken up for surgery and laparoscopically we found distended rotated gall bladder. Surgery was uneventful after aspiration of clear fluid from gall bladder, laparoscopic cholecystectomy was done. Patient discharged next day and stitches were removed after 8 days (Figure 1).

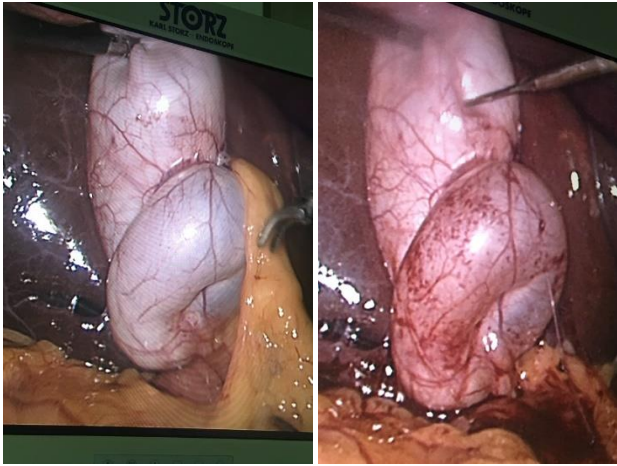


Figure 1: Laparoscopic view of volvulus of gall bladder.

DISCUSSION

Gall bladder volvulus or twisting or torsion is a rare condition primarily seen in elderly women, can be very painful and serious condition, requiring immediate surgical intervention. Complete twist leads to obscure blood flow and in due time there could be gangrene which is life threatening. Worst thing is there is no specific symptom of twisted gall bladder or gall bladder torsion.

First reported by Wendel in 1898, Wendel described a configuration named the “Floating gall bladder” where gall bladder is pedunculated, hanging free of the liver and attached only by cystic mesentery.¹ Volvulus of gall bladder is relatively uncommon condition with no more than 500 cases reported in literature.⁹

Gall bladder volvulus or torsion, when gall bladder rotates either clockwise or anticlockwise around its mesentery along the axis of cystic duct and cystic artery causing complete obstruction of blood flow and biliary damage, resulting in acute gangrenous cholecystitis.³

Anatomical variations of peritoneal covering of gall bladder are well known. There are five recognized positions of gall bladder in relation to liver.

- Completely embedded in liver;
- Closely attached to the under surface of the liver by the peritoneum
- A complete mesentery but held closely to liver
- A complete mesentery which is large and allows the gall bladder to hang freely
- An incomplete mesentery which is attached along the cystic duct and allows gall bladder to hang freely in peritoneal cavity.

Only situations 4 and 5 can predispose to torsion of gall bladder.¹⁰ Intense peristalsis of stomach, duodenum and colon as well as kyphoscoliosis and atherosclerosis of

cystic artery have also been associated.^{4,5,7,11} The susceptibility of rotation may be attributed to the elderly's fat less and tissue atrophy suspending gall bladder freely.⁸ Presence of gall stones has been described in 24% of the reported cases and their role is unclear.^{7,12,13} As condition is rare and occurs in less than 0.1% patients who undergo urgent cholecystectomies for presumed acute cholecystitis.¹²

Correct preoperative diagnosis of gall bladder volvulus is very rare with less than dozen cases have been diagnosed accurately with pre-operative imaging.⁵ Despite technological advances in radiology, definitive diagnosis is generally achieved intra-operatively.¹²

Patient usually presents with acute abdominal pain in upper quadrant with or without vomiting. There may be presence of tender mobile mass indicating a floating gall bladder. Lab investigations may be normal as in one case or leukocytosis maybe there. Liver function is normal as CBD remains unobstructed.¹⁴ Preoperative diagnosis of gall bladder torsion is difficult since clinical features overlap with other acute gall bladder conditions.¹⁵

Distinction between torsion and acute cholecystitis with cholelithiasis is important, as cholecystitis can be treated conservatively but not the torsion of gall bladder. Torsion of gall bladder has mortality rate of 6% though no death occurred in patients diagnosed preoperatively.¹⁶ Thus, early diagnosis and early intervention can reduce mortality associated with this condition.^{16,17} Ultrasonography and computed tomography are non-specific investigations for diagnosis of volvulus.¹⁵ A hepatobiliary iminodiacetic acid (HIDA) scan theoretically shows a characteristic, though not sensitive, “bull's eyes” appearance of the torted gall bladder.¹⁸ T2-weighted MRI images are useful for evaluating necrosis of gall bladder as in cases of torsion.^{19,20}

Treatment is surgical only, can be done laproscopically although open surgery may sometimes be necessary. First the twisting has to be undone if possible to prevent injury to common bile duct. principal of procedure is open or laproscopically is decompression, derotatoion and cholecystectomy with or without transurgical cholangiogram.²¹⁻²³ Severe cases can be life threatening without prompt treatment. Torsion directly affects the blood supply to the gall bladder causing infarction and gangrene.¹¹

Use of percutaneous drainage is only recommended when the surgical procedure could be high risk to patient.²⁴

CONCLUSION

Volvulus or torsion of gall bladder is very rare with less than 500 cases are reported since 1898. Though diagnosis is difficult as features are no specific. When on suspects signs like acute pain and vomiting in elderly female and rapid appearance of a palpable and enlarged gall bladder.

Although multiple imaging methods are there to make preoperative diagnosis, no one has proven to be adequately sufficiently sensitive.

Gall bladder volvulus torsion should be promptly resolved laparoscopically whenever diagnosis is suspected to avoid injury to common bile duct as twisted gall bladder can tent the CBD, making it vulnerable to injury.

So, treatment of gall bladder volvulus is detorsion and cholecystectomy. Both open and laparoscopic techniques can be used

Funding: No funding sources

Conflict of interest: None declared

Ethical approval: Not required

REFERENCES

- Wendel AV. A case of floating gall-bladder and kidney complicated by cholelithiasis, with perforation of the gall-bladder. *Ann Surg.* 1898;27(2):199.
- Reilly DJ, Kalogeropoulos G, Thiruchelvam D. Torsion of the gallbladder: a systematic review. *HPB.* 2012;14(10):669-72.
- Mouawad NJ, Crofts B, Streu R, Desrochers R, Kimball BC. Acute gallbladder torsion-a continued pre-operative diagnostic dilemma. *World J Emergency Surg.* 2011;6(1):13.
- Tarhan OR, Barut I, Dinelek H. Gallbladder volvulus: review of the literature and report of a case. *Turk J Gastroenterol.* 2006;17(3):209-11.
- Nicholas JM. Image of the month: Gallbladder volvulus. *Arch Surg.* 2002;(6):741-2.
- Stieber AC, Bauer JJ. Volvulus of the gallbladder. *Am J Gastroenterol.* 1983;78:96-8.
- Chiew AKH, Ibrahim S, Tay KH. Torsion of the gallbladder: a rare entity. *Ann Acad Med Singapore.* 2007;36(8):705-6.
- Shaikh AA, Charles A, Domingo S, Schaub G. Gallbladder volvulus: report of two original cases and review of the literature. *Am Surg.* 2005;71(1):87-9.
- Pu TW, Fu CY, Lu HE, Cheng WT. Complete body-neck torsion of the gallbladder: a case report. *World J Gastroenterol.* 2014;20(38):14068-72.
- Chilton CP, Mann CV: Torsion of the gallbladder in a nine-year-old boy. *J R Soc Med.* 1980;73(2):141-3.
- Yeh HC, Weiss MF, Gerson CD. Torsion of the gallbladder: the ultrasonographic features. *Journal of Clinical Ultrasound.* 1989;17(2):123-5.
- Nakao A, Matsuda T, Funabiki S, Mori T, Koguchi K, Iwado T, et al. Gallbladder torsion: case report and review of 245 cases reported in the Japanese literature. *J Hepato-Biliary-Pancreatic Sci.* 1999;6(4):418-21.
- Losken A, Wilson BW, Sherman R. Torsion of the gallbladder: a case report and review of the literature. *Ameri surg.* 1997;63(11):975-8.
- Garciavilla PC, Alvarez JF, Uzqueda GV. Diagnosis and laparoscopic approach to gallbladder torsion and cholelithiasis. *JSLs.* 2010;14(1):147.
- Younan G, Schumm M, Ali F, Christians KK. Gallbladder volvulus in a patient with type I choledochal cyst: a case report and review of the literature. *Case Reports in Surgery.* 2016;22:2016.
- Vedanayagam MS, Nikolopoulos I, Janakan G, El-Gaddal A. Gallbladder volvulus: a case of mimicry. *BMJ case reports.* 2013;17:2013:bcr2012007857.
- Janakan G, Ayantunde AA, Hoque H. Acute gallbladder torsion: an unexpected intraoperative finding. *World J Emergency Surg.* 2008;3(1):9.
- Wang GJ, Colln M, Crossett J, Holmes RA. "Bull's-eye" image of gallbladder volvulus. *Clinic Nuclear Medic.* 1987;12(3):231-2.
- Younan G, Schumm M, Ali F, Christians KK. Gallbladder Volvulus in a Patient with Type I Choledochal Cyst: A Case Report and Review of the Literature. *Case Reports in Surg.* 2016;22:2016.
- Usui M, Matsuda S, Suzuki H, Ogura Y. Preoperative diagnosis of gallbladder torsion by magnetic resonance cholangiopancreatography. *Scandinavian J Gastroenterol.* 2000;35(2):218-22.
- Reddy PK, Muralidharam M, Venkatasubram R. Laparoscopic derotation and cholecystectomy for torsion gallbladder. *JSLs.* 2005;9(2):238-40.
- Amarillo HA, Pirchi ED, Mihura ME. Complete gallbladder and cystic pedicle torsion Laparoscopic diagnosis and treatment. *Surgical Endoscopy and Other Interventional Techniques.* 2003;17(5):832-3.
- Nguyen T, Geraci A, Bauer JJ. Laparoscopic cholecystectomy for gallbladder volvulus. *Surgical Endoscopy.* 1995;9(5):519-21.
- Garciavilla PC, Alvarez JF, Uzqueda GV. Diagnosis and laparoscopic approach to gallbladder torsion and cholelithiasis. *JSLs.* 2010;14(1):147.

Cite this article as: Kumar R, Hastir A, Walia R, Goyal S. Volvulus of gall bladder -case report. *Int Surg J* 2017;4:3792-4.