

## Original Research Article

# A pilot study to evaluate the efficacy of fibrin glue in attaching full thickness skin graft in repair of cicatricial ectropion

Nitin V. Vichare\*, Jaswinder Singh

Department of Ophthalmology, Command Hospital (CC), Lucknow, Uttar Pradesh, India

**Received:** 14 July 2017

**Accepted:** 10 August 2017

**\*Correspondence:**

Dr. Nitin V. Vichare,

E-mail: [vicharenitin@yahoo.com](mailto:vicharenitin@yahoo.com)

**Copyright:** © the author(s), publisher and licensee Medip Academy. This is an open-access article distributed under the terms of the Creative Commons Attribution Non-Commercial License, which permits unrestricted non-commercial use, distribution, and reproduction in any medium, provided the original work is properly cited.

### ABSTRACT

**Background:** Traditionally, sutures are used to attach skin graft. Periocular skin reconstruction is peculiar in respect of constant movement of the graft bed due to lid movements. This study was aimed at evaluating the use of fibrin glue in skin graft for cicatricial ectropion.

**Methods:** This was prospective, non-randomized, interventional study. Total 10 patients with cicatricial ectropion were recruited. After dissection of scar, skin defect was covered with full thickness post auricular graft. Fibrin glue used to attach the graft over host bed. Bolster tied and bandage applied. Patients were evaluated for graft stability, opposition of graft host junction and graft uptake.

**Results:** The mean age was 30.9 years. Patients were divided into three groups i.e. 20-30 years, 30-40 years and 40-50 years. There were 05 patients (50%) in first group, 03 patients (30%) in second group and 02 patients (20%) in third group. Majority (90%) were male. Following injury 70% patients reported between 1-3 years. Grade 3 ectropion was most common (60%). Average duration of surgery was 79.3 min (standard deviation of 14.15 min). Horizontal dimensions of graft, 32 mm maximum and 26 mm minimum (average 29 mm). Vertical dimensions of graft, 18 mm maximum and 12 mm minimum (average 15 mm). Graft uptake was complete in all cases. No cases of graft infection or necrosis. However, 03 patients had residual ectropion.

**Conclusions:** Use of fibrin glue in attaching full thickness skin graft is an effective and safe technique with good uptake and stable graft host junction.

**Keywords:** Cicatricial ectropion, Fibrin glue, Skin graft

### INTRODUCTION

The term ectropion is derived from the Greek ek (away from) and tropein (to turn) and refers to any form of everted lid margin.<sup>1</sup> The eyelids are complex specialized facial adaptations designed to protect, moisten, and clean the ocular surfaces. The lids are covered anteriorly by skin and posteriorly by mucous membrane- the tarsal conjunctiva. They contain striated and smooth muscles, glands, blood vessels and nerves, all bound together by connective tissue. The eyelid can be divided into anterior

lamella formed by skin- orbicularis oculi muscle and posterior lamella formed by tarsus- conjunctiva. The physiological stability of eyelid is ensured by integrity of anterior lamella, posterior lamella and canthal tendons having fine equilibrium.<sup>1</sup>

Ectropion is commonly encountered in clinical practice and generally affects the lower eyelid.<sup>1,2</sup> Acquired form of ectropion can be involuntal, mechanical, cicatricial or paralytic.<sup>1</sup> Cicatricial ectropion of the upper or lower eyelid occurs following loss of skin (anterior lamella)

secondary to mechanical trauma, thermal or chemical burns, surgical trauma or chronic actinic skin damage.<sup>1-4</sup> Loss of apposition of lid margin to the globe leads to epiphora, chronic conjunctivitis and exposure keratitis.<sup>1-3</sup> Surgery is the mainstay of treatment of cicatricial ectropion and requires lengthening of the anterior lamella achieved by skin grafting.<sup>2,4</sup> Traditionally, sutures are used to keep the graft in place.

Tissue adhesives are used for closing and apposing wound edges quickly. In 1944 Tidrick RT first reported the use of fibrin glue to secure skin graft.<sup>5</sup> Subsequently, use of tissue adhesives has been tried for skin grafting by various authors.<sup>6-9</sup> Periocular skin reconstruction is peculiar in respect of thinness of the skin and constant movement of the graft bed due to eye lid movements. Sutures, including bed sutures, are used to prevent graft movement. Fibrin glue to attach skin graft in periocular skin reconstruction has not been used as it is thought that there is danger of rejection due to graft movement.

This study was aimed at evaluating the use of fibrin glue in attaching full thickness skin graft in periocular skin reconstruction.

**METHODS**

The study was conducted as a prospective, non-randomized, interventional study at a tertiary level hospital of Armed Forces from Aug 2014 to Aug 2016. The study proposal was evaluated and approved by institutional ethics committee.

Total 10 patients reporting to the ophthalmology department with cicatricial ectropion were recruited for this pilot study after obtaining informed consent. A comprehensive evaluation of patients was undertaken including patient’s age, gender, ocular history, nature of trauma, duration from initial event, slit lamp examination and anterior segment photography.

**Inclusion criteria**

- Cicatricial ectropion involving upper or lower lid
- Mature scar tissue or scar at least 6 months old
- Absence of bone fixation implants under scar tissue which may prevent graft uptake.

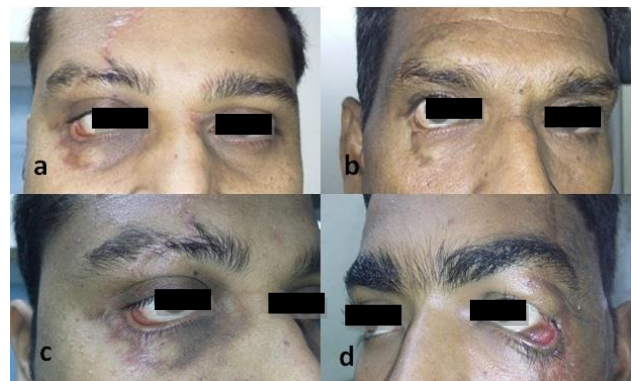
**Exclusion criteria**

- Congenital eyelid abnormality e.g. lid coloboma, ptosis
- History suggestive of any hypersensitivity to human blood products or any component of fibrin bio adhesive.

Parameters like epiphora, grade of ectropion and lagophthalmos were noted.

Ectropion was graded as (Figure 1, Figure 2 a, b)

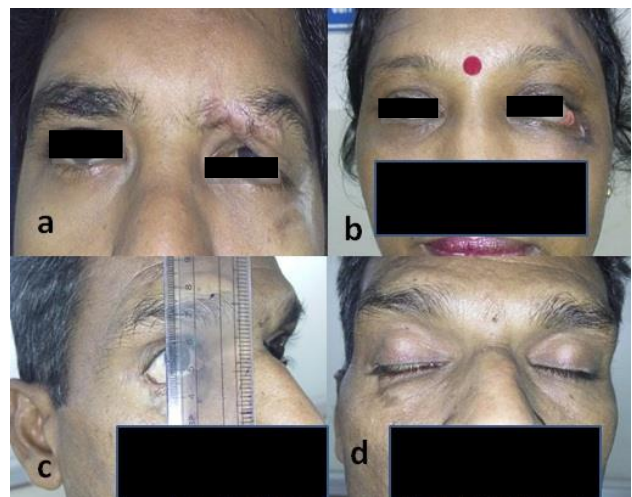- Grade 1- loss of punctal apposition
- Grade 2- posterior lid margin visible
- Grade 3- part of fornix visible
- Grade 4- complete fornix visible.



**Figure 1: a) Post traumatic cicatricial ectropion of lower lid, b) Grade 2 ectropion, c) Grade 3 ectropion, d) Grade 4 ectropion.**

Lagophthalmos was measured using a ruler after asking patient to close his eyelids gently and measuring maximal vertical distance separating eyelid margins (Figure 2 c, d). Lagophthalmos was graded as:

- Absent- 0 mm
- Mild- 1 mm
- Moderate- 2 mm
- Severe- > 3 mm.

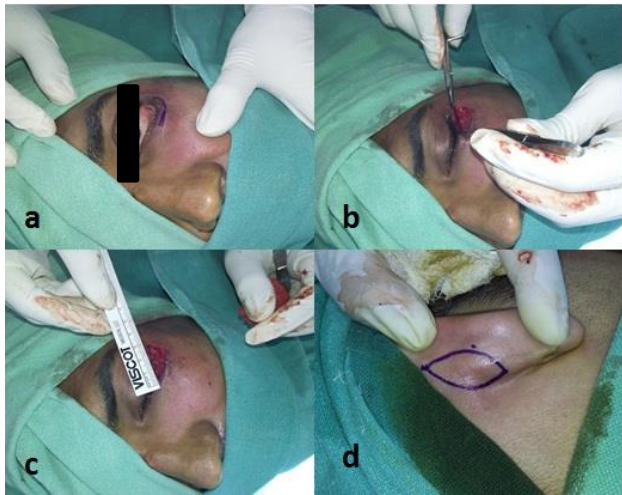


**Figure 2: a) Scar involving upper lid, b) Cicatricial ectropion in a young lady, c) and d) Lagophthalmos and its measurement.**

**Surgical steps**

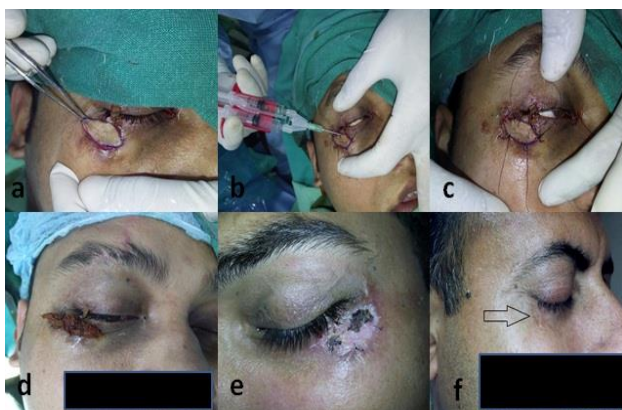All surgeries were performed under local anaesthesia after giving premedication in form Inj Promethazine HCL 0.5 ml (25 mg/ml) and inj pethidine HCL 0.5 ml (50 mg/ml) intra muscularly. Operative side was infiltrated

with mixture of 2% lignocaine with 1:10000 adrenaline. Sub ciliary incision marked with sterile skin marker 3 mm below lid margin of affected lid extending along the length of everted part (Figure 3 a). Incision made using no15 blade. Skin undermined and scar tissue released (Figure 3 b) until there was no tension on the surrounding tissues and lid margin sat on its normal anatomical position. Temporary tarsorrhaphy performed and skin defect measured in its horizontal and vertical extent (Figure 3 c).



**Figure 3: a) Marking of sub ciliary incision, b) Dissection of scar tissue, c) Measurement of skin defect, d) Harvesting of post auricular skin graft.**

Graft was harvested from post auricular region after adding additional 25% area in the defect measured to compensate for the graft contraction (Figure 3 d). Graft was defatted and thinned. Multiple full thickness punctures made in graft to allow for the increase in graft size as well as to allow drainage of serous fluid in graft bed. Graft placed on host bed (Figure 4 a).



**Figure 4: a) Graft placed over graft bed, b) Placing long sutures to tie bolsters, c) Application of fibrin glue, d) Bolster tied over graft.**

The mixing of Fibrin glue components (Tisseel fibrin sealant Baxter AG, Vienna, Austria) were done as per the

manufacturer's directions. The procedure requires the addition of the fibrinolysis inhibitor, aprotinin (small blue bottle) to the sealer protein concentrate vial (large blue bottle) followed by warming. The thrombin component is prepared by injecting the contents of calcium chloride vial (small black bottle) into the thrombin vial (large black bottle/white bottle).

Large black bottle causes rapid clot formation while with white bottle rate of clot formation is slow. In our technique, the white bottle was used always so that slow clotting will give enough time to the surgeon to align the graft while attaching. The vials are then warmed for several minutes and prepared solutions are drawn into two different syringes. These syringes are then placed into the duplojet injector which is specially designed so that depressing the common plunger exerts simultaneous and equal pressure on both the syringes. A mixer nosecone, topped by a blunt applicator needle, is attached to the nozzle to facilitate the mixing of the two syringe components.

With help of duplojet injector fibrin glue was spread over graft bed and at graft host junction (Figure 4 b). Edges of graft were held in opposition to the host skin margin with help of blunt tip forceps till the fibrin glue clots.

Four cardinal sutures applied with help of 6-0 silk at the edges of graft and ends of sutures kept long to tie bolster over graft for better apposition between graft and graft bed (Figure 4 c, d). No other sutures applied. A tight pad and bandage applied at the end of surgery. All patients were given broad spectrum antibiotics, oral analgesics and anti-inflammatory drugs.

*Post op visits*

Pad and bandage was removed after 48 hours. Bolster was kept moist with 5% betadine drops. Bolster was removed after 7 days. Post-operative visits were planned on day 2 (removal of bandage), day 7 (removal of bolster), day 15, day 30, day 90 and day 180. Patients were evaluated for graft stability, opposition of graft host junction and graft uptake (Figure 4 e, f).

**RESULTS**

This study included 10 patients cicatricial ectropion. The mean age of patients was 30.9 years with standard deviation 7.61 years.

**Table 1: Age wise distribution of patients.**

Age group (years)	No. of patients
20-30	05 (50%)
30-40	03 (30%)
40-50	02 (20%)

Based on age, patients were divided into three groups i.e. 20-30 years, 30-40 years and 40-50 years. There were 05

patients (50%) in age group 20-30 years, 03 patients (30%) in age group 30-40 years and 02 patients (20%) in age group 40-50 years (Table 1). Out of 10 patients, 09 (90%) were male. Right eye involvement seen in 06 patients (60%) while 04 patients (40%) had left eye involvement. Upper lid involved in only 01 patients (10%). Rest all patients (90%) had lower lid involvement.

Facial trauma involving skin around eyelid without involvement of lid margin was present in all cases. 01 patient had history of burns along with laceration of the periocular skin due to blast injury. Interestingly, 09 patients gave history that primary repair was done by general surgeon and not by ophthalmologist.

Interval between periocular injury and seeking ophthalmologist consultation for cicatricial ectropion was noted. 02 patients (20%) reported to ophthalmologist within one year following trauma. Majority of patients, 07 patients (70%) reported between 1-3 years following injury. 01 patient (10%) had cicatricial ectropion for more than 3 years duration.

**Grades of ectropion**

Grade 3 ectropion was most common and seen in 06 patients (60%). 03 patients (30%) had grade 4 ectropion while 01 patient (10%) had grade 2 ectropion. Grade 1 ectropion was not encountered in the study. Table 2 shows age wise distribution of grades of ectropion. Grade 3 ectropion was seen commonly in younger age group of 20-30 years. Measurement of lagophthalmos showed moderate amount was present in 7 patients while severe lagophthalmos seen in 2 patients with grade 4 ectropion.

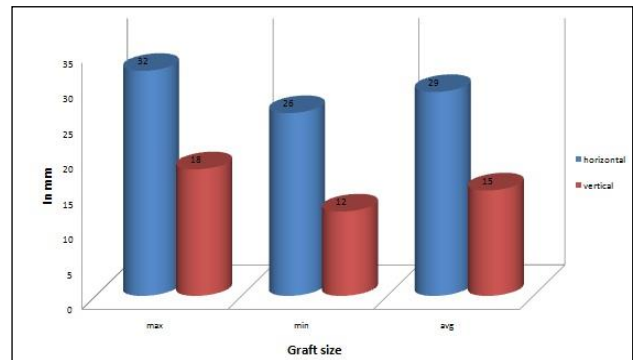
**Table 2: Age wise distribution of grades of ectropion.**

Age group (years)	Grade of ectropion			
	Grade 1	Grade 2	Grade 3	Grade 4
20-30	-	-	4	1
30-40	-	-	2	1
40-50	-	1	-	1

Surgeon noted the duration for the procedure including preparation of surgical site, dissection of scar tissue, harvesting donor skin from retro auricular area, closure of donor site, trimming of harvested skin, attaching donor skin to recipient bed with help of fibrin glue, placement of bolsters and application of tight bandage. Longest surgical duration was 96 min and shortest surgical time noted was 56 min. Average duration of surgery was 79.3 min with standard deviation of 14.15 minutes.

Dimensions of skin graft were noted. Maximum horizontal dimension of graft 32 mm and minimum horizontal dimension of graft 26 mm. Average horizontal dimension 29 mm. Maximum vertical dimension of graft

18 mm and minimum vertical dimension of graft 12 mm. Average vertical dimension 15 mm (Figure 5).



**Figure 5: Graft dimensions.**

Watering was a major complaint in all 10 patients (100%) pre-operatively. Post operatively, epiphora was completely cured in only 01 patient (10%). Majority of patients i.e. 07 patients (70%) had significant reduction in epiphora and it was not as disturbing as before surgery. But 02 patients (20%) continued to have disturbing epiphora even after 06 months post operatively. Discharge causing crusting and matting of eyelashes was present in 03 patients (30%) pre-operatively.

Post operatively, discharge was present in 02 patients at the end of 15 days follow up which continued on 30 days follow up. By 6 months, no patient had discharge from the operated eye. 02 patients who continued to have disturbing epiphora even after 06 months post operatively, did not have discharge from the eye.

Residual ectropion of any grade was looked for and documented. Bolster removed at day 7 post operatively and residual ectropion was checked at day 15 post-operative follow up. Out of 10 patients, 03 patients (30%) had residual ectropion at day 15 post-operative follow up. These patients continued to have residual ectropion at day 30, day 90 and at the end of 6 months follow up period. 01 patient had grade 1 residual ectropion and 02 patients had grade 2 residual ectropion.

Residual lagophthalmos was checked by instructing patient to close the eyelids. Post operatively, residual lagophthalmos was noted in patient with grade 2 residual ectropion. 02 patients had residual lagophthalmos at the end of 6 months follow up period (Table 3).

Post operatively, patients were evaluated for opposition of graft host junction, graft stability and graft uptake. Graft host junction apposition was checked on post-operative day 2 after removal of bandage with bolster in situ. Edges of graft beyond bolster were evaluated. Graft host junction apposition evaluated again on post-operative day 7 after removal of bolster.

**Table 3: Evaluation in post op visits.**

	No. of patients (pre-op)	Post op visit					
		Day 2	Day 7	Day 15	Day 30	Day 90	Day 180
Epiphora	10	10	10	07	03	03	02
Discharge	03	02	02	02	02	Nil	Nil
Residual ectropion	10	--	--	03	03	03	03
Residual lagophthalmos	10	--	--	02	02	02	02

Improper graft host junction apposition was not seen any patients in this series. Edges of graft were in good apposition under the bolster and by post-operative day 7 when bolsters were removed. Graft uptake was complete in all cases. No cases of graft infection or graft necrosis were encountered.

## DISCUSSION

Severe cicatricial ectropion of the lower lid creates a marked aesthetic deformity, poses a risk of corneal exposure and jeopardizes the patient's vision.<sup>3,10</sup> Management should combine limiting the damage due to exposure and lengthening of the cutaneous surface to reconstruct the lid. Non-surgical modalities like lubricating eye drops, use of moisture shields and taping gives temporary relief.<sup>11</sup> Surgical treatment forms the mainstay of management in cicatricial ectropion.

For localised scarring and skin shortage Z-plasty is preferred choice.<sup>1</sup> This procedure increases the length of skin in the line of scar contraction at the expense of shortening skin perpendicular to it. Various types of skin flaps like advancement flap, rotation flap, transposition flap, rhomboid flap, bilobed flap can be fashioned in periocular region utilising surrounding skin to cover the defect.<sup>12</sup> These flaps have some degree of their own blood supply and therefore heal faster. Skin grafting is indicated when there is generalised shortage of the skin.<sup>1,2,4,13</sup>

In cicatricial ectropion, full thickness skin grafting to replace deficient anterior lamella of lid is the preferred mode of treatment.<sup>1,10</sup> Preferred sites for harvesting the full thickness skin graft are eyelid skin from the same or contralateral eye, pre-and post-auricular region, supraclavicular region and inner part of the upper arm.

Traditionally, during skin grafting 6-0 braided silk sutures are used to suture the graft edges. However, using sutures presents several disadvantages, including complicated surgical technique, prolonged operation time, prolonged post-operative patient discomfort and suture related potential complications. To overcome these shortcomings tissue adhesives are being increasingly used. The two most commonly available tissue adhesives are- synthetic (commonest is n-butyl-2-cyanoacrylate) and biological (fibrin glue).<sup>14-16</sup> Fibrin glue is blood

derived product that is absorbable, relatively easy to use and can be kept at room temperature or in a refrigerator. In 1944 Tidrick used fibrin for skin graft fixation.<sup>5</sup> First use of fibrin glue in ophthalmology was reported by Katzin for attaching corneal transplants in rabbits.<sup>17</sup> Since then, fibrin glue has been used in various ophthalmic surgeries including pterygium, strabismic, glaucoma and vitreoretinal surgery.<sup>18-22</sup>

Use of fibrin glue has been showed to be effective in skin transplants.<sup>6-9,23</sup> However, periocular area poses a challenge during skin grafting due to constant movements of eyelid. There is a paucity of material on use of fibrin glue in eyelid reconstruction. Authors found just one reference in the literature where Osborne in 2010 evaluated the effectiveness of full thickness graft adhesion with fibrin glue in cicatricial ectropion and found it to be an effective technique.<sup>24</sup>

In this study, all patients who reported with cicatricial ectropion were below 50 years of age with majority of the patients in age group 20-30 years. This confirms trauma in young as the cause of cicatricial ectropion. One of the causes was trauma sustained trauma in road traffic accidents involving two-wheeler vehicles. This underlines the need for use of protective gear like helmets even for pillion riders. Lower lid involvement was present in majority of patients. This can be attributed to the fact that mobile upper lid has more lax skin around it than lower lid. Formation and contraction of scar tissue is more likely to pull the lower lid away from its normal anatomical position than the upper lid.

Interestingly, initial suturing of wound around periocular region in most cases was carried out by either general surgeon or medical officer as patients presented with polytrauma to accident and emergency dept. Wounds around periocular region needs closure in layers with attention to lid anatomy. Authors feel that suturing of such wounds should be done by ophthalmologists.

Average duration of surgery was 79.3 min. Though this study was non-comparative, authors observed that duration of surgery was greatly reduced compared to conventional technique of using sutures to attach skin grafts. Epiphora was present in all cases pre-operatively. Post operatively, majority of patients (07 patients) had significant reduction of epiphora but complete cure could

be obtained only in 01 patient. This shows that anatomical restoration does not correlate with physiological restoration.

Improper graft host junction apposition was not seen any patients in this series. Use of fibrin glue helped in smooth apposition of the edges. This study showed that fibrin glue can achieve excellent graft host junction apposition. Haematoma due to bleeding from host bed can lead to improper apposition and failure of graft uptake. No case of graft haematoma was seen in this study. Also graft uptake was complete in all cases. Studies have shown beneficial property of fibrin glue in achieving better haemostasis.<sup>15</sup> As per author's opinion this property helped in better apposition of graft to host bed and prevented graft loss or graft infection.

## CONCLUSION

Use of fibrin glue in attaching full thickness skin graft in periocular reconstruction is an effective and safe technique with good uptake of the skin graft, stable graft host junction and no postoperative haematoma or loss of graft.

*Funding: AFMRC project No 4558 /2014 granted and funded by the office of the DGAFMS, Government of India*

*Conflict of interest: None declared*

*Ethical approval: The study was approved by the institutional ethics committee*

## REFERENCES

- Collin JRO. Ectropion. In: A manual of systematic eyelid surgery. 3<sup>rd</sup> ed. Elsevier, 2006:57-84.
- Couch SM, Custer PL. Ectropion. In: Black EH, Nesi FA, Calvano CJ, Gladstone GJ, Levine MR eds. Smith and Nesi's Ophthalmic Plastic and Reconstructive Surgery, 3<sup>rd</sup> ed. New York: Springer; 2012:323-331.
- Astori IP, Muller MJ, Pegg SP. Cicatricial, post-burn ectropion and exposure keratitis. Burns. 1998;24:64-7.
- Rubin P, Mykula R, Griffiths RW. Ectropion following excision of lower eyelid tumours and full thickness skin graft repair. Br J Plast Surg. 2005;58(3):353-60.
- Tidrick RT, Warner ED. Fibrin fixation of skin transplants. Surg. 1944;15:90-5.
- Chakravorty RC, Sosnowski KM. Autologous fibrin glue in full-thickness skin grafting. Ann Plast Surg. 1989;23:488-91.
- Dahlstrom KK, Weis-Fogh US, Medgyesi S, Rostgaard J, Sorensen H. The use of autologous fibrin adhesive in skin transplantation. Plast Reconstr Surg. 1992;89:968-72.
- Adant JP, Detroz B, D'Silva M. Skin grafting with fibrin glue in burns. Eu J Plastic Surg. 1993;16:292-7.
- Foster K, Greenhalgh D, Gamelli RL. Efficacy and safety of a fibrin sealant for adherence of autologous skin grafts to burn wounds: results of a phase 3 clinical study. J Burn Care Res. 2008;29(2):293-303.
- Frueh BR, Schoengarth LD. Evaluation and treatment of the patient with ectropion. Ophthalmology 1982; 89:1049-54.
- La Piana FG, Irwin AE, Przybyla VA. Non-surgical management of postoperative cicatricial lower lid ectropion. Ophthal Plast Reconstr Surg. 1985;1(4):283-6.
- Sharma V, Bengner R, Martin PA. Techniques of periocular reconstruction. Indian J Ophthalmol. 2006;54:149-58.
- Johnson TM, Ratner D, Nelson BR. Soft tissue reconstruction with skin grafting. J Am Acad Dermatol. 1992;27(2):151-65.
- Trott AT. Cyanoacrylate tissue adhesives. An advance in wound care. JAMA. 1997;277:1559-60.
- Thompson DF, Letassy NA, Thompson GD. Fibrin glue: A review of its preparation, efficacy and adverse effects as a topical hemostat. Drug Intell Clin Pharm. 1988;22:946-52.
- Chan SM, Boisjoly H. Advances in the use of adhesives in ophthalmology. Curr Opin Ophthalmol. 2004;15:305-10.
- Katzin HM. Aqueous fibrin fixation of corneal transplants in the rabbit. Arch Ophthalmol. 1945;35:415-20.
- Panda A, Kumar S, Kumar A, Bansal R, Bhartiya S. Fibrin glue in ophthalmology. Indian J Ophthalmol. 2009;57:371-9.
- Zauberman H, Hemo I. Use of fibrin glue in ocular surgery. Ophthalmic Surg. 1988;19:132-3.
- Srinivasan S, Dollin M, McAllum P, Berger Y, Rootman DS, Slomovic AR. Fibrin glue versus sutures for attaching the conjunctival autograft in pterygium surgery: a prospective observer masked trial. Br J Ophthalmol. 2009;93:215-8.
- Erbil H, Sinav S, Sullu Y, Kandemir B. An experimental study on the use of fibrin sealants in strabismus surgery. Turk J Pediatr. 1991;33:111-6.
- O'Sullivan F, Dalton R, Rostron LK. Fibrin glue; an alternative method of wound closure in glaucoma surgery. J Glaucoma. 1996;5:367-70.
- Lilius P. Fibrin adhesive: its use in sealed skin grafting. Scand J Plast Reconstr Hand Surg. 1987;21:245-8.
- Osborne SF, Eidsness RB, Carroll SC, Rosser PM. The use of fibrin tissue glue in the repair of cicatricial ectropion of the lower eyelid. Ophthal Plast Reconstr Surg. 2010;26:409-12.

**Cite this article as:** Vichare NV, Singh J. A pilot study to evaluate the efficacy of fibrin glue in attaching full thickness skin graft in repair of cicatricial ectropion. Int Surg J 2017;4:3052-7.