

Original Research Article

Comparison of conventional closure versus “re-modified Smead Jones” technique of single layer mass closure with Polypropylene (prolene) loop suture after midline laparotomy in emergency cases

Raxith Sringeri*, Thulasi Vasudeviah

Department of General Surgery, JSS University, Mysore, Karnataka, India

Received: 12 July 2017

Accepted: 09 August 2017

***Correspondence:**

Dr. Raxith Sringeri,

E-mail: raxith25@gmail.com

Copyright: © the author(s), publisher and licensee Medip Academy. This is an open-access article distributed under the terms of the Creative Commons Attribution Non-Commercial License, which permits unrestricted non-commercial use, distribution, and reproduction in any medium, provided the original work is properly cited.

ABSTRACT

Background: The occurrence of sudden disruption of the abdominal laparotomy wound is a major disaster in the life of a patient who has undergone an abdominal operation and a major psychological blow to the patient as well as the surgeon.

Methods: 100 consecutively enrolled patients who underwent emergency midline laparotomies were enrolled in the study who were admitted in Department of Surgery, JSS University, Mysore and intra-operatively randomized into two groups in 1:1 pattern.

Results: The total number of patients who underwent laparotomy for generalized peritonitis in 2 years was 100. The post-operative wound infection rate in Group A was 32.4% and in Group B was 12.3% ($p = 0.03$) and 95% CI (1.083-7.326).

Conclusions: Present study concluded that the modified version of Smead-Jones techniques of laparotomy closure with prolene loop had very low incidence of early and may reduce the late complications. It was superior to other conventional methods of closure.

Keywords: Incisional hernia, Laparotomy, Smead Jones, Wound dehiscence

INTRODUCTION

The occurrence of sudden disruption of the abdominal laparotomy wound is a major disaster in the life of a patient who has undergone an abdominal operation and a major psychological blow to the patient as well as the surgeon.¹ The partial or complete postoperative separation of abdominal wound closure is known as wound dehiscence or acute wound failure.¹ Acute wound failure is defined as postoperative separation of the abdominal musculoaponeurotic layers, within 30 days after operation and requires some form of intervention, usually during the same hospitalization.¹ Most bursts occur between the 6th and 9th postoperative day.²

The integrity of the sutured abdominal wound rests on a balance between the suture holding capacity of tissues and tissue holding capacity of sutures.² Numerous clinical trials have compared layered to mass abdominal closure. Some studies have shown an increased incidence of burst abdomen and incisional hernia with layered closure, and some studies show no difference in these complications, but no studies demonstrate an advantage of layered over mass closure.³ With recent advances in suture material and the use of mass closure technique the rate of dehiscence has generally been less than 1%, although a recent report from the Veterans affairs national quality program has documented a rate of 3.2%. The prevalence of wound disruption in Indian scenario is reported to

range from 10-30% for emergency cases and 0-5% for elective cases.⁴

We commonly use the conventional method of closure which includes fascial closure which may be layered fascial closure or mass fascial closure, subcutaneous closure followed by skin closure. We planned a randomized controlled trial to compare two different abdominal closure techniques to reduce the incidence of wound disruption following midline laparotomy incisions in our teaching institution. We advocated modified Smead Jones closure which includes a series of far-near-near-far within single loop of PDS suture whereby the tension load of suture is distributed both along and across the suture line. We randomized two groups in 1:1 in which, Group A constituted conventional abdominal closure Group B constituted modified Smead Jones closure (far-near-near-far) and studied on 100 patients who underwent midline laparotomies for different emergency indications.

METHODS

100 consecutively enrolled patients who underwent emergency midline laparotomies were enrolled in the study who were admitted in Department of Surgery, JSS University, Mysore and intra-operatively randomized into two groups in 1:1 pattern. Ethical clearance obtained from the Institutional Ethical Committee. Study design was single centric prospective study.

Inclusion criteria

Generalized peritonitis irrespective of the cause and emergency laparotomy by midline incision in cases with delayed presentation (24 hours after onset).

Exclusion criteria

Elective laparotomy and patients with diabetes and proven malignancy

Suture: Polypropylene (prolene) no.1 loop was used in both techniques.

Patients were included in two groups: Group 'A' and Group 'B'. Group A includes those patients who underwent conventional closure with polypropylene number 1 size loop suture. Conventional closure included closure of rectus fascia with muscle first in a continuous fashion. The sutures were placed 2 cm from the edge of the linea alba on both sides and 1 cm was maintained between two adjacent sutures. Following this skin was closed with interrupted ethilon 2-0 sutures (Figure 1).

Group B includes those patients who underwent modified Smead Jones "far-near-near-far" technique of abdominal wall closure. This technique includes suture approximation of rectus sheath with peritoneum and muscle in one layer, in a continuous fashion. The entry

and exit of prolene was 2 cm from the wound edges and 1 cm from the edge of linea alba on either side. The distance between two adjacent sutures was 3 cm (Figure 2). The skin was sutured separately. Primary outcome measures the incidence of wound infection and abdominal wall dehiscence at the end of 15 days by the evaluating surgeon.

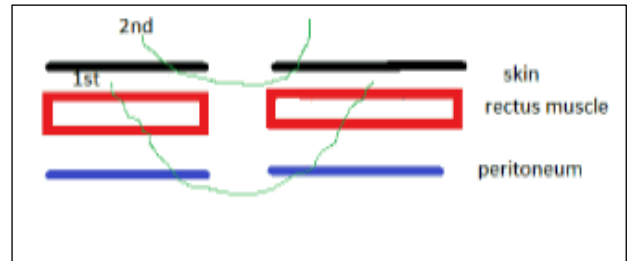


Figure 1: Conventional closure.

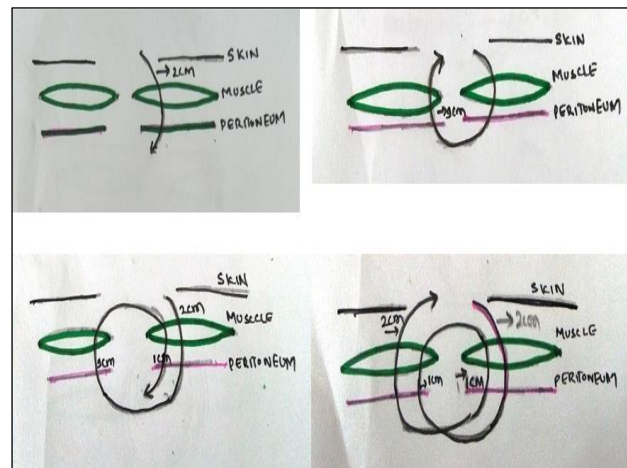


Figure 2: Far-near-near-far suture.

Follow up: All patients were discharged after suture removal on 10th postoperative day and were followed on 15th day and then monthly up to 6months year.

RESULTS

The total number of patients who underwent laparotomy for generalized peritonitis in 2 years was 100. Among them 50 patients underwent conventional mass closure and were included in Group A and 50 number of patients underwent technique as mentioned for Group B.

Mean age of patients in Group A was 44 years and 46 years in Group B. Males were more common than females. Among the causes of peritonitis, duodenal ulcer perforation was the most common followed by post traumatic hollow viscous perforation. Among these post-traumatic perforations, those involving small intestine (jejunum followed by ileum) was more than large bowel perforation. The third common cause was perforation of appendix with generalized peritonitis secondary to intra-abdominal abscess (Table 1).

Table 1. Comparison of various causes for laparotomy in Group A and B and the outcomes.

Surgery done for/outcomes	Group A	Group B
Duodenal perforation	26	27
Traumatic jejunal/ ileal perforation	9	9
Colon injury	6	9
Appendicular perforation peritonitis	5	3
Strangulated (perforated) hernia	2	1
Necrotizing pancreatitis	2	2
Total number of patients	50	50

The post-operative wound infection rate in Group A was 32.4% and in Group B was 12.3% ($p = 0.03$) and 95% CI (1.083-7.326). This was statistically significant. Wound dehiscence was noted in 14.9% in Group A and 1% in patients of Group B ($P = 0.01$). Odd ratio was 3.2. This was also shown to be statistically significant. The mean hospital stay in Group A was 15 days and 20 days in Group B.

Table 2: Complication between two groups.

Complications	Group A	Group B
Wound infection	32.4%	12.3%
Wound dehiscence	14.9%	1%
Mean hospital stay (days)	15	20

All wound dehiscence seen in Group A underwent emergency mass closure with the technique in Group B. Among these, 4 patients had wound infection which improved with conservative measures. None of them developed re-dehiscence. However, these patients were not included in Group B.

Group A and Group B came for third follow up for 6 months and none of these had any complications like incisional hernia. 12 patients (Group A: 8 and Group B: 4) were lost to follow up.

DISCUSSION

Acute wound failure is one of the major complications following laparotomy with significant morbidity and mortality.³ The prevalence of disease has varied with time and geographical location. The increase in the prevalence of wound dehiscence in recent studies is actually due to the fact that recently sicker patients with multiple risk factors are being operated and most cases follow emergency laparotomy for peritonitis. It usually manifests when there is a sudden rise in intra-abdominal pressure like vomiting, coughing, retching or sneezing. A pink sero-sanguinous discharge from the laparotomy wound in 23% to 84% patients and a sensation of something giving way in abdomen are indicators for burst.⁵

The ideal fascial closure should maintain tensile strength throughout the healing process. The dynamic process of wound healing can be divided into three phases. The first exudative phase (days 1-4) does not provide any holding strength to the wound. It is followed by the proliferative phase (days 5-20), in which the tissue regains approximately 15-30% while up to 80% of its original tensile strength is regained in the third or remodeling phase (days 21 onwards). It was demonstrated in the early 1950s that the healing process of abdominal fascia after surgical incision continues for 9 to 12 months. Abdominal fascia regains only 51% to 59% of its original tensile strength at 42 days, 70% to 80% at 120 days, and 73% to 93% by 140 days.⁶⁻⁸

Sutured wound bursts because either the suture breaks or its knot slips or it cuts through the tissues. Generally, the first 2 reasons are rare, and wound dehiscence occurs when the suture material tears through the fascia. The strength of a particular suture material increase as its cross-sectional diameter increases and smaller diameter sutures are associated with a greater likelihood of tearing through the tissue.^{7,8} It has been shown experimentally by Jenkins that the length of a midline laparotomy incision can increase up to 30% in the postoperative period in association with several factors that increase the intra-abdominal pressure and determined that a suture length-to-wound length ratio should be 4:17.⁹ A meta-analysis on 23 randomized trials showed that odds of burst are reduced to half with interrupted method of closure compared to continuous method. In emergency surgery, interrupted sutures are better than continuous method as they have “gigli saw” or “hack saw” effect. In conventional abdominal closure, the primary advantage of layered closure is that as individual fascial layer is sequentially closed, the multiple strands exist, so that if a break, the incision is held intact by the remaining sutures. Whereas, continuous fascial mass closure with a single closure allows the even tension distribution across the entire length of the suture which results in minimization of tissue strangulation. But, excessive tension if applied in layered closure, leads to tissue necrosis and resultant failure of closure.^{9,10} Agrawak CS et al, has concluded that interrupted abdominal wall closure prevents burst abdomen, in his randomized controlled trial comparing interrupted X and conventional continuous closures in surgical and gynaecological patients.¹¹ We did a prospective study by comparing between conventional abdominal closure and modified Smead Jones closure method.

It is sad that in Asian countries the incidence of abdominal wound dehiscence is still very high and stays above the 10% level due to widely prevalent malnutrition and the lack of proper health care delivery system providing emergency surgical treatment.¹¹ The operation at the rural and suburban level may be often delayed for a day or more resulting in much tissue necrosis of the linea alba as well as more marked systemic inflammatory

response syndrome adversely affecting healing and collagen synthesis.^{9,12}

In an attempt to decrease these complications, we adopted the technique of single layer mass closure in which all the layers of the abdominal wall are approximated by “far-near and near-far” technique. This technique is to some extent similar to and is influenced by the Smead-Jones technique of abdominal fascia mass closure by the far-far and near-near technique.

Though this technique modified variant of Smead Jones closure with continuous loop sutures placed and in our technique, there are no additional fascia closure sutures and “far-near and near-far”, sutures are the only sutures approximating the fascia.

Our modified version of Smead Jones method of abdominal closure with prolene loop suture is advantageous in sequential closure with even distribution of suture tension thereby efficacious in prevention of abdominal dehiscence and later incisional hernias. According to us, modified Smead method of closure can be used as a preferential method of abdominal wall closure in all midline laparotomy incisions, even in cases more prone for abdominal dehiscence due to patient factors such as abdominal sepsis.

The limitation of our study was longer hospital stay: as most of our patients are from far-off rural areas, they preferred to stay in the hospital till the sutures were removed. Inadequate follow up: we could not assess for incisional hernia for the very same reasons that most of our patients are poor, lived far away and unable to come for follow up.

CONCLUSION

All the patients with generalized peritonitis in emergency setting need special attention regarding the wound closure. This newer technique of midline emergency laparotomy wound closure, especially in Indian setup significantly reduces the incidence of wound infection and wound dehiscence. Our study concluded that the modified version of Smead-Jones techniques of laparotomy closure with prolene loop had very low incidence of early and may reduce the late complications. It was superior to other conventional methods of closure.

ACKNOWLEDGMENTS

Authors would like to thank the JSS University for providing them the platform for conducting the work. Authors like to thank HOD and all their senior colleagues in Department of Surgery. Above all authors are very grateful for all the patients involved in this study.

Funding: No funding sources

Conflict of interest: None declared

Ethical approval: The study was approved by the institutional ethics committee

REFERENCES

1. Van't Riet M, Steyerberg EW, Nellensteyn J, Bonjer HJ, Jeekel J. Meta-analysis of techniques for closure of midline abdominal incisions. *Br J Surg.* 2002;89(11):1350.
2. Gislason H, Viste A. Closure of burst abdomen after major gastrointestinal operations: comparison of different surgical techniques and later development of incisional hernia. *Eur J Surg.* 1999;165:958.
3. Wadstrom J, Gerdin B. Closure of the abdominal wall; how and why? Clinical review. *Acta Chir Scand.* 1990;156:75.
4. Goligher JC, Irvin TT, Johnston D, De Dombal FT, Hill GL, Horrocks JC. A controlled clinical trial of three methods of closure of laparotomy wounds. *Br J Surg.* 1975;62:823.
5. Bucknall TE, Ellis H. Abdominal wound closure: a comparison of monofilament nylon and polyglycolic acid. *Surg.* 1981;89:672.
6. Richards PC, Balch CM, Aldrete JS. Abdominal wound closure. A randomized prospective study of 571 patients comparing continuous versus interrupted suture techniques. *Ann Surg.* 1983;197:238-43.
7. Rahman A. Spontaneous ileal perforation: an experience of 33 cases. *J Postgrad Med Inst.* 2003;17:105-10.
8. Wong SY, Kingsnorth AN. Abdominal wound dehiscence and incisional hernia. *Surg.* 2002;20:100-3.
9. van t Riet M, de vos van Steenwijk PJ, Bonjer HJ. Incisional hernia after repair of wound dehiscence: Incidence and risk factors. *Am Surg.* 2004;70:281-6.
10. Mingoli A, Puggioni A, Sgarzini G, Luciani G, Corzani F, Ciccarone F, et al. Incidence of incisional hernia following emergency abdominal surgery. *Ital J Gastroenterol Hepatol.* 1999;31:449-53.
11. Whipple AO, Elliott RHE Jr. The repair of abdominal incisions. *Ann Surg.* 1938;108:741-56.
12. van Os JM, Lange JF, Goossens RH, Koster RP, Burger JW, Jeekel J, et al. Artificial midline-fascia of the human abdominal wall for testing suture strength. *J Mater Sci Mater Med.* 2006;17:759-65.

Cite this article as: Sringeri R, Vasudeviah T. Comparison of conventional closure versus “re-modified Smead Jones” technique of single layer mass closure with Polypropylene (prolene) loop suture after midline laparotomy in emergency cases. *Int Surg J* 2017;4:3058-61.