

## Original Research Article

# Study of different surgical management approach in lower limb varicose veins at tertiary care hospital

Mohd Shafiuddin<sup>1\*</sup>, T. P. Bhavanishankar<sup>2</sup>

<sup>1</sup>Associate Professor, Department of Surgery, Gulbarga Institute of Medical Sciences, Gulbarga, Karnataka, India

<sup>2</sup>Professor, Department of Surgery, KIMS, Hubli, Karnataka, India

**Received:** 28 June 2017

**Accepted:** 11 July 2017

### \*Correspondence:

Dr. Mohd Shafiuddin,

E-mail: [drmohdshafi@hotmail.com](mailto:drmohdshafi@hotmail.com)

**Copyright:** © the author(s), publisher and licensee Medip Academy. This is an open-access article distributed under the terms of the Creative Commons Attribution Non-Commercial License, which permits unrestricted non-commercial use, distribution, and reproduction in any medium, provided the original work is properly cited.

## ABSTRACT

**Background:** The present study was conducted with the aim to evaluate the clinical features and management of varicose veins in terms of recurrence and symptoms improvement.

**Methods:** This clinical study was conducted for a period of two years during January 1990 to February 1992. A total of 21 patients who presented with symptoms of varicose veins in lower extremities to Karnataka Medical College Hospital Hubli were involved in the study. After thorough clinical examination and investigation all the patients are subjected to relevant treatment.

**Results:** Long saphenous system is the most common venous system affected by varicosity in 18 (85.7%) cases. Incompetence of perforator veins was seen in about 20 (95.3%) cases. Trendelenburg's operation was done in all cases of long saphenous involvement. Sub fascial ligation of perforators was done in 2 patients. Wound infection is the common postoperative complication observed in 5 patients. Preoperative stay in hospital was longer in patients with ulcer (13 days), whereas patients with postoperative wound infection (14 days) had longer postoperative stay.

**Conclusions:** This study showed that the prevalence of lower limb varicose veins has a male predominance and is more common in younger age group. Occupation involving standing for longer periods of time is one of the important contributing factors in the development of varicosities. There is no single method of appropriate treatment for all cases. Multiple ligations of saphenous vein and excision of varicose tributaries were done in 9 patients. If cases are selected properly with good operative technique the complications are negligible.

**Keywords:** Complications, Long saphenous, Trendelenburg's operation veins, Varicose veins

## INTRODUCTION

Varicose veins are a common medical condition and can cause disability and disturbance in leading the quality of life.<sup>1</sup> It was seen in at least 10-30% of the general population.<sup>2</sup> The symptoms of varicose veins range from asymptomatic varicose veins to more severe complications such as discomfort, pain, itching, eczema and deep vein thrombosis.<sup>3</sup> Varicose veins may cause significant morbidity including spontaneous bleeding, ulceration, dermatitis, superficial thrombophlebitis, ankle

edema and lipodermatosclerosis.<sup>4</sup> The possible risk factor for varicose veins is standing for a long period of time and other risk factors include age, family history and pregnancy.<sup>5</sup>

Varicose veins were familiar pre-historically and many developments were made regarding the diagnosis and management of varicose veins by phlebologists including many bandaging techniques, ligation and stripping of veins.<sup>6</sup> The attention was mainly towards the mechanical effects of the varicosity rather than the basic cause. It is

only in the recent past that considerable knowledge has been gained concerning the anatomy of the venous system of the leg, the physiological mechanism of venous return to the heart against gravity and pathology of the disorder, which has led to many newer modalities of investigations and treatment.

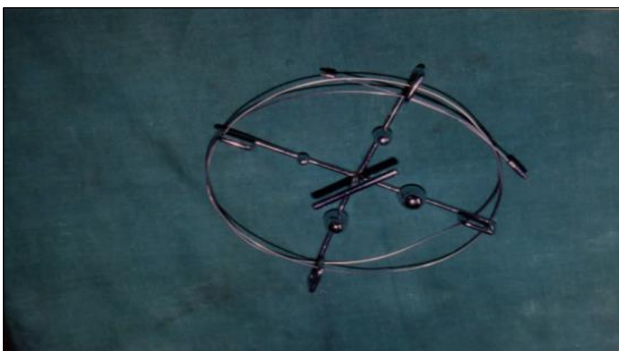
There is no single applicable method for treating the range of manifestations of varicose veins. The management alternatives for lower limb varicose veins includes Trendelenburg operation, stripping, sub-fascial ligation of perforators, laser, sclerotherapy, subfascial endoscopic perforator surgery and radiofrequency ablation.<sup>7</sup>

The investigation for more effective means of diagnosing and treating the varicose veins and prevention and management of its complications continues and this study aims at studying the clinical features, and management of varicose veins of lower limbs.

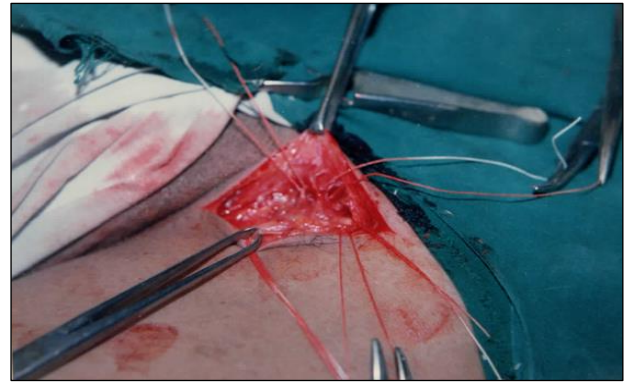
## METHODS

This was clinical study involving 21 patients who presented with symptoms of varicose veins in lower extremities to Karnataka Medical College Hospital Hubli, during the period from January 1990 to February 1992. Complete data of the patient including age, sex, occupation, hereditary tendency, previous history regarding the deep vein thrombosis and any other major illness or trauma were noted. The presenting complaints were recorded in detail in the chronological order.

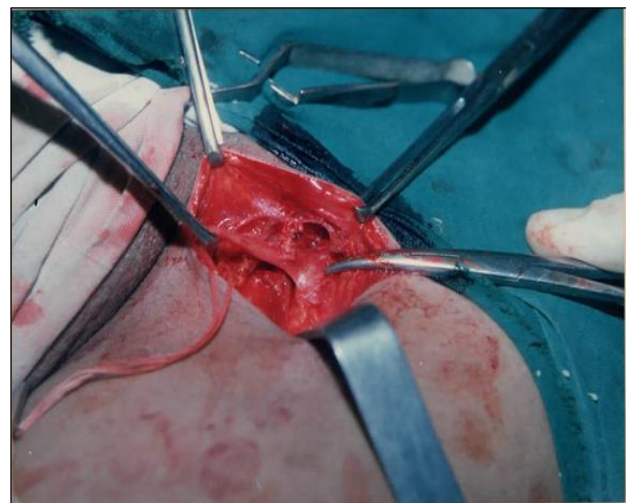
After obtaining an adequate history, the patient was examined in standing position with good illumination, exposing both the lower limbs completely. The following tests were performed: Brodie-Trendelenburg test, Schwartz test, Morrissey's cough impulse test, Parthe's test, multiple tourniquet test. The result of the tests was noted according to the clinical proforma. Surgery was done in 20 cases with associated ulcers. So, in those cases conservative treatment was given before surgery. In one patient where deep vein thrombosis was present, only conservative treatment was given.



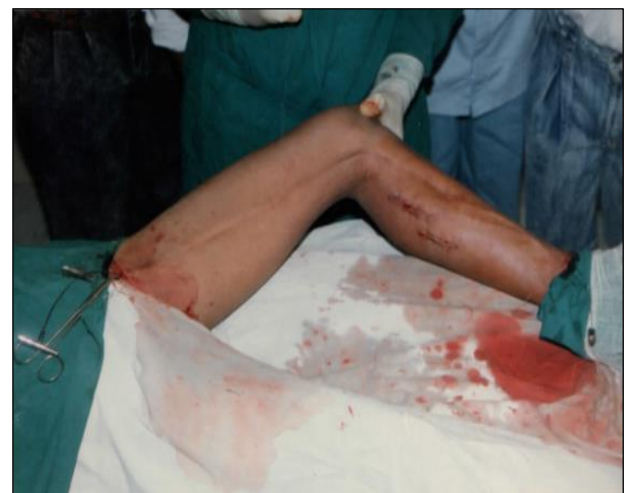**Figure 1: Meyer's stripper.**



**Figure 2: Sapheno-femoral junction with terminal tributaries shown.**



**Figure 3: Sapheno-femoral junction exposed.**



**Figure 4: Mayre's stripper introduced.**

Patients of both sexes aged between 15-70 years were included in the study. Patients of age less than 15 or more than 70 and patients not willing to get follow up were excluded from the study.

### Statistical analysis

The data obtained was represented as percentages and was represented in the form of tables.

## RESULTS

During study period 968 patients were admitted for surgical treatment of vascular ailments and varicose veins accounted for 21 (2.16%). Socio-demographic and clinical features of the study participants was presented in Table 1. Majority of the patients with varicosities in the lower limb were under the age group of 21-30 years. Male preponderance was observed.

**Table 1: socio-demographic characters and clinical features of the study participants (n=21).**

Variables	No. of patients (%)
<b>Age in years</b>	
10-20	2 (9.52)
21-30	9 (42.84)
31-40	5 (23.84)
41-50	3 (14.28)
51-60	1 (4.76)
61 and above	1 (4.76)
<b>Sex</b>	
Males	20 (95.3)
Female	01 (4.7)
<b>Occupation</b>	
Agriculture	6 (28.56)
Hotel worker	5 (23.84)
Coolie	4 (19.04)
Student	1 (4.76)
House wife	1 (4.76)
Shop assistant	2 (9.52)
Weaver	1 (4.76)
Clerk	1 (4.76)
<b>Presenting complaints</b>	
Prominent veins	3 (14.28)
Pain and prominent veins	10 (47.64)
Prominent veins and ulcer	2 (9.52)
Prominent veins and swelling of limb	1 (4.76)
Prominent vein, pain and ulcer.	1 (4.76)
Ulcer	2 (9.52)
Bleeding	1 (4.76)
Prominent vein, swelling of limb and pain	1 (4.76)
<b>Limbs involved</b>	
Isolated right lower limb	9 (42.86)
Isolated left lower limb	9 (42.86)
Both limbs	3 (14.28)
<b>Venous system involved</b>	
Long saphenous system	18 (85.72)
Short saphenous system	-
Both long and short saphenous system	3 (14.28)

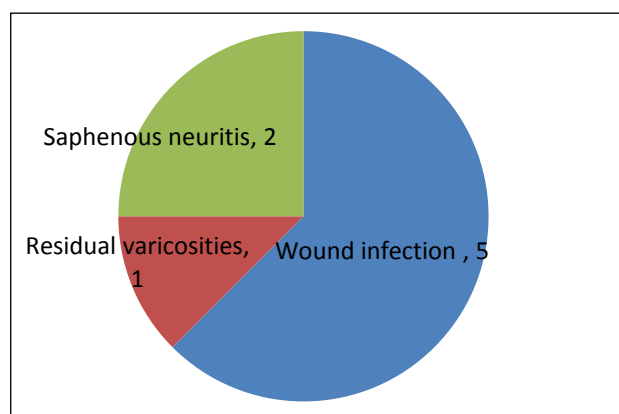
Majority 18 (85.7%) of the patient's occupation was involved in prolonged periods of standing and violent muscular efforts. The most common symptom observed in majority of the patients 10 (47.64%) was pain and prominent veins. In 18 patients, equal distribution of varicosities was observed in left 9 (42.86%) and right side 9 (42.86%) of lower limbs respectively.

Long saphenous system is the most common venous system affected by varicosity 18 (85.7%). Incompetence of perforator veins was seen in about 20 (95.3%) cases.

In this study surgery was done in 20 cases. Surgical modality was selected on the basis of severity of the disease detected clinically as shown in Table 2. All the cases except those associated with ulcer were treated by surgery only and in remaining cases conservative treatment was given prior to surgery. The conservative treatment involved (a) elastocrepe bandaging from the toes to the groin when patient was ambulatory (b) elevation of the limb during sleeping hours (c) antibiotics (d) dressing and (e) exercises. The duration of treatment varied from patient to patient. Conservative therapy was continued till the ulcer healed. One case was associated with deep vein thrombosis and was treated conservatively only.

**Table 2: Operative procedures employed in the study (n=21).**

Surgical procedures	No. of patients (%)
Trendelenburg's operation	1 (5)
Trendelenburg's operation with stripping	1 (5)
Trendelenburg's operation with multiple ligation and excision of varicose tributaries.	9 (45)
Trendelenburg's operation with stripping of long saphenous vein and sub fascial ligation of perforator.	7 (35)
Sub fascial ligation of perforators	2 (10)

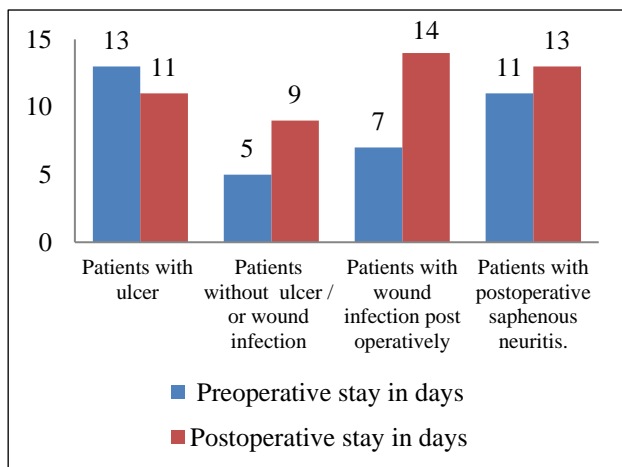


**Figure 1: Postoperative incidence of complications (n=21).**

Trendelenburg's operation was done in all cases of long saphenous involvement. Seven cases were subjected to stripping of the long saphenous system. In 6 cases, whole length of long saphenous vein was removed and in one case it was removed upto knee level. Sub fascial ligation was done in two cases. Multiple ligation and excision of the large varicose tributaries were done. 6 cases were associated with varicose ulcer. All the cases were treated conservatively before surgery. In one case skin grafting was done to make the ulcer heal. Postoperatively complications were noticed in 8 patients. Wound infection was the common complication observed in 5 (62%) cases (Figure 1).

They were treated by antibiotics after pus-culture and sensitivity. This made the few patients to stay longer in the hospital. One patient had residual varicosity of veins. But the patient refused for repeat surgery. Two patients had saphenous neuritis and were treated conservatively, both these patients had under gone vein stripping from below upwards.

Number of days of hospital stay pre-and postoperatively was given in Figure 2. Preoperative stay in hospital was longer in patients with ulcer. Whereas patients with postoperative wound infection and saphenous neuritis had longer postoperative stay.



**Figure 2: Showing number of days of hospital stay.**

## DISCUSSION

Varicose veins of the lower extremities are the most common peripheral vascular diseases. By definition they are dilated, elongated and tortuous veins.<sup>8</sup> In the present study, the higher incidence of varicose veins was observed between the age group 20-40 years which correlates well with the studies of Janugade et al and Vaidyanathan et al.<sup>9,10</sup> Males 20 (95.3%) are commonly affected than females in this study. Similar observations were seen in the studies of Nagaraj et al.<sup>11</sup> This variation might due to the factor that cosmesis is not concern for low and middle-class women in our country, only complications associated with the disease makes the

patient to consult the doctor. On contrary, a study by Callum showed women to be more affected than men.<sup>12</sup>

In this study, 18 (85.7%) of the patients exhibit a definite history of standing for long duration. This is keeping with the widely held presumption that occupations involving prolonged periods of standing and/or violent physical effort could lead to varicose veins. Similar findings were noted by the Mirji et al.<sup>13</sup> In this series, left side limb involvement was seen in 9 (42.86%) and right side in 9 (42.86%) cases. Both limbs were involved in 3 (14.28%) cases. Study by Prasad et al showed that right side limb involvement was seen in 28 (56%) cases and left side in 20(40%) cases and in 2 (4%) both limbs were involved.<sup>14</sup>

In the present study, the most common symptoms were pain and prominent veins in 10 patients and thus majority of the patients seek medical help for complication of the varicose veins. These findings correlate well with other studies done by Cambell et al, with aching pain in 57% patients.<sup>15</sup> The present study noted long saphenous vein involvement in most 18 (85.7%) of the cases followed by both long and short saphenous vein involvement in 3 (14.28%). These observations are in accordance with the findings of Janugade et al and Naik et al.<sup>9,16</sup>

In this present study 95.23% of patients had perforator incompetence. Which shows that majority of the cases presenting to hospital for treatment are advanced cases of hemodynamic disturbances of the limb and it is compared with study conducted by Donnell et al where 79.48% of patients had perforator in competence.<sup>17</sup>

Varicose veins are a progressive disease, the precise etiology for which is not known. Thus, the therapy in vogue can be said to be symptomatic rather than curative. Post-operative follow up is mandatory because the treatment is not curative and the disease is progressive. There is no single appropriate method for treating varicose veins. The individual surgical procedure was decided upon in each case taking into consideration involvement of the saphenous system, presence of incompetent perforators, sapheno femoral in competence and complicating factors like edema ulceration. In The present study out of 21, 20 patients were having associated ulcers. They managed conservatively initially and then followed by surgery.

Incompetent sapheno femoral valve was tackled by Trendelenburg's operation. Incompetent perforators are managed by subfascial ligation or by stripping. The bulk of the varicose veins were tackled by multiple ligation alone or by multiple ligation and excision. If residual veins were present was treated by multiple ligation. These procedures were done individually or in combination with other procedures depending on the venous system involved.<sup>9</sup>

In the present study, ligation of saphenous vein was done in 1 (5%) patient, ligation with stripping in 1 (5%) case,



multiple and excision of varicose tributaries in 9 (45%) cases. Stripping of long saphenous vein and sub fascial ligation of perforator in 7 (35%) and sub fascial ligation of perforators in 2 (10%) cases.

All the patients were cured of their varicosities except one, who had residual varicosity over the back of the leg for which he was advised re-operation. But the patient refused surgery. Patients could not be followed up for long period of time as they were not turned up.

The complications of varicose vein surgeries are very rare. In the present study, wound infection was the major complication noted in 5 patients. Similar observation was made by Janugade et al in his study.<sup>9</sup>

## CONCLUSION

Our study shows the prevalence of varicose veins of lower limbs is more in younger people with occupations involved in prolonged standing and strenuous work. Males are more affected than females. Surgery is the only choice of treatment for varicose veins associated with ulcers in lower limbs and different surgical procedures were adopted. Operating procedures depend on the involvement of the saphenous system, presence of incompetent perforators, sapheno femoral in competence and complications. The present procedures adopted for the surgery in the present study enabled the patient to lead almost normal life after surgery.

*Funding: No funding sources*

*Conflict of interest: None declared*

*Ethical approval: The study was approved by the institutional ethics committee*

## REFERENCES

1. Subramonia S, Lees TA. The Treatment of Varicose Veins. Ann R Coll Surg Engl. 2007;89(2):96-100.
2. Evans CJ, Fowkes FG, Ruckley CV, Lee AJ. Prevalence of varicose veins and chronic venous insufficiency in men and women in the general population: Edinburgh Vein Study. J Epidemiol Community Health. 1999;53(3):149-53.
3. Ren S, Liu P. Initial clinical experiences in treating 27 cases of varicose veins with EVLT plus TRIVEX. J US China Med Sci. 2005;2(1):4-8.
4. Stephen C. Nicholls. Sequelae of Untreated Venous Insufficiency. Semin Intervent Radiol. 2005;22(3):162-8.
5. Liu P, Ren S, Yang Y, Liu J, Ye Z, Lin F. Intravenous catheter-guided laser ablation: a novel alternative for branch varicose veins. Int Surg. 2011;96(4):331-6.
6. Van den Boezem PB, Klem TM, le Cocq d'Armandville E, Wittens CH. The management of superficial venous incompetence. BMJ. 2011;343:d4489.
7. Lin F, Zhang S, Sun Y, Ren S, Liu P. The Management of Varicose Veins. Int Surg. 2015;100(1):185-9.
8. Bailey H. Demonstration of physical sign in clinical surgery, Ed. Clain A 16 edition; 1973:30-32.
9. Janugade HB, Patil BP, Tata NH, Saygaonkar HV, Janugade DH, Dokania V. Clinical profile and management of lower limb varicose veins. 2017;6(2):1615-22.
10. Vaidyanathan S, Balkrishnan V. Role of Ambulatory venous pressure studies in venous disorders of the lower limb. Indian J Surg. 1986;48.
11. Nagaraj H, Hebbar AK, Rajaput AS, Kumar BVS. Prospective clinical study of surgical management of varicose veins of lower limb and its complications. Int J Res Med Sci. 2014;2:306-9.
12. Callum MJ. Epidemiology of Varicose veins. British J Surg. 1994;81:167-3.
13. Mirji P, Emmi S, Joshi C. Study of Clinical Features and Management of Varicose Veins of Lower Limb. J Clin Diagn Res. 2011;5(7):1416-20.
14. Pavan Prasad BK, Prem Kumar A. Clinical Study of varicose veins and their management. Int J Biomed Advance Res. 2015;6(08):564-8.
15. Cambell WB. Varicose vein, an increasing burden for the NHS. British Med J. 1990;300:763-4.
16. Ravinder Naik J, Noonavath RN. Clinical Study and Management of Varicose Veins. JMSCR. 2017;5(1):15473-80.
17. Donnell TFO, Burnand KG, Clemenson G, Thomas ML, Browse NL. Doppler examination vs clinical and phlebographic detection of the location of incompetent perforating veins. Arch Surg. 1977;112:31-2.

**Cite this article as:** Shafiuddin M, Bhavanishankar TP. Study of different surgical management approach in lower limb varicose veins at tertiary care hospital. Int Surg J 2017;4:2520-4.