

Original Research Article

Laparoscopic approach for small - bowel perforation - early outcome for 20 patients

Jignesh Patel¹, Piyush Patel^{2*}

¹Department of Surgery, Mamta Hospital, Surat, Gujarat, India

²Department of Surgery, GMERS Medical College, Valsad, Gujarat, India

Received: 20 August 2016

Accepted: 24 September 2016

*Correspondence:

Dr. Piyush Patel,

E-mail: drpiyushpatel621@gmail.com

Copyright: © the author(s), publisher and licensee Medip Academy. This is an open-access article distributed under the terms of the Creative Commons Attribution Non-Commercial License, which permits unrestricted non-commercial use, distribution, and reproduction in any medium, provided the original work is properly cited.

ABSTRACT

Background: Small bowel perforation is still a major health problem in the developing world with its attendant high morbidity and mortality. Till date Small bowel perforation has been treated by conventional laparotomy. Early surgery has become the accepted mode of treatment and this has improved survival in the patients. Reports are now available for the feasibility of laparoscopic repair of Small bowel perforation. Laparoscopy provides diagnostic as well as therapeutic capabilities with diagnostic accuracy reaching 100%. The objective of the study was to study benefit of laparoscopic approach for small bowel perforation.

Methods: We selected 20 patients who presented with the small bowel perforation from May 2009 to November 2011. All patients were haemodynamically stable and presented within 48 hours treated by Laparoscopic approach. Results were analyzed in terms of wound infection, hospital stay, return to work, and mortality.

Results: There was no conversion. Perforations treated with intracorporeal suturing in 11 patients and laparoscopic assisted extracorporeal suturing in 9 patients. Laparoscopy reduces postoperative pain, wound infections, hospitalization, and early recovery. There was no chest infection, post-operative intra-abdominal collection and mortality.

Conclusions: Laparoscopy is an effective tool in avoiding negative and non-therapeutic laparotomy and offered profound therapeutic potential laparoscopic approach is safe, reliable and feasible, required shorter operative time, lesser analgesia, fewer complications, shorter hospital stay and early recovery.

Keywords: Small bowel perforation, Laparoscopy, Intracorporeal suturing

INTRODUCTION

An acute abdomen responsible for about 40% of all emergency-surgical hospital admissions.¹ A majority of the cases are secondary to perforation or impending gastrointestinal perforation. Small bowel perforation is one such common surgical emergency which possess serious outcome in terms of morbidity and mortality ranging from various degree of peritonitis and shock.² Management of small bowel perforation still remains a challenge for surgeons, especially in limiting wound-related complications. Wound infection still remains the

major reason for morbidity in these patients and can lead to burst abdomen.³⁻⁵

The mainstay of treatment for small bowel perforation is surgery.¹ There are several modalities of operations are done to improve outcome. However, laparoscopy is becoming the preferred surgical approach to different pathologies due to the possibility of accurate diagnose and treating them at the same time. It has become possible to carry out even complicated bowel surgeries with laparoscopic techniques.^{6,7} Laparoscopic management of small bowel perforation has been shown

to be feasible and beneficial. However, widespread acceptance and application is still not observed.^{8,9} Although perforated peptic ulcer and colonic perforation have been repaired laparoscopically since the early 1990s.¹⁰

So, this study was planned with the objective to extend the benefit of laparoscopic approach to small bowel perforation from the viewpoint of decreasing the postoperative complications like wound infections, post-operative pain, intra-abdominal collections and hospital stay.

METHODS

This was a prospective study conducted between May 2009 and November 2011 in a tertiary care teaching hospital. The study was approved by Institutional ethical committee. All patients with small bowel perforation who underwent diagnostic and therapeutic laparoscopy in surgery department were included in the study. All the patients were explained clearly about the nature and purpose of the study in the language they understood and written informed consent was obtained before enrolling them for the study. During the study period, Laparoscopy was performed only on patients who were presented within 48 hours of onset of symptoms and haemodynamically stable. All the patients with history of previous abdominal surgery, gross abdominal distension with septicaemia, multiple perforations were excluded. Pregnant patients and paediatric patients were also not included in this study.

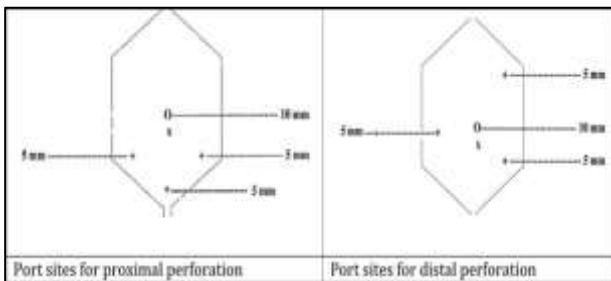


Figure 1: Various port position for laparoscopic repair of small bowel perforation.

Surgical techniques

After confirmation of diagnosis, patients were given IV fluids and analgesics. Nasogastric decompression was done. Third generation cephalosporin and metronidazole (I.V.) were given pre and post operatively. Informed consent was taken after explaining risk and complications. All patients were operated under general anaesthesia with modified trendelenburg tilt position given. Surgeon stood on left side of patient. Open Hassan’s technique was used for first umbilical port. CO2 pressure kept at 12 mm Hg. A 30° 10mm laparoscope was introduced through the umbilical port, peritoneal exploration was done. Degree of contamination,

collections in various recesses was noted. Remaining ports were placed according to the site of pathology. For proximal perforations 2 working ports were introduced in iliac fossa both side, for distal perforations one working port placed in left iliac fossa and other was in left hypochondrium keeping angle of 60° between them. Additional port can be introduced for suction or retraction (Figure 1).

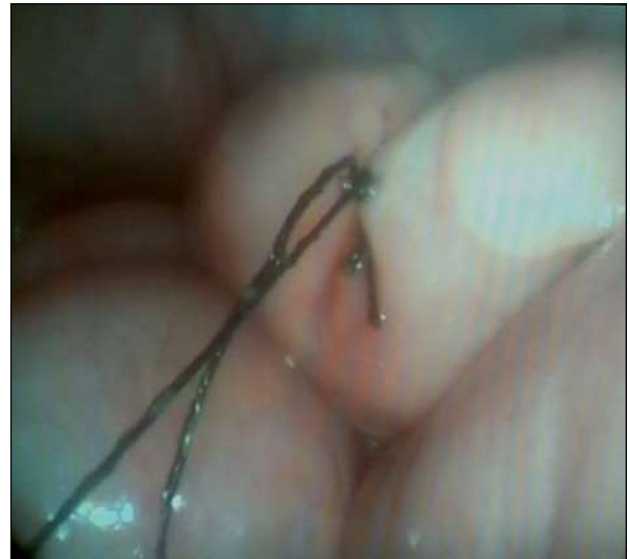

Figure 2: Intracorporeal 2 layer suturing.

The perforations were treated either by total laparoscopy or Laparoscopy assisted repair. There was single perforation in all patients. Size of perforation was measured with reference to the size of jaws of laparoscopic grasper. Biopsy was taken from the small bowel perforation margin.

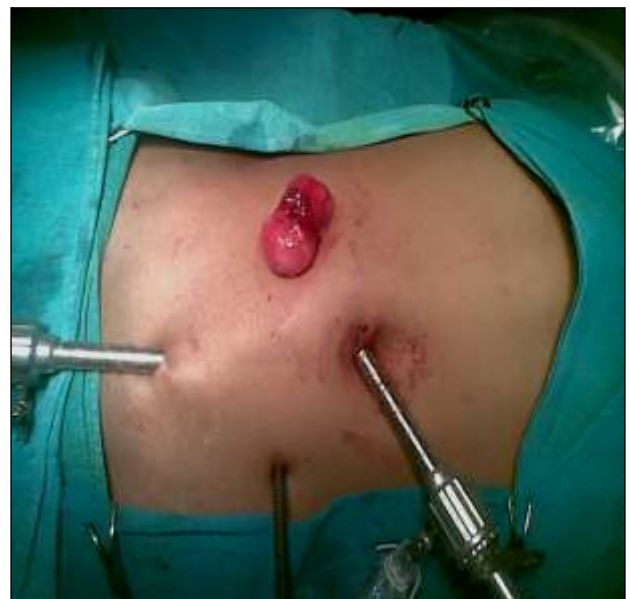

Figure 3: Laparoscopy assisted small bowel perforation repair.

In total laparoscopy, perforations were repaired by interrupted intracorporeal suturing with silk 3-0 in 2 layers.¹¹ In laparoscopy assisted technique, perforations were repaired by extracorporeal suturing with silk 3-0 in 2 layers (Figure 2). Right side working port was enlarged up to 3-4 cm (which can also be used to create stoma if needed). Thorough peritoneal lavage was given with normal saline in all peritoneal recesses and inter-bowel space. Peritoneal cavity was inspected for possible bowel injury or hemorrhage. Wide bore drainage tube kept in pelvic cavity. Port sites were closed by prolene 1-0. Sterile dressing kept over wounds (Figure 3).

If bowel condition is not healthy, laparoscopy assisted exteriorization/stoma/resection can be done. Conversion to formal laparotomy in case of technical difficulty during surgery was always an option. Though we did not have such problem in our study.

During post-operative period, all patients were mobilized within 24 hrs of surgery. Nasogastric tube was removed within 24-72hours and oral feeding was resumed once peristalsis present. I.V. antibiotics were given as mentioned earlier. Patients were given Tab. Cefixime (200mg) twice a day for 14 days post operatively. The patients were followed postoperatively for 2 weeks following discharge from the hospital.

RESULTS

In the present study, total 20 patients were enrolled during the study period. Patients were in the age group of 18-52 years with mean age of 28.76±8.65 years. The study was dominated by males’ patients (14, 70.00%) as compared to females (6, 30.00%) (Figure 4).

There was no conversion of open laparotomy. Mean operation time was 95 minutes (range 90-100 minutes) and it depends on expertise of surgeon. Average return of bowel function noted on 2nd day. Out of 20 perforations, 9 were due to typhoid pathology as supported by serum

Widal test; while in rest of perforations pathology was nonspecific (biopsy was not confirmatory). Dose of analgesia given in this group of patients found to be lesser than routine. There was no mortality in this study. 2 patients had minor port site infection which was managed by daily dressing and oral antibiotics. In 1 patient post-operative paralytic ileus occurred. Both patients were managed conservatively. Average hospital stay was 6 days (range 6-9 days) hence early recovery and return to work was significant observation in this study.

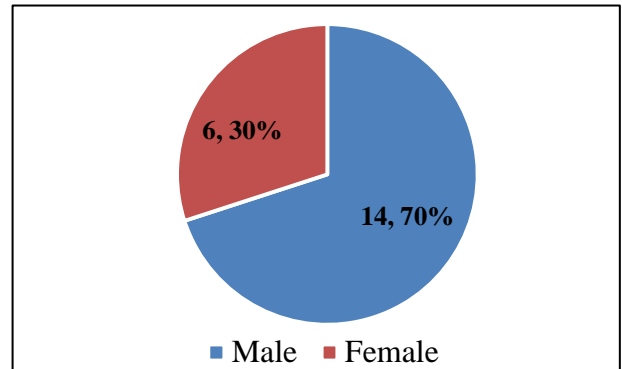


Figure 4: Distribution of the patients according to gender.

DISCUSSION

The surgical management of small bowel perforation is still presenting challenges to the surgeon despite improvement in patient survival. However different approaches to the surgery of small bowel perforation have been described and these have impacted positively on the disease outcome.

Laparoscopy is the only minimally invasive technique that provides the platform for adequate diagnosis, appropriate treatment and the best abdominal approach.

Table 1: Comparison of various studies done so far depicting the role of laparoscopy in small bowel perforation. Outcome of laparoscopic repair of small bowel perforation.

Author	No of patients	Days in hospital	Surgery duration	Morbidity	Mortality
Sinha R et al ¹²	20	10	42-75 mins	10% (Port site infection)	0
Ramachandra CS et al ¹³	6	6	45-92 mins	-	0
Present study	20	6	90 -100 min	10% (Port site infection)	0

In the present study, no mortality has been reported with only 2 (10%) patients were developed Port site infection. Similar findings were reported in study done by Sinha R et al but no morbidity reported in study done by

Ramachandra CS et al.^{12,13} But later study included only 6 patients so exact picture of post-operative complications may not be found. Average duration of hospital stay was found in our study was 10 days as compared to 6 days in studied done by Sinha R et al and Ramachandra CS et

al.^{12,13} The duration of surgery ranges from 45-92 minutes in Sinha's series and a single layer intracorporeal closure of the perforation with 3-0 polydioxanone were done.¹² Ramachandra CS et al used 2-0 silk with Duration of perforation prior to surgery ranges from 3-5 days.¹³ In the present study, surgery duration was ranged from 90-100 minutes.

Laparoscopy is advantageous because of the better quality of peritoneal washing and easy cleaning in the abdominal recesses as well as minimal trauma of the abdominal wall. Open surgery has a high rate of wound dehiscence and intra-abdominal abscess formation. This is not the case with the patients who underwent laparoscopy, port site infection being the commonly reported morbidity. Significantly there was no mortality in our study. This could be attributed to patient selection. However, the surgeon can always convert in difficult cases. Even in technically difficult cases, laparoscopic assisted procedure done and are likely to have a better outcome compared to the patient who had a planned open operation.

Double layer closure was used during laparoscopic surgery which has also shown to be effective in enteric perforation. Shorter duration of hospital stay is a well-known benefit of laparoscopy, and this can significantly reduce the morbidity. Duration of surgery could also be shortened in expert hands.

A careful analysis of results of open surgery reveals that wound-related morbidity, which includes wound infection and various grades of wound dehiscence, may be as high 4 out of 8 Wound infection leads to persistent septicaemia and is often fatal when it becomes a complete dehiscence.^{14,15} This could be offset in a major way by laparoscopic intervention.

However, laparoscopic intervention too has its limitations. The main limitation is adhesions, which in turn are related to the time interval of presentation. Thus, patients presenting within 48 hours of the catastrophe are more easily manageable laparoscopically. Patients presenting beyond this time interval usually develop more-dense small bowel adhesions, and their adhesinolysis becomes problematic laparoscopically as oedematous bowel is always susceptible to traction injury during manipulation. SB perforations as a result of other causes like solitary ischemic perforations, sharp injury, and tubercular perforations can all be treated similarly in select cases.^{16,17}

Patients were entirely treatable by laparoscopy, avoiding therapeutic celiotomy, 100% diagnostic accuracy in acute abdomen; nevertheless, conversion was always possible if the assessment was inadequate. It was always possible to perform a laparoscopy, whether in an emergency situation or after an initial delay.

CONCLUSION

Thus the laparoscopy & laparoscopic assisted procedures in patients with a small bowel perforation who are haemodynamically stable are feasible, safe and many benefits including reduction in peri-operative morbidity and mortality. Laparoscopy provides diagnostic as well as therapeutic capabilities with diagnostic accuracy reaching 100% laparoscopy reduces postoperative pain, aids in the recovery of GI function, reduces wound infections, reduces hospitalization, and enhances the cosmesis. Laparoscopy is an effective tool in avoiding negative and non-therapeutic laparotomy and offered profound therapeutic potential.

Funding: No funding sources

Conflict of interest: None declared

Ethical approval: Not required

REFERENCES

1. Langell JT1, Mulvihill SJ. Gastrointestinal perforation and the acute abdomen. *Med Clin North Am.* 2008;92(3):599-625, viii-ix.
2. Talwar S, Sharma R.K, Mittal D. K., Prasad P. Typhoid enteric perforation. *Aust N Z J Surg.* 1997;67:351-3.
3. Oheneh-Yeboah M. Postoperative complications after surgery for typhoid ileal perforation in adults in Kumasi. *West Afr J Med.* 2007;26:32-6.
4. Agbakwuru EA, Adesukanmi AR, Fadiora SO, et al. A review of typhoid perforation in a rural African hospital. *West Afr J Med.* 2003;22:22-5.
5. Ugwu BT, Yiltok SJ, Kidmas AT, Opaluwa AS. Typhoid intestinal perforation in north central Nigeria. *West Afr J Med.* 2005;24:1-6.
6. Farooq A, Ammori BJ. Laparoscopic diagnosis and management of primary bacterial peritonitis. *Surg Laparosc Endosc Percutan Tech.* 2005;15(1):36-7.
7. Milsom JW, de Oliveira O Jr, Trencheva KI, Pandey S, Lee SW, Sonoda T. Long-term outcomes of patients undergoing curative laparoscopic surgery for mid and low rectal cancer. *Dis Colon Rectum.* 2009;52:1215-22.
8. Kathkhouda N, Movor E, Mason RJ, Campos GM, Soroshyari A, Berne TV. Laparoscopic repair of perforated duodenal ulcers. Outcome and efficacy in 30 consecutive patients. *Arch Surg.* 1999;134:845-50.
9. Lau WY, Leung KL, Kwong KH, et al. A randomized study comparing lap vs. open repair of perforated peptic ulcer using suture or sutureless technique. *Ann Surg.* 1996;224:131-8.
10. Mouret P, Francois V, Vignal J, Barth X, Lombard-Platet R. Laparoscopic treatment of perforated peptic ulcer. *Br J Surg.* 1990;77:1006.
11. Jagad RB. Laparoscopic closure of small bowel perforation: Technique of small bowel anchoring to the abdominal wall. *J Min Access Surg.* 2009;5:47-8.

12. Sinha R, Sharma N. Laparoscopic repair of small bowel perforation. *JLS.* 2005;9:399-402.
13. Ramachandran CS, Agarwal S, Goel NB. Laparoscopic Surgical management of perforative peritonitis in enteric fever: A preliminary report. *Surg Laparosc Endosc Percut Tech.* 2004;14:122-4.
14. Oheneh-Yeboah M. Postoperative complications after surgery for typhoid ileal perforation in adults in Kumasi. *West Afr J Med.* 2007;26:32-6.
15. Agbakwuru EA, Adesukanmi AR, Fadiora SO, et al. A review of typhoid perforation in a rural African hospital. *West Afr J Med.* 2003;22:22-5.
16. Mallat AF, Mancini ML, Daley BJ, Enderson BL. The role of laparoscopy in trauma: a ten-year review of diagnosis and therapeutics. *Am Surg.* 2008;74(12):1166-70.
17. Agresta F, Ciardo LF, Mazzarolo G, Michelet I, Orsi G, Trentin G, et al. Peritonitis: laparoscopic approach. *World J Emerg Surg.* 2006;1:9.

Cite this article as: Patel J, Patel P. Laparoscopic approach for small - bowel perforation - early outcome for 20 patients. *Int Surg J* 2016;3:2191-5.