

Original Research Article

Role of axillary reverse mapping in decreasing complications after axillary dissection in breast cancer

Ahmed Gaber*, Ahmed Fawzy, Ahmed Sabry, Alaa El Sisi

Department of General Surgery, Faculty of Medicine, Al Menofia University, Egypt

Received: 02 July 2017

Accepted: 08 July 2017

*Correspondence:

Dr. Ahmed Gaber,

E-mail: ahmed.eltatawy@med.menofia.edu.eg

Copyright: © the author(s), publisher and licensee Medip Academy. This is an open-access article distributed under the terms of the Creative Commons Attribution Non-Commercial License, which permits unrestricted non-commercial use, distribution, and reproduction in any medium, provided the original work is properly cited.

ABSTRACT

Background: Breast cancer is one of the most leading causes of cancer deaths in female. Surgical treatment is considered the corner stone in its management. Axillary lymph node dissection (ALND) is an integral step in most of surgeries done, however it has many morbidities like prolonged seroma and lymphedema. Axillary reverse mapping (ARM) procedure was first described in 2007 in a trial to map the axillary lymphatics of the arm and avoid its injury therefore lymph complications.

Methods: A prospective, randomized, controlled study over 72 female patients who underwent modified radical mastectomy (MRM). Patients were divided and randomized into study and control groups, thirty-six patients for each. In study group the ARM procedure was done by injecting 2.5 ml of methylen blue dye intra-dermally and subcutaneously in the upper inner ipsilateral arm along the medial intramuscular groove before ALND. Operative and post-operative results were recorded. Follow up was 6 to 24 months.

Results: ARM procedure and successful visualization of arm lymphatics was achieved in 31 patients (86.1%). Statistically there was no significant difference between the two groups regarding patient and tumour characteristics, operative time and number of excised L.Ns. There was significant difference favouring the ARM group in decreasing the incidence of seroma ($p=0.040$), lymphedema ($p=0.031$) and time passed till remove drains ($p<0.001$).

Conclusions: ARM procedure facilitated arm lymphatics visualization. It is easy non-time-consuming procedure. It resulted in significant reduction in incidence of seroma and lymphedema, with considerable reduction in the overall complications rate.

Keywords: Axillary lymph node dissection, Axillary reverse mapping, Arm lymphedema, Seroma

INTRODUCTION

Breast cancer is the most common malignancy in women worldwide and its incidence increases every year.¹ From the total female cancer cases in Egypt, breast cancer represented 35.1%.²

The primary site of lymphatic drainage of the breast is the axillary lymph nodes that involved in regional metastatic disease in breast cancer. Axillary lymph node dissection is the standard treatment of axillary lymph node

metastasis. It is important for local control, staging and increase the possibility of survival benefit.³

Most of the serious complications after breast surgery are attributed to axillary lymph node dissection such as; lymphedema, seroma and major neurovascular injuries.⁴

Seroma is the most common problem occurring after axillary lymph node dissection; excessive fluid accumulation usually stretches the skin and causes it to sag, resulting in patient discomfort, and delay of adjuvant

therapy.⁵ The reported incidence of seroma formation after breast surgery varies widely from 2.5% to 51%.⁶ Up to 3% - 85%.⁷

The etiology of seroma formation is yet not quite clear. Studies on the composition of the fluid collected from post mastectomy drainage suggest an inflammatory origin, while others have hypothesized that seroma is most likely to originate from lymph leak.⁸

Lymphedema of the upper arm is a non-lethal complication of axillary lymph node dissection. The incidence of lymphedema is variable (from 10-50%) according to difference of the treatment modalities (Sentinel L.N or axillary lymph node dissection) with or without radiotherapy.⁸ It results from cutting or ligation of upper limb lymphatics during axillary dissection.^{7,9}

The virtually unknown variations in arm lymphatic drainage put the arm lymphatics at risk for disruption during ALND. Therefore, mapping the drainage of the arm with blue dye and preserving the identified lymphatics would help in identification and decrease the likelihood of disruption of the lymphatics draining the arm during ALND.¹⁰

The objective of this study was to put a spot on the effect of axillary reverse mapping (ARM) technique on the incidence of seroma and lymphedema after modified radical mastectomy (MRM).

METHODS

This study was conducted at General surgery department of Al Menofia University Hospital on seventy-two patients admitted from outpatient clinic with breast cancer to whom modified radical mastectomy was done in the period from June 2012 to December 2016. The patients were randomly divided into two groups (A, B). Each group contained thirty-six patients. Group A (study group): modified radical mastectomy was done with axillary reverse mapping. Group B (control group): modified radical mastectomy was done without axillary reverse mapping. All patients were submitted to complete history taking, physical examination and preoperative work up to diagnose the cancer and detect its metastasis. We excluded patients arranged for conservative breast surgery or SLN, patients arranged for immediate breast reconstruction and patients with advanced breast cancer.

After completion of simple mastectomy and 5 to 10 minutes before ALND, 2.5 ml of methylen blue dye was injected intra-dermally and subcutaneously in the upper inner arm along the medial intramuscular groove of the ipsilateral side. The upper inner area was chosen simply because it has the most rapid drainage and it hides the tattoo that could last from 1 week to 6 months. After injection, the site was massaged and the arm was elevated for 5 minutes to enhance arm lymphatic drainage.

Axillary dissection in the study group was done from the lateral side first to detect and preserve the mapped lymphatic channels. Entrance of the axilla in the control group was done as usual from medial to lateral. After dissection through the axillary fascia, we could identify and preserve the apparent blue lymphatics draining the arm and ligation of the injured ones (Figure 1).

Coagulate mood of diathermy was used to control bleeding from small vessels. Two limbs of 16 F suction drains were placed in all patients. One limb was placed in the axilla and the other one under the upper flap.

Follow up

All patients were followed up for 2-3 days in the hospital, then turned to regular visits at outpatient clinic.

Study recorded total drain outputs daily for all patients prior to drain removal. The drains were removed when the daily drainage was less than 40 ml. After removal of the drains, seroma and the amount of aspirated fluid were recorded.

Tape measurement of the arm circumference 10cm above and below olecranon process was used to detect lymphoedema. This was done preoperatively and 2 weeks, 1, 3 and 6 months postoperatively up to 24 months.

RESULTS

Results were statistically analyzed by SPSS version 20 (SPSS Inc., Chicago, IL, USA). Chi-Squared (χ^2) and Fisher's exact test were used for qualitative variable. Student's t-test was used to indicate the presence of any significant difference between two means for a normally distributed quantitative variable. P value was set to be significant at ≤ 0.05 and highly significant results at < 0.001 .

Seventy-two patients were included in this study. They were randomly divided into two groups (study and control). Each group contained thirty-six patients. The range of the age for study group was 38-66 years with mean \pm SD (51.50 \pm 7.40) Compared to 37-67 years with mean \pm SD (52.25 \pm 7.94) for control group with non-significant statistical difference between both groups ($P=0.680$). In study group 10 patients (27.8%) were premenopausal and 26 patients (72.2%) were postmenopausal compared to 12 patients (33.3%) premenopausal and 24 patients (66.7%) postmenopausal in the control group with no significant statistical difference between both groups ($P = 0.609$). Regarding tumour side, site and size, there were no significant statistical differences between both groups ($P = 0.814$), ($P = 0.791$) and ($P = 0.628$) respectively (Table 1).

The mean \pm SD operative time was 101.0 \pm 10.50 minutes with range (94-135) and 97.0 \pm 8.19 minutes with range (85-120) for study and control groups respectively. There is no significant difference between both groups (P= 0.076).

Successful mapping to the axillary lymphatics of the upper limb occurred in thirty-one patients (86.1%), while failed in five patients (13.9%) who discarded from the study.

Table 1: Patients and tumour characteristics of the studied groups.

	Groups				Test of sig	P value
	Study (No.=36)		Controls (No.=36)			
Age in years $\bar{X} \pm SD$	51.50±7.40 Range = (38-66)		52.25±7.94 Range = (37-67)		t = 0.41	0.680
Menopausal status: no, %	No.	%	No.	%	χ^2 0.26	0.609
Pre	10	27.8	12	33.3		
Post	26	72.2	24	66.7		
Tumour side: no, %						
Right	18	50.0	19	52.8	χ^2 0.05	0.814
Left	18	50.0	17	47.2		
Tumour site: no, %						
UOQ	21	58.3	20	55.6	χ^2 1.70	0.791
LOQ	9	25.0	11	30.6		
UIQ	1	2.8	0	0.0		
LIQ	1	2.8	2	5.6		
Central	4	11.1	3	8.3		
Tumour size: $\bar{X} \pm SD$	2.84±0.56		2.77±0.59		t = 0.48	0.628

Table 2: Operative characteristics of the studied groups.

	Groups		t Test	P value
	Study (No.=36)	Controls (No.=36)		
	$\bar{X} \pm SD$	$\bar{X} \pm SD$		
Operative time (minutes):	101.0 \pm 10.50 R = (94-135)	97.0 \pm 8.19 R = (85-120)	1.81	0.076
Number of L.N.	(No. = 31)	(No. = 36)	0.56	0.573
	15.93 \pm 2.60 R = (10-21)	15.52 \pm 3.19 R = (9-23)		
Drain removal (days)	(No. = 31)	(No. = 36)	11.61	<0.001**
	11.22 \pm 0.80 R = (10-12)	14.41 \pm 1.40 R = (12-17)		

** highly significant, R = range

Table 3: Post-operative complications.

Complications	Groups				Test of sig.	P value
	Study (No.=31)		Controls (No.=36)			
	No.	%	No.	%		
Seroma	2	6.5	9	25.0	χ^2 4.18	0.040*
Lymphedema	1	3.2	8	22.2	Fisher's exact 5.17	0.031*
Wound complications					Fisher's exact	
Infection	2	6.5	4	11.1	0.44	0.678
Dehiscence	1	3.2	2	5.6	0.21	1.0

*significant.

Number of harvested L.N show no significant difference between both groups (P = 0.573). The mean \pm SD was 15.93 \pm 2.6 L. Ns with range (10-21) for study group

and 15.52 \pm 3.19 L.Ns with range (9-23) in control group (Table 2).

Strikingly there was highly significant reduction is observed in study group in comparison to the control one as regard to the duration, per days, before drains were removed. The mean \pm SD was 11.22 \pm 0.80 days with range (10-12) days in study group and was 14.41 \pm 1.40 with range (12-17) days in control group (P <0.001). Considerable reduction in the mean amount of drained fluid daily was also observed favoring the study group (Figure 2, 3).

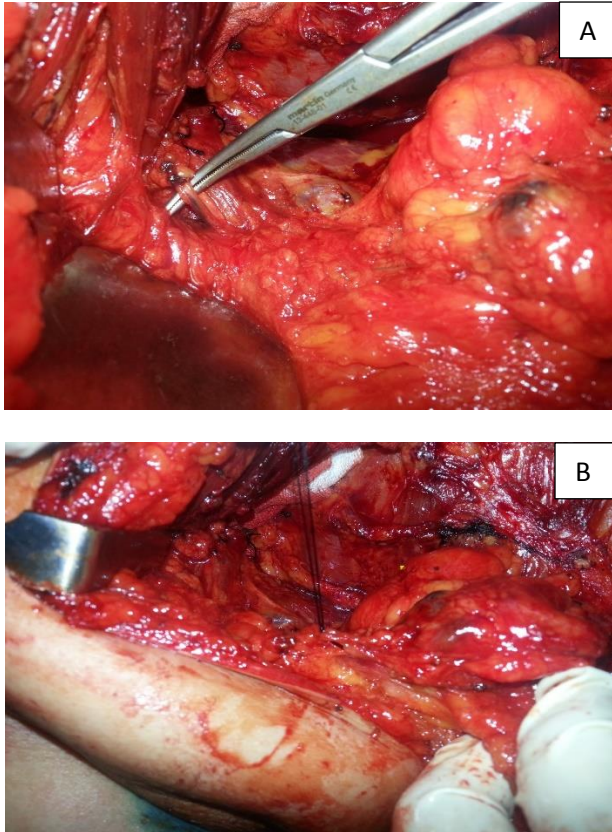


Figure 1: (A) Identification and preservation of lymphatic vessels; (B) Ligation of injured lymphatic vessels.

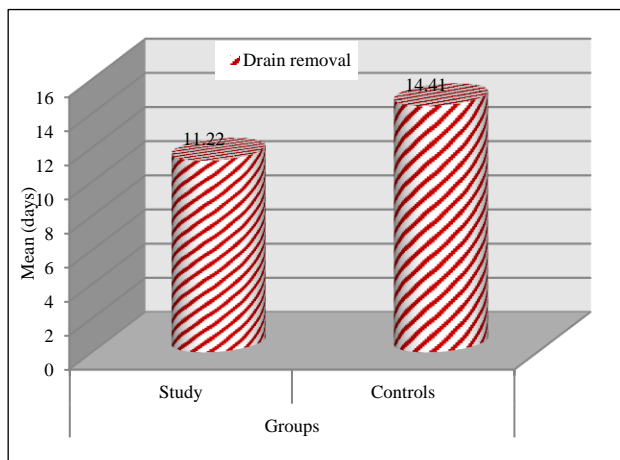


Figure 2: Time to drain removal in days in the studied groups (P <0.001).

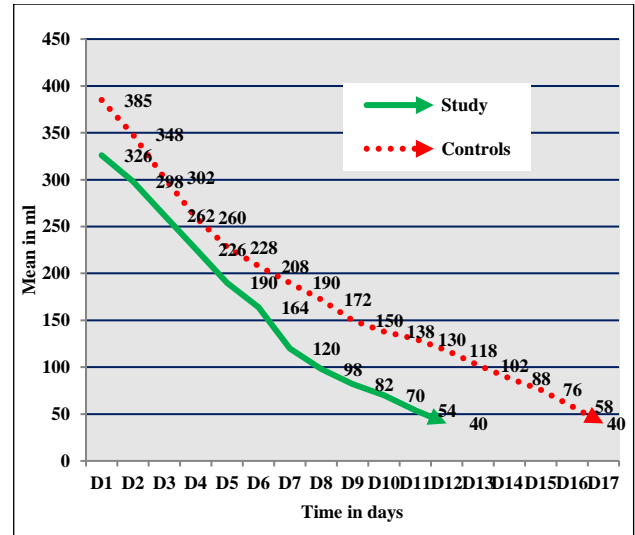


Figure 3: Mean amount of drained fluid in days in the studied groups.

There was significant reduction in incidence of seroma favoring the study group by incidence 6.5% (2 patients out of 31) compared to 25% (9 patients out of 36) in control group (P = 0.040).

There was also significant reduction in incidence of lymphedema favoring the study group by incidence 3.2% (1 patients out of 31) compared to 22.2% (8 patients out of 36) in control group (P = 0.031).

There was reduction of incidence of wound complications (infection and dehiscence) in study group but without significant statistical difference between the both groups. The incidence of wound infection was 6.5% (2 patients out of 31) in study group compared to 11.1% (4 patients out of 36) in control group (P = 0.678). While the incidence of wound dehiscence was 3.2% (1 patients out of 31) in study group compared to 6.5% (2 patients out of 36) in control group (P = 1.0) (Table 3).

Lastly mild complications were related to methylen blue as tattoo formation at the site of injection which disappeared gradually in three to six weeks. No allergy or anaphylaxis occurred to the patients from the injection of the dye.

DISCUSSION

Breast cancer has remained the second leading cause of cancer death among women worldwide over the past three decades with estimated 28% of all females' newly diagnosed cancer and 15% of estimated annual causes for deaths in USA in 2010 and contributing significantly to cancer surgical load.¹¹ In breast cancer, axillary lymph node dissection remains an essential part of surgical treatment. Seroma and chronic lymphoedema are the most usual complications.^{12,13}

With unclear origin, it was postulated that seromas form as an exudate from an acute inflammatory reaction due to the trauma of surgery that cause increased fibrinolytic activity in the lymph and serum leading to increase serous fluid collection. Supporting its lymph origin, it was found that there are low fibrinogen levels in seromas in comparison to with those in plasma during the postoperative period.¹⁴

Lymphoedema which is defined as an increase in arm volume greater than 20% from baseline and because of its chronicity it is considered one of the most dreaded morbidities.¹⁵ Lymphedema is still a morbidity that is faced by breast cancer patients in spite of all hard efforts done to reduce the invasiveness of the surgery.^{16,17} In the literature its incidence ranges from (11.8 - 53.5)% for axillary lymph node dissection and (zero - 15.8)% for sentinel lymph node procedure.^{18,19} In 2011 Devoogdt N et al, concluded that the short term manual lymph drainage in addition to guidelines and exercise therapy didn't have considerable effect in decreasing the arm lymphedema rate after axillary lymph node dissection for breast cancer.²⁰ Due to this result and with presence of much variations in arm lymphatic drainage that put these lymphatics at risk of disruption during axillary lymph node surgery, hence the need for mapping of axillary lymphatics become a must and floated to the surface introducing itself as an important and irreplaceable step during axillary surgeries. Earlier in 2007 Thompson M et al, and Nos C et al, started to do axillary reverse mapping using blue dye telling that it has a great effect in reducing or even preventing occurrence of lymphedema.^{21,22} Since then many studies on axillary reverse mapping were done. These studies were based on the assumption that there are different and separate pathways for lymphatics of the upper limb and the breast with reported some interconnections between them. The role of ARM here is that it helps to distinguish these pathways from each other.²¹⁻²⁴

In harmony with our results Tummel E et al, mentioned that the mean age in his study was 57 ± 13 years compared to ours that was 51.50 ± 7.40 years in study group and 52.25 ± 7.94 in control group.²⁵ Thompson M et al, mentioned that the median age of his patients was 49.7 ± 13 years with range (26-69) years compared to our ranges (38-66) years and (37-67) years for study and control groups respectively.²¹ Also, similar to our results Casabona F et al, documented that the mean age in his study was 57 years with range 25-81 years, and most of them, 82% (59/72), were post-menopausal compared to 69.44% (50/72) post-menopausal patients in our study (50/72)

Beek MA et al, documented in his review for many ARM studies that the visualization rate for axillary nodes and axillary lymphatics in ALND range between (39-90%) and (47-86%) respectively.^{24,26} Gebruers N et al, in systemic review for lymphatic visualization mentioned that in ALND the average of detection ratio was 80.8%

with range 46.6- 94.9% documenting that the coloring technique (Blue dye, isotope, fluorescence) seems that it doesn't have any influence on the detection rate of ARM nodes.²⁷ This agree with our results where we had successful visualization of lymphatics in 86.1% of cases in the study group after injection of 2.5 ml of methylene blue. Tummel E et al, documented successful visualization of lymphatics and L.Ns. in 71.8% of ALND cases.²⁵ Nos C et al, in the first trials on 21 patients mentioned that the procedure and visualization reached in only 15 patients (71%) with range of 50% in the first ten patients (5/10) and 10 out of 11 patients (91.1%) in the remnant 11 patients.²² This was mostly with increasing the experience and perfection of doing the procedure. Thompson M et al, mentioned that, after injecting 2.5-5 mL of blue dye identification of blue lymphatics or nodes within the axilla proper was successful in 61% of cases in their first 18 ALNDs.²¹

Study results show that the mean \pm SD number for dissected L.Ns. was (15.93 ± 2.6) L.Ns with range (10-21) for study group and (15.52 ± 3.19 L.Ns) with range (9-23) in control group. Similar results documented by Thompson M et al, who documented that the mean \pm SD number of L.Ns. during ALND was (12.5 ± 5) with range (3-21) nodes.²¹ Casabona F et al, mentioned that in the nine patients who underwent ALND the mean number of excised L.Ns. was 16 with range (9-24) nodes.²⁶ Tummel E et al, mentioned that the median number for excised L.Ns. were 13.3 nodes in patients underwent ALND whether it was accompanied by SLNB or not.²⁵ Nos C et al, mentioned that the mean number of axillary nodes removed in the axillary dissection was 10.8 with range (3-37).²² With non-significant difference between our study and control groups we can document that the ARM procedure didn't affect the number of excised L.Ns. It makes the ALND much easier with a clear paved way demonstrating the arm lymphatics and preventing its injury.

Study results show that the operative time for control group (without ARM) is lesser than that for study group (with ARM) and this is logic due to the added time of ARM procedure. But, this didn't reach significant level where the mean \pm SD operative time was 101.0 ± 10.50 minutes with range (94-135) and 97.0 ± 8.19 minutes with range (85-120) for study and control groups respectively ($P = 0.076$). This means that the ARM procedure didn't affect the operative time significantly.

In this study, strikingly there was highly significant reduction observed in study group in comparison to the control one as regard to the duration per days, before drains were removed. The mean \pm SD for drain removal was 11.22 ± 0.80 days with range (10-12) days in study group and 14.41 ± 1.40 with range (12-17) days in control group ($P < 0.001$). Also, there was significant reduction in incidence of seroma favoring the study group by incidence 6.5% (2 patients out of 31) compared to 25% (9 patients out of 36) in control group ($P = 0.040$), these

rates are compatible with previously mentioned ranges by Anand R and Boostrom SY.^{6,7} This was accompanied by considerable reduction in the mean amount for drained fluid daily favoring also the study group. We suggest that this happened as normal reflection of cautious preservation of arm lymphatics that can be easily injured or divided during ALND and even if it is injured it could be easily visualized and ligated. Contrary to what occurs in non-ARM patients, these lymphatics could be divided and unnoticed and these open lymphatics will continue oozing the lymph causing delayed drain removal and increasing the seroma incidence. Although it didn't reach a significant level there was considerable reduction in the wound complications in study (ARM) group in the form of wound infection and wound dehiscence as a normal sequel of decreased seroma rate.

The results show that there was a significant reduction in incidence of lymphedema favoring the study (ARM) group and documenting that the ARM procedure was the cause for this reduction. It was 3.2% (1 patients out of 31) in study group compared to 22.2% (8 patients out of 36) in control group ($P = 0.031$). This matches with the range mentioned by DiSipio T et al, in his systemic review of lymphedema after breast surgery telling that the incidence of lymphedema in their estimation for 30 studies was 21.4% with range (14.9-29.8%).¹⁸ Telling also that the incidence increases by time till 2 years post operatively. This rate increases with increasing the assessing method to 28.2%, with range (11.8-53.5) in non-ARM axillary lymph node dissection. Tummel E et al, documented that the total lymphedema rate was 21.4% (33/154) of ALND patients which dropped to 6.9% (5/72) ALND with implication of ARM procedure.²⁵ Similar result was documented by Yue T et al, where the incidence of lymphedema in control group was 33.07% compared to 5.93% in ARM group.²⁸ Many authors agree with our results that ARM facilitates the preservation of lymphatics draining the arm and decreases the post-operative lymphedema rate.²⁰⁻²⁸

Ikedo K et al, concluded that Information regarding the ARM factors could predict the incidence of arm lymphedema in patients with breast cancer following post axillary surgery and documented that ARM node positivity is a positive risk factors for lymphedema.²⁹

Contrary to all previous results Tausch C et al, concluded that there is no evidence that ARM decreases the lymphedema rate after ALND in patients with breast cancer.³⁰ Beek M A et al, told that major problem with the ARM procedure is the assumption that the arm lymphatics plays a minor role in the pathway for breast L.Ns. through the small interconnections present between arm and breast lymphatics.²⁴ This may permit some metastasis from breast cancer to pass and interfere with perfect radicality. However, till the moment with the use of ARM and preservation of arm L.Ns, no reported increase in the incidence of axillary recurrence in the literature.

CONCLUSION

Axillary reverse mapping facilitates much visualization and preservation of arm lymphatics during ALND. It is easy procedure and doesn't have significant effect on operative time. ARM decreased significantly not only the incidence of post-operative lymphedema and seroma but also the time elapsed to remove the drains. The mean daily amount of serous fluid and wound complications were decreased also. This is mostly due to cautious preservation of lymphatics and ligation of any injured one. Our results recommend ARM procedure during ALND. Further larger prospective studies are also recommended.

Funding: No funding sources

Conflict of interest: None declared

Ethical approval: The study was approved by the institutional ethics committee

REFERENCES

1. Ferlay J, Autier P, Boniol M, Heanue M, Colombet M, Boyle P. Estimates of the cancer incidence and mortality in Europe in 2006. *Ann Oncol.* 2007;18(3):581-92.
2. Hokkam E, Farrag S, El Kammash S. Tetracycline sclerotherapy in treating postmastectomy seroma: a simple solution for a frequently occurring problem. *Egyptian J Surgery.* 2009;28:99-104.
3. Aitken DR, Minton JP. Complications associated with mastectomy. *Surg Clin North Am.* 1983;63:1331-52.
4. Beaulac SM, McNair LA, Scott TE, LaMorte, WW, Kavanah MT. Lymphedema and quality of life in survivors of early stage breast cancer. *Arch Surg.* 2002;137:1253-7.
5. Chilson TR, Chan FD, Lonser RR, Wu TM, Aitken DR. Seroma prevention after modified radical mastectomy. *Am Surg.* 1992;58:750-4.
6. Anand R, Skinner R, Dennison G, Pain JA. A prospective randomised trial of two treatments for wound seroma after breast surgery *EJSO.* 2002;28:620-2.
7. Boostrom SY, Throckmorton AD, Boughey JC. Incidence of clinically significant seroma after breast and axillary surgery. *J Am Coll Surg.* 2009;208:148-50.
8. Bonnema J, van Geel AN, Ligtenstein DA, Schmitz PI, Wiggers T. A prospective randomized trial of high versus low vacuum drainage after axillary dissection for breast cancer. *Am J Surg.* 1997;173:76-9.
9. Britton TB, Solanki CK, Pinder SE. Lymphatic drainage pathways of the breast and the upper limb. *Nucl Med Comm.* 2009;30(6):427-30.
10. Thompson M, Korourian S, Henry-Tillman R, Adkins L, Mumford S, Westbrook K, et al. Axillary reverse mapping (ARM): a new concept to identify

- and enhance lymphatic preservation. *Ann Surg Oncol* 2007;14(6):1890-5.
11. Jemal A, Siegel R, Xu J, Ward E. Cancer statistics. *Ca Cancer J Clin.* 2010;60:277-300.
 12. Lee EW, Shin JH, Ko HK, Park J, Kim SH, Sung KB. Lymphangiography to treat postoperative lymphatic leakage: a technical review. *Korean J Radiol.* 2014;15(6):724-32.
 13. Flores EV, de Castro G, Casal E, Sobrino C. Chylous fistula following axillary lymphadenectomy. *Cirugia Espanola.* 2014;92(1):55-6.
 14. Srivastava V, Basu S, Shukla VK. Seroma formation after breast cancer surgery: what we have learned in the last two decades. *J Breast Cancer.* 2012;15(4):373-80.
 15. Ahmed M, Rubio IT, Kovacs T, Klimberg VS, Douek M. Systematic review of axillary reverse mapping in breast cancer. *BJS.* 2016;103:170-8.
 16. McLaughlin SA, Wright MJ, Morris KT, Giron GL, Sampson MR, Brockway JP, et al. Prevalence of lymphedema in women with breast cancer 5 years after sentinel lymph node biopsy or axillary dissection: objective measurements. *J Clin Oncol.* 2008;26(32):5213-9.
 17. Lumachi F, Basso SM, Bonamini M, Marino F, Marzano B, Milan E, et al. Incidence of arm lymphedema following sentinel node biopsy, axillary sampling and axillary dissection in patients with breast cancer. In *Vivo (Athens Greece).* 2009;23(6):1017-20.
 18. DiSipio T, Rye S, Newman B, Hayes S. Incidence of unilateral arm lymphedema after breast cancer: a systematic review and meta-analysis. *Lancet Oncol.* 2013;14(6):500-15.
 19. Gebruers N, Verbelen H, De Vrieze T, Coeck D, Tjalma W. Incidence and time path of lymphedema in sentinel node negative breast cancer patients: a systematic review. *Arch Phys Med Rehabil.* 2015;96(6):1131-9.
 20. Devoogdt N, Christiaens MR, Geraerts I, Truijen S, Smeets A, Leunen K, et al. Effect of manual lymph drainage in addition to guidelines and exercise therapy on arm lymphedema related to breast cancer: randomised controlled trial. *BMJ.* 2011;343:d5326.
 21. Thompson M, Korourian S, Henry-Tillman R, Adkins L, Mumford S, Westbrook K, et al. Axillary reverse mapping (ARM): a new concept to identify and enhance lymphatic preservation. *Ann Surg Oncol.* 2007;14(6):1890-5.
 22. Nos C, Lesieur B, Clough KB, Clough KB, Lecuru F. Blue dye injection in the arm in order to conserve the lymphatic drainage of the arm in breast cancer patients requiring an axillary dissection. *Ann Surg Oncol.* 2007;14(9):2490-6.
 23. Pavlista D, Eliska O. Analysis of direct oil contrast lymphography of upper limb lymphatics traversing the axilla - a lesson from the past - contribution to the concept of axillary reverse mapping. *Eur J Surg Oncol.* 2012;38(5):390-4.
 24. Beek MA, Gobardhan PD, Schoenmaeckers EJP, Klompenhouwer EG, Rutten HJT, Voogd AC, et al. Axillary reverse mapping in axillary surgery for breast cancer: an update of the current status. *Breast Cancer Res Treat;* 2016.
 25. Tummel E, Ochoa D, Korourian S, Betzold R, Adkins L, McCarthy M, et al. Does axillary reverse mapping prevent lymphedema after lymphadenectomy? *Ann Surg.* 2017;265(5):987-92.
 26. Casabona F, Bogliolo S, Menada MV, Sala P, Villa G, Ferrero S. Feasibility of axillary reverse mapping during sentinel lymph node biopsy in breast cancer patients. *Ann Surg Oncol.* 2009;16:2459-63.
 27. Gebruers N, Tjalma WAA. Clinical feasibility of axillary reverse mapping and its influence on breast cancer related lymphedema: a systematic review. *Eu J Obstet Gynecol Reproduct Biol.* 2016;200:117-22.
 28. Yue T, Zhuang D, Zhou P, Zheng L, Fan Z, Zhu J, et al. A prospective study to assess the feasibility of axillary reverse mapping and evaluate its effect on preventing lymphedema in breast cancer patients. *Clin Breast Cancer.* 2015;15(4):301-6.
 29. Ikeda K, Ogawa Y, Kajino C, Deguchi S, Kurihara S, Tashima T, et al. The influence of axillary reverse mapping related factors on lymphedema in breast cancer patients. *Eur J Surg Oncol.* 2014;(7):818-23.
 30. Tausch C, Baege A, Dietrich D, Vergin I, Heuer H, Heusler RH, et al. Can axillary reverse mapping avoid lymphedema in node positive breast cancer patients? *Eur J Surg Oncol.* 2013;39(8):880-6.

Cite this article as: Gaber A, Fawzy A, Sabry A, Sisi AE. Role of axillary reverse mapping in decreasing complications after axillary dissection in breast cancer. *Int Surg J* 2017;4:2397-403.