

## Original Research Article

# The sutureless circumcision: a novel surgical innovation

M. S. Ray, B. S. Deepak\*

Department of Surgery, Military Hospital, Jalandhar Cantt, Jalandhar, Punjab, India

**Received:** 05 August 2016

**Revised:** 10 September 2016

**Accepted:** 13 September 2016

**\*Correspondence:**

Dr. B. S. Deepak,

E-mail: [deepaksatyapal@gmail.com](mailto:deepaksatyapal@gmail.com)

**Copyright:** © the author(s), publisher and licensee Medip Academy. This is an open-access article distributed under the terms of the Creative Commons Attribution Non-Commercial License, which permits unrestricted non-commercial use, distribution, and reproduction in any medium, provided the original work is properly cited.

### ABSTRACT

**Background:** Circumcision is a commonly performed surgical procedure done all over the world for various reasons. There are a number of ways to achieve the same which have been used from ancient times till recent times. Sutureless circumcision is a novel surgical technique which we have used with excellent results, good cosmesis and wound healing. The objective of this study was to bring forward a novel and new innovative method of circumcision.

**Methods:** The sutureless circumcision was performed over 132 patients from 1992 till date with excellent results.

**Results:** The incidences of complications were minimal with excellent wound healing though some cases had self-limiting penile oedema which subsided subsequently.

**Conclusions:** This novel technique has given excellent results and it can be used in countries where there is paucity of funds as it is very economical advocating a newer technique of circumcision without the use of costly tissue adhesive etc. which would bring about a revolution.

**Keywords:** Circumcision, Haemostasis, Sutureless, Wound healing

### INTRODUCTION

Sutureless surgery has been used in varying surgical fields from oro/maxillofacial, cardiothoracic, cataracts and hemorrhoidal surgery.<sup>1-4</sup> In the modern time with the advent of elective surgery, more energy has been directed for achieving an efficient and uncomplicated healing of the deliberately inflicted wound.<sup>5</sup> Every surgeon dreams of perfect wound healing while performing surgeries. Although spectacular achievements are made in science and technology in recent years, yet the oldest surgical problem of perfect wound closure still persists. The use of tissue adhesive as an attractive alternative to sutures has recently been invoked immense interest in the field of wound healing but here we are advocating a newer technique of circumcision without the use of costly tissue adhesive which would bring about a revolution in the basis of surgery with excellent cosmesis.

Circumcision is a commonly performed operation and absorbable sutures have traditionally been used for closure. The two most common complications of circumcision are bleeding and wound infection.<sup>6</sup>

The objective of this study was to bring forward an innovative surgical technique of sutureless circumcision.

### METHODS

#### *Study design*

This was a prospective study where a total of 132 patients (Adults and Pediatric) were seen in outpatient department for circumcision who were fully informed about the procedure and informed consent was obtained. Study was conducted from September 1992 to July 2016.

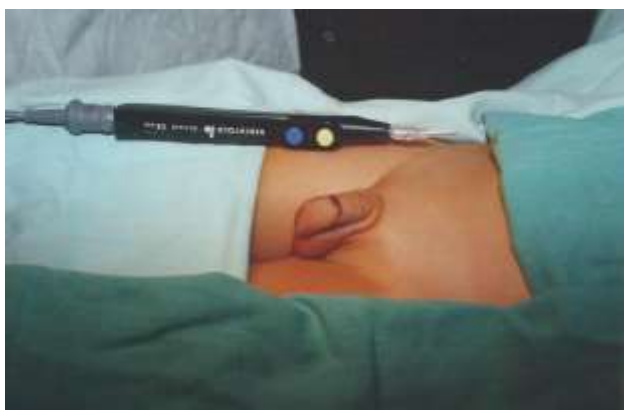**Inclusion criteria**

- Circumcision-etiology included
- BXO-Balantitis Xerotica Obliterens,
- Congenital Phimosis,
- Recurrent Balanoprophatitis

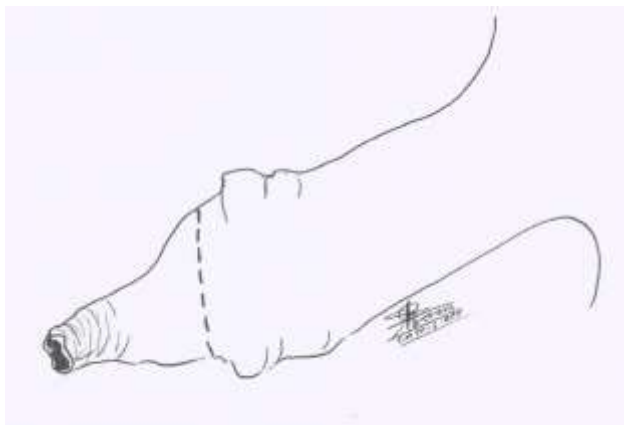
**Methods**

The operation was performed in local or spinal anesthesia.

*Step 1:* On a relaxed penis, the prepuce skin was marked circumferentially with a marking pen just about 01 mm distal to the visible impression of the Corona Glandis (Figure 1a,1b).

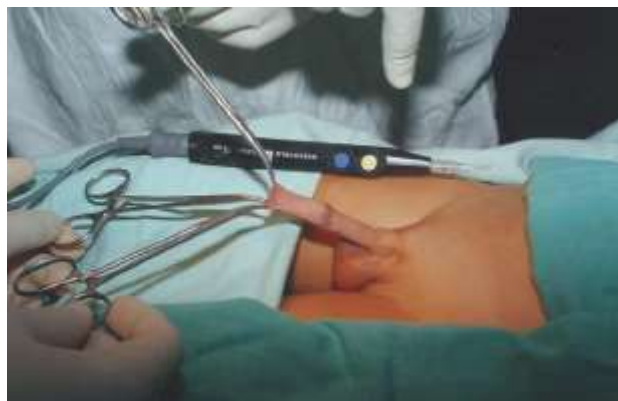

**Figure 1(a): Marking of the prepuce skin circumferentially (Step 1).**

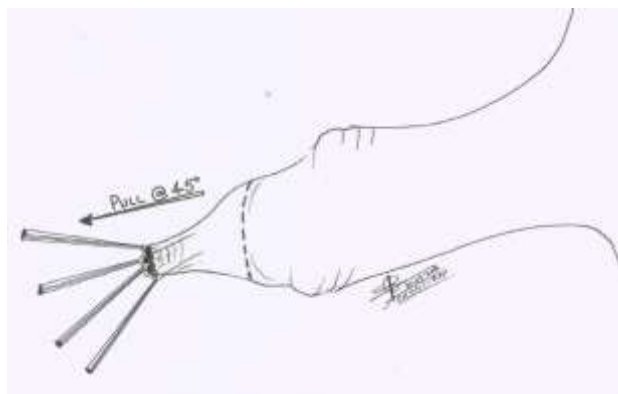


**Figure 1(b): Sketch of marking of the prepuce skin circumferentially (Step 1).**

*Step 2:* The prepuce skin was held by 4 straight artery forceps at 12, 3, 6 and 9 O'clock position and penis was placed at a 45 angle and pulled gently forwards. Metzenbaum scissors were used to break the adhesions between inner prepuce skin and glans penis (Figure 2a, 2b).

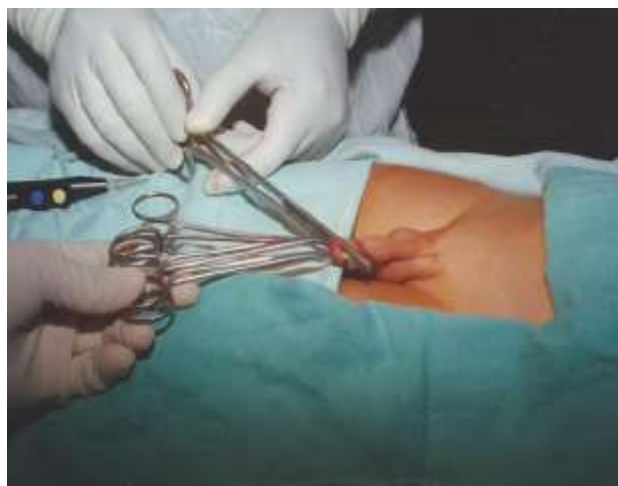

**Figure 2(a): Breaking of adhesions (Step 2).**

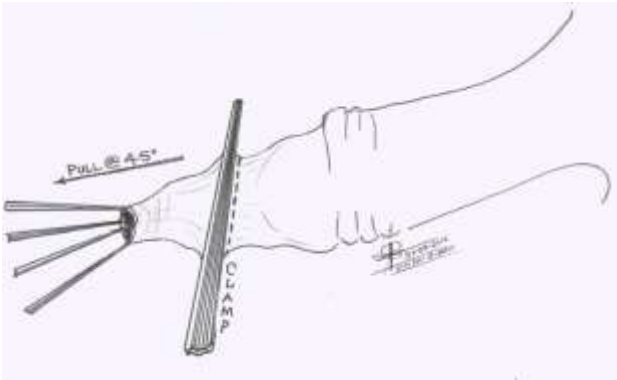


**Figure 2(b): Sketch of breaking of adhesions (Step 2).**

*Step 3:* The surgeon's left thumb and the index finger gently pinches the Glans Penis away from the prepuce skin marking and a straight Robert's artery forceps is clamped 01 mm distal to this circumferential skin marking (Figure 3a, 3b).

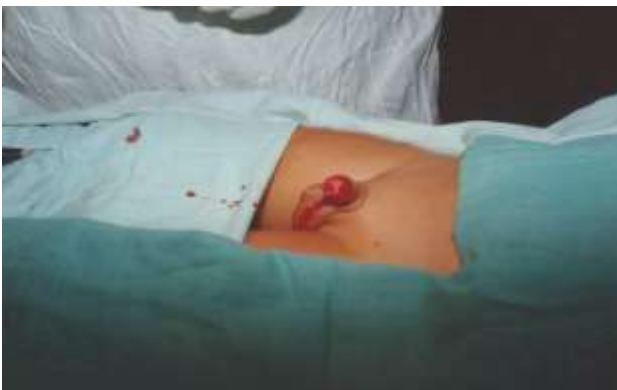

**Figure 3a: Glans penis pulled away before applying the straight Robert's artery forceps clamp on the marked prepuce skin (Step 3).**

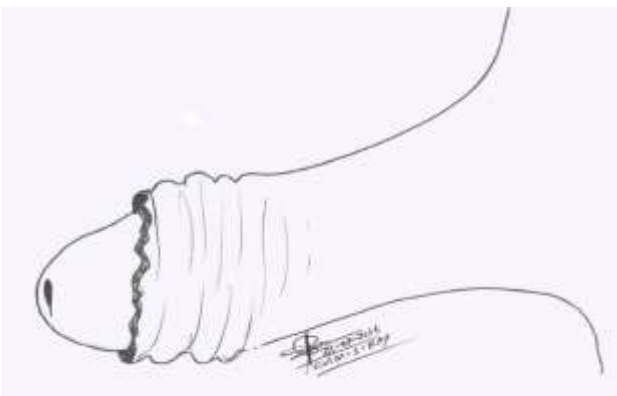


**Figure 3(b): Sketch of glans penis pulled away before applying the straight Robert's artery forceps clamp on the marked prepuce skin (Step 3).**

*Step 4:* The Prepuce is cut flush with the Robert's Straight forceps distal to the circumferential prepuce marking as the surgeon's left thumb and Index finger pinches the Glans penis away from the harm's way (Figure 4a, 4b).



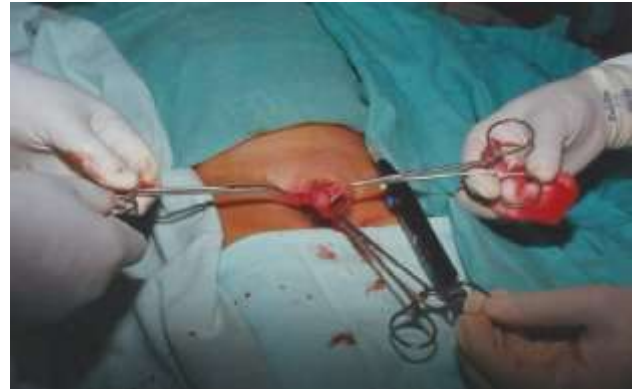**Figure 4(a): Perpuce cut flush to the straight Robert's artery forceps (Step 4).**



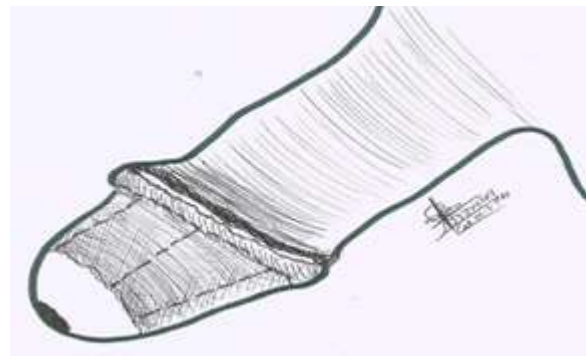
**Figure 4(b): Sketch of perpuce cut flush to the straight Robert's artery forceps (Step 4).**

*Step 5:* The lax penile skin is gently pulled down to the base of the penis, leaving the inner prepuce skin on the Glans penis.

*Step 6:* The inner prepuce skin is picked by 03 fine artery forceps tri-radially and slit with Metzenbaum scissors up to the corona glandis and snipped off radially along corona glandis. Smegma around Corona Glandis is gently rubbed off with moist gauze (Figure 5a, 5b).



**Figure 5(a): Inner prepuce skin incised tri-radially up to corona glandis and excised circumferentially (Step 5).**



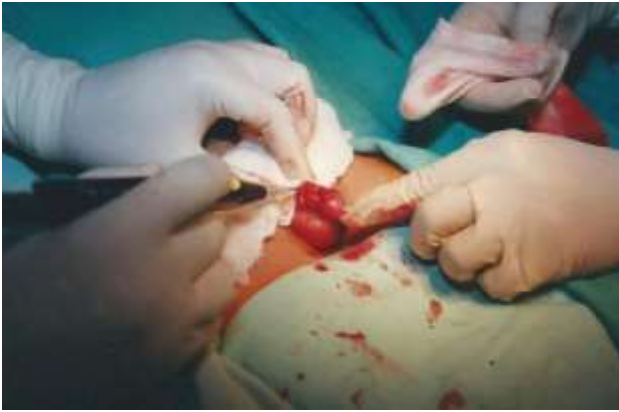**Figure 5(b): Sketch of inner prepuce skin incised tri-radially up to corona glandis and excised circumferentially (Step 5).**

*Step 7:* While keeping the lax penile skin retracted to the base of the penis, meticulous all round haemostasis is achieved with bi-polar cautery. Special care is given in coagulation haemostasis of the frenular artery without causing thermal injury to the external urethral meatus. If bi-polar electro-cautery is not available, the Mono-polar cautery with the lowest coagulation setting is used without any ill effects. No penile tourniquet was used (Figure 6a, 6b).

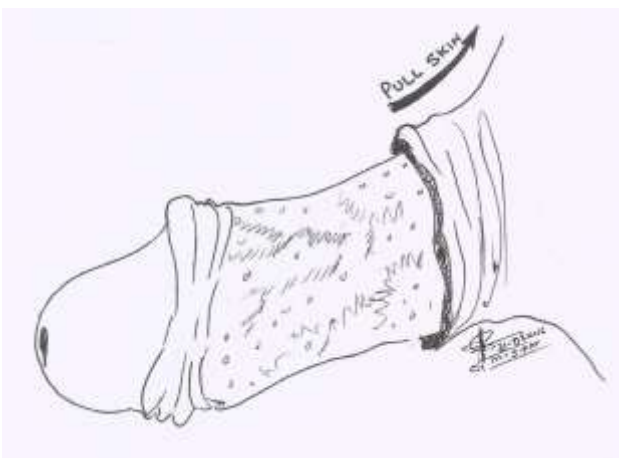
*Step 8:* External urethral meatus is gently checked and calibrated with a lubricated hemostat.

*Step 9:* Generous amount of antibiotic ointment is applied all around and the lax penile skin is gently repositioned back to Corona Glandis and dressing applied (Figure 7).

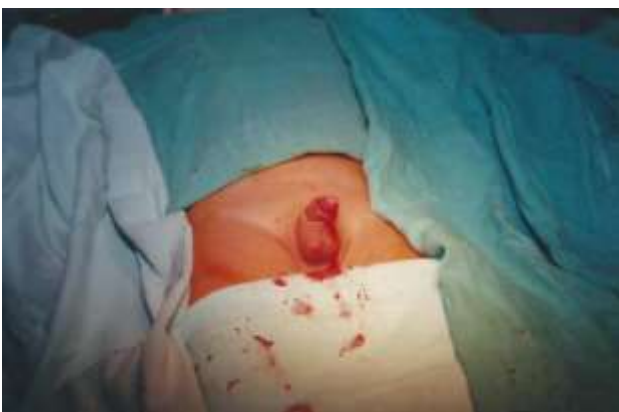*Step 10:* Penis is gently strapped to the anterior abdominal wall for overnight for pressure haemostasis (Figure 8).



**Figure 6(a): Meticulous haemostasis using bipolar cautery (Step 6).**



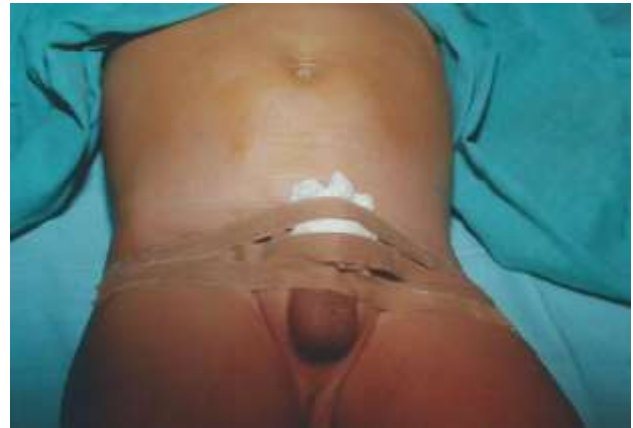**Figure 6(b): Sketch of meticulous haemostasis using bipolar cautery (Step 6).**



**Figure 7: Penile skin repositioned back to Corona Glandis and ointment applied.**

*Step 11:* In elderly patients prophylactic urethral catheterization is done with 16 Fr Foley's catheter for about 03-05 days.

Patients were allowed to bath after 48 h of surgery. Postoperative pain was assessed after 5 h interval for two times using visual analogue scale in all patients. Wound infection was defined as wound discharge with positive culture. Inflammation was defined as redness around the wound edges. All patients received postoperative antibiotic for 03-05 days. Wound healing was followed observations on 3<sup>rd</sup>, 7<sup>th</sup> and 15<sup>th</sup> day postoperatively. After one month, assessment of cosmesis was carried (Figure 9).



**Figure 8: Haemostatic compression dressing applied and strapped to the abdominal wall.**



**Figure 9: Post-operative view.**

## RESULTS

The average operating time is 15 min and the incidences of complication were very minimal. The patients were fore-warned about Oedema which could be present for 10 days post op. There were 15 adult patients which had Frenular wound infection which were managed with antibiotics and dressing.

## DISCUSSION

Male circumcision is removal of the foreskin (prepuce) from the penis. Early description of circumcision was found in cave drawings and Ancient Egyptian tombs.<sup>7</sup> According to the World Health Organization (WHO), global estimates suggest that 30% of males are circumcised.<sup>8</sup> In India incidence of circumcision in general population is approximately 33%.<sup>9</sup> Most circumcisions are performed during adolescence for cultural or religious reasons. The prevalence of circumcision varies mostly with religious affiliation, and sometimes due to culture. Male circumcision (MC) reduces the risk of HIV and other Sexually Transmitted Infections (STIs), including Human Papilloma Virus (HPV) and Herpes Simplex Virus type 2 (HSV-2), and is recommended as an important component of a comprehensive package of HIV prevention interventions.<sup>8</sup>

The circumcision wound was closed by absorbable sutures, traditionally. Currently, alternative methods are being utilized to overcome the shortcomings of the conventional closure like complications, postoperative pain, time consumed and cosmetic problems. The most recent advancement is the technique of closure carrying out without sutures. Adult and adolescent circumcision is carried out using one of the methods: Dorsal slit method or sleeve method, using 2-Octyl Cyanoacrylate (Dermabond), Gomco Clamp, Shang Ring, Plastibell Circumcision Device.<sup>10-13</sup> Surgical complications of male circumcision can include excessive bleeding, hematoma formation, sepsis, unsatisfactory cosmetic effect, lacerations of the penis and injury to the Glans, too little or too much of foreskin excised, meatal injury and subsequent stenosis, urinary retention, Phimosis and buried penis. Among all these complications, hemorrhage and infection are the most common complications.<sup>6</sup>

## CONCLUSION

Sutureless Circumcision is an excellent technique with very good results, which can be used to treat important health problems such as HIV, an important social and public health problem, thus reducing significant morbidity and mortality, especially in the developing world. In the present study, this procedure of Sutureless technique has lesser complications, like wound dehiscence and bleeding, as an excellent very meticulous homeostasis is aimed and achieved. There is reduction in operation time (average operating time is 15 min). The learning phase is very short about 02-03 cases. Another advantage is that the stitch marks are absent as compared to sutures. The post-operative cosmesis is very satisfactory. This method obviates the use of traditional dressings like Sofra-Tulle, many of which get snarled with sutures, and hence cause pain during their removal.

There is no need of sutures and expensive disposables which are not often available especially in the Third World Countries and in remote health care units. This “low equipment intensive” surgical technique is a client satisfying and extremely economical procedure-money-wise, operating time-wise, learning curve wise!

*Funding: No funding sources*

*Conflict of interest: None declared*

*Ethical approval: The study was approved by the institutional ethics committee*

## REFERENCES

1. Chisci G. Sutureless technique in third molar surgery: an overview. *J Craniofac Surg.* 2013;24(6):2210-1.
2. Jainandusing JS, Al Ansari S, Woltersom BD, WL Scheeren T, Natour E. Novel hemostatic patch achieves sutureless epicardial wound closure during complex cardiac surgery: a case report. *J Cardiothoracic Surg.* 2015;10:12.
3. Sandford-Smith J. Sutureless cataract surgery: principles and steps. *Community Eye Health.* 2003;16(48):49-53.
4. Sayfan J, Becker A, Koltun L. Sutureless closed hemorrhoidectomy: a new technique. *Ann Surg.* 2001;234(1):21-4.
5. Bucknall TE. Abdominal wound closure: choice of suture. *JR Soc Med.* 1981;74:580-5.
6. Weiss HA, Larke N, Halperin D, Schenker I. Complications of circumcision in male neonates, infants and children: a systematic review. *BMC Urol.* 2010;16:10-2.
7. Hodges FM. The ideal prepuce in ancient Greece and Rome: Male genital aesthetics and their relation to lipodermos, circumcision, foreskin restoration, and the kynodesme. *Bull Hist Med.* 2001;75:375-405.
8. WHO/UNAIDS. Male circumcision: Global trends and determinants of prevalence, safety and acceptability. World Health Organization. 2008.
9. Reynolds SJ, Shepherd ME, Risbud AR, Gangakhedkar RR, Brookmeyer RS, Divekar AD, et al. Male circumcision and risk of HIV-1 and other sexually transmitted infections in India. *Lancet.* 2004;363:1039-40.
10. Elmore JM, Smith EA, Kirsch AJ. Sutureless circumcision using 2-octyl cyanoacrylate (Dermabond): appraisal after 18-month experience. *Urology.* 2007;70(4):803-6.
11. Bhat NA, Hamid R, Rashid KA. Bloodless, sutureless circumcision. *Afr J Paediatr Surg.* 2013;10(3):252-4.
12. Barone MA, Li PS, Awori QD, Lee R, Goldstein M. Clinical trials using the shang ring device for male circumcision in Africa: a review. *Transl Androl Urol.* 2014;3(1):113-24.
13. Hamed A, Helal AA, Badway R, Goda SH, Yehya AL, Raziq MA, et al. Ten years' experience with a novel modification of plastibell circumcision. *Afr J Paediatr Surg.* 2014;11:179-83.

**Cite this article as:** Ray MS, Deepak BS. The sutureless circumcision: a novel surgical innovation. *Int Surg J* 2016;3:2150-4.