

## Original Research Article

# Neonatal small bowel obstruction due to malrotation: a clinical study

Srinivas S.\*, Reddy K. R., Balraj T. A., Gangadhar A.

Department of Paediatric Surgery, Niloufer Hospital, Hyderabad, Telangana, India

**Received:** 19 June 2017

**Accepted:** 23 June 2017

**\*Correspondence:**

Dr. Srinivas S.,

E-mail: [shantisrinivas@gmail.com](mailto:shantisrinivas@gmail.com)

**Copyright:** © the author(s), publisher and licensee Medip Academy. This is an open-access article distributed under the terms of the Creative Commons Attribution Non-Commercial License, which permits unrestricted non-commercial use, distribution, and reproduction in any medium, provided the original work is properly cited.

### ABSTRACT

**Background:** This study was done at Niloufer hospital and institute of child health, Hyderabad with an aim of evaluating the clinical presentation, diagnostic evaluation, management and outcome of malrotation of intestines in the neonates.

**Methods:** Cases of neonatal small intestinal obstruction due to malrotation presenting to the Department of Pediatric Surgery, Niloufer hospital over a period of two years were evaluated.

**Results:** A total of 38 newborns presented to our department with intestinal obstruction due to malrotation. 3/38 patients presented with extensive gangrene of midgut. 4/38 patients died during the course of treatment.

**Conclusions:** Malrotation is a relatively common cause of neonatal small bowel obstruction. A high index of suspicion is needed in neonates presenting with bilious vomiting. Early laparotomy prevents fatal complication of extensive gangrene due to midgut volvulus.

**Keywords:** Malrotation, Midgut volvulus

### INTRODUCTION

Small bowel obstruction in a neonate represents a rather small segment of neonatal pathology. However, it is responsible for most of the surgeries in newborn period. Causes of small bowel obstruction in newborn period include small bowel atresias, malrotation of gut, Hirschsprung's disease and other rare causes like congenital bands, obstructed hernias etc. Malrotation of gut is a congenital anomaly which occurs due to abnormality during intestinal rotation or fixation. This embryological insult results in a spectrum of abnormalities ranging from normal intestines to malrotation and complete nonrotation. The incidence of malrotation is 1 in 500 live births.<sup>1,2</sup> About 75% - 85% of malrotations present during early infancy.<sup>3</sup> Rest of the cases may present in childhood or even in adults. Malrotation also known as intestinal rotation abnormality (IRA), results in narrow mesentery and peritoneal bands (Ladd's) crossing over the duodenum. This puts the

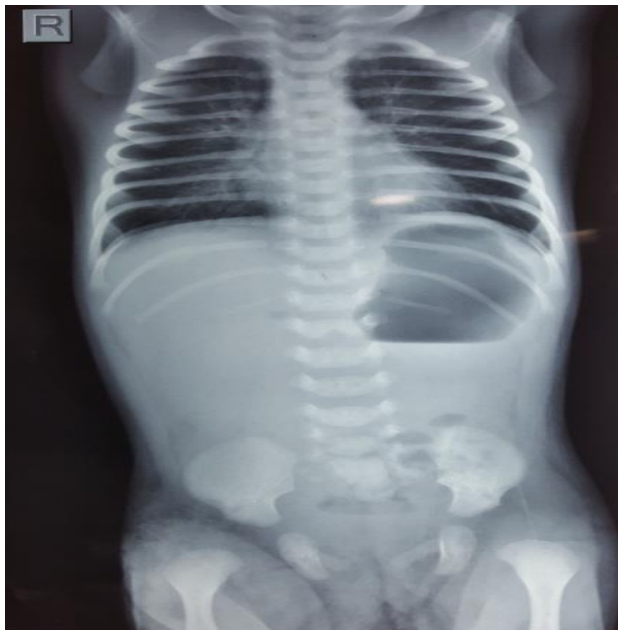patient at risk for bowel obstruction and volvulus and if the treatment of volvulus is delayed it may result in extensive gangrene of the small intestine causing massive intestinal loss and short bowel syndrome. Ladd WE in 1936 published a landmark paper in which he described the surgical steps in the treatment of malrotation, which from then on was referred to as Ladd's procedure.<sup>4</sup>

The objective of this retrospective study was to emphasize the need to have a high index of suspicion in a newborn presenting with bilious vomiting for the diagnosis of malrotation. This results in early surgical management preventing fatal complications of midgut volvulus like extensive gangrene of small bowel and short bowel syndrome.

### METHODS

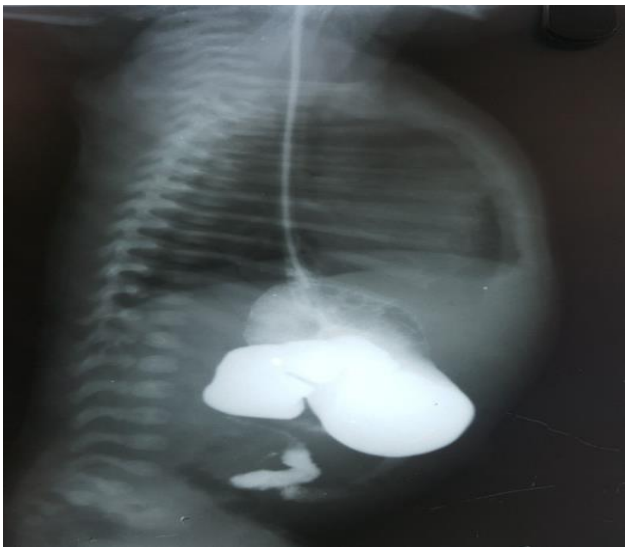Between January 2015 and January 2017, 38 neonates with small intestinal obstruction due to malrotation were

treated at Department of pediatric surgery, Institute of Child health, Niloufer hospital, Hyderabad.



**Figure 1: Plain X-ray abdomen showing partial duodenal obstruction.**

All the newborns were admitted to surgical NICU and after resuscitation a plain X-ray abdomen was performed. If the plain X-ray abdomen revealed gastro duodenal dilatation and paucity (but not absence) of distal gas, a diagnosis of partial duodenal obstruction was made and patients were subjected to upper GI contrast study. Findings like abnormal position of duodenojejunal flexure to the right of the spine, proximal small bowel loops in the right side of the abdomen and cork screw pattern (s/o volvulus) were taken as diagnostic of malrotation of gut.



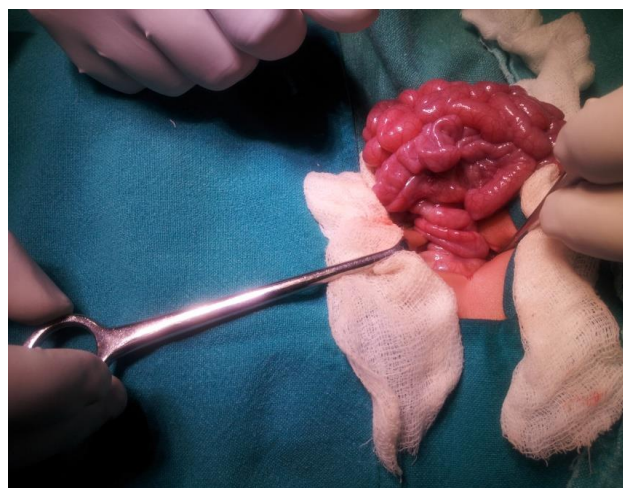
**Figure 2: Upper GI contrast suggestive of malrotation.**

After proper resuscitation, all these patients were subjected to exploratory laparotomy and Ladd's procedure. The steps of this procedure included, derotation of volvulus if present, release of Ladd's bands, straightening of the duodenum, widening of duodenocolic mesentery, ruling out intrinsic duodenal obstruction, appendectomy and placing the bowel in position of nonrotation.

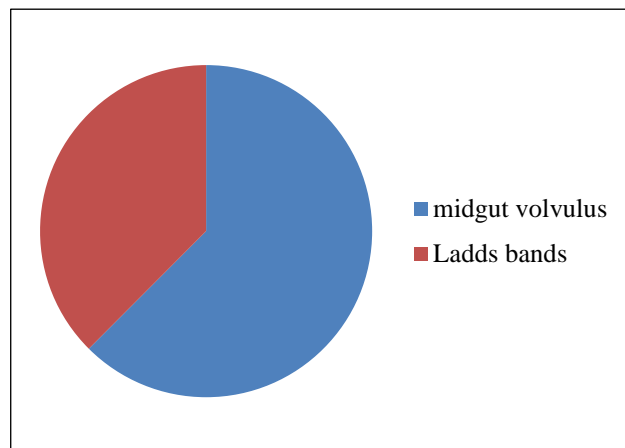
All patients were followed in immediate post-operative period.

## RESULTS

Of the 210 patients who were treated for small bowel obstruction in neonatal age group, 38 patients had malrotation of gut. All 38/38 patients had bilious vomiting as presenting symptom and all had passed green colored meconium after birth. Age of onset of symptoms ranged from birth to 23 days and the mean delay in diagnosis was 4 days. A combination of partial duodenal obstruction on plain X-ray abdomen and UGI contrast study was diagnostic in all (38/38) cases.



**Figure 3: Midgut volvulus.**



**Figure 4: Pie-chart showing causes of bowel obstruction in a neonate with malrotation.**

Findings of malrotation were evident at laprotomy in all cases. 26/38 cases (62.48%) had findings suggestive of midgut volvulus. In other cases, intestinal obstruction was due to Ladd's bands (12/38). 3 of these cases who had mid gut volvulus had extensive gangrene of small intestine (3/38 i.e. 7.9%) and in all these 3 cases extensive resection of small bowel resulted in short bowel syndrome and intestinal failure, eventually these three babies died. One more baby died on 4<sup>th</sup> post-operative day due to sepsis and disseminated intravascular coagulation. Total mortality in the present series was 4/38 i.e. 10.5%.

## DISCUSSION

Malrotation of gut is a common cause of small bowel obstruction in a newborn. In the present study, the incidence of malrotation was 18.09% among all cases of small intestinal obstructions. In the neonatal period patient's clinical presentation is obvious with bilious vomiting due to volvulus or Ladd's bands causing duodenal obstruction. In the present study, all patients presented with bilious vomiting mean delay in diagnosis was 4 days in our study. Presentation of malrotation in post neonatal period may vary from acute midgut volvulus to innocuous abdominal complaints like nonspecific abdominal pain and failure to thrive. Spigland N et al, had reported a delay in diagnosis of 5 days in the neonates and a mean delay of 1.7 years in patients presenting beyond neonatal period.<sup>5</sup> Upper GI contrast study is supposed to indicate normal rotation if duodenal "C" loop crosses midline and eventually duodenojejunal junction lies to the left of midline at the level of gastric outlet. It is important to note that normal caecal position does not rule out malrotation.<sup>6</sup> Upper GI contrast study has high sensitivity to diagnose intestinal rotational disorders. In the present study, all the patients were diagnosed by upper GI contrast. Applegate et al, published 7 keys for obtaining an accurate upper GI contrast series for diagnosis of malrotation.<sup>7</sup>

Symptoms of malrotation in a newborn are basically due to volvulus or Ladd's bands causing duodenal obstruction. Most of the studies emphasize that when neonates present with symptoms of malrotation they are at a greater risk of midgut volvulus. The frequency of midgut volvulus amongst newborns who present with malrotation ranges from 45% to 80%.<sup>8,9</sup> In the present series frequency of midgut volvulus in newborns presenting with malrotation was 62.48%. The frequency of midgut volvulus in older children is reported to be 14%.<sup>8</sup>

morbidity and mortality to a large extent is in patients of malrotation who were diagnosed after onset of volvulus.<sup>10</sup> Advances in neonatal surgery and postoperative neonatal

care especially total parenteral nutrition have significantly improved the outcome in babies with midgut volvulus. For neonates presenting with extensive gangrene due to midgut volvulus the outcome is very poor due to short bowel syndrome and intestinal failure. In the present series, all 3 newborns who had massive intestinal resection eventually died.

## CONCLUSION

Malrotation of gut is a common cause of small bowel obstruction in newborns. Diagnosis of this condition is straightforward in neonatal period. Due to high incidence of midgut volvulus and its associated fatal complications in small babies, surgical correction on an emergency basis is advisable.

## REFERENCES

1. Filston HC, Kirks DR. Malrotation-the ubiquitous anomaly. *J Ped Surg.* 1981;16(4):614-20.
2. Torres AM, Ziegler MM. Malrotation of the intestine. *World J Surg.* 1993;17(3):326-31.
3. Andrassy RJ, Mahour GH. Malrotation of the midgut in infants and children. *Arch Surg.* 1981;116:158-60.
4. Ladd WE. Surgical diseases of the alimentary tract in infants. *N Engl J Med.* 1936;215:705-8.
5. Spigland N, Brandt ML, Yazbeck S. Malrotation presenting beyond the neonatal period. *J Ped Surg.* 1990;25(11):1139-42.
6. Nagdeve NG, Qureshi AM, Bhingare PD, Shinde SK. Malrotation beyond infancy. *J Ped Surg.* 2012;47(11):2026-32.
7. Applegate KE, Anderson JM, Klatte EC. Intestinal malrotation in children: A problem solving approach to upper gastrointestinal series. *Radiograph.* 2006;26:1485-500.
8. Yanez R, Spitz L. Intestinal malrotation presenting outside the neonatal period. *Arch Dis Child.* 1986;61:682-5.
9. Stewart DR, Colodny AL, Dagget WC. Malrotation of the bowel in infants and children: a 15 years review. *Surg.* 1976;79:716-20.
10. Powell DM, Othersen HB, Smith CD. Malrotation of the intestines in children: the effect of age on presentation and therapy. *J Ped Surg.* 1989;24(8):777-80.

**Cite this article as:** Srinivas S, Reddy KR, Balraj TA, Gangadhar A. Neonatal small bowel obstruction due to malrotation: a clinical study. *Int Surg J* 2017;4:2727-9.