

Original Research Article

Thoracotomy and decortication in chronic empyema (fibrothorax), in the era of video assisted thoracic surgery

Prabhat B. Nichkaode^{1*}, Rajendra Agrawal¹, Sachin Kumar Patel²

¹Department of Surgery, Chandulal Chandrakar Memorial Medical College, Kachandur Durg - 490024, Chhattisgarh, India

²Department of Surgery, NKP Salve Institute of Medical Sciences and Research Centre, Lata Mangeshkar Hospital, Digdoh Hills, Hingna Nagpur, Maharashtra, India

Received: 01 June 2017

Accepted: 27 June 2017

*Correspondence:

Dr. Prabhat B. Nichkaode,

E-mail: rajanichkaode@gmail.com

Copyright: © the author(s), publisher and licensee Medip Academy. This is an open-access article distributed under the terms of the Creative Commons Attribution Non-Commercial License, which permits unrestricted non-commercial use, distribution, and reproduction in any medium, provided the original work is properly cited.

ABSTRACT

Background: Traditionally, open thoracotomy and decortication with or without pleurectomy is the treatment of chronic empyema in the stage of fibrothorax. Some recent reports have claimed similar clinical results by video assisted thoracoscopic surgery (VATS) with less morbidity and mortality than open surgery. Our experience with thoracotomy and decortication with or without pleurectomy for fibrothorax is reviewed, in this study. Aim was to evaluate results of the results of open thoracotomy and decortication with or without pleurectomy in patients with chronic empyema in the stage of fibrothorax.

Methods: From September 2007 to March 2012, 126 patients with diagnosis of empyema thoracic were treated at institute. Diagnosis of chronic empyema was based on-duration of signs and symptoms before definitive treatment and imaging findings- such as constriction of thoracic cage and lungs. 56 patients fulfilled the criteria for chronic empyema and then underwent open thoracotomy and decortication.

Results: 39 patients (69.6 %) were males, 17 patients (30.35 %) were females. Mean age of study group was 31.4 years. Etiology was synpneumonic effusion in 49 patients (87.5 %) sub pleural malignancy in 3 patients, traumatic haemothorax in 2 patients and ruptured hydatid cyst in 2 patients. The mean duration of symptoms and signs before definitive treatment averaged 42 days. All patients had chronic empyema (Fibrothorax), as confirmed by imaging and operative findings. There were 3 patients (5.4 %) with complications and one mortality. The postoperative length of stay averaged 11.2 days. There were no recurrences of empyema. Complete expansion of lung was confirmed by imaging in 53 patients at the end of 3 months on follow up.

Conclusions: Treatment for chronic empyema thoracic with Fibrothorax can be achieved with open thoracotomy and decortication with low complication rates and low mortality with satisfactory results.

Keywords: Chronic empyema, Decortication, Pleural empyema, Video thoracoscopy

INTRODUCTION

The treatment of empyema thoracic has evolved since its inception by hippocrates.^{1,2} Improvements of equipment and thoracoscopic techniques in 1990s, helped for expansion of applications of video-thoracoscopy.³ One

indication for video thoracoscopy in the treatment of empyema is (early phase II) fibro purulent stage; But There is an evidence that when all patients of chronic empyema were approached thoracoscopically the rate of conversion to thoracotomy was almost 61.9 % (Roberts et al).⁴⁻⁶ However, treatment at the chronic stage remains controversial.^{4,5} One point of contention is that

thoracotomy and decortication involve increased morbidity and mortality.^{6,7} Importantly, there are also reports which indicate that morbidity and mortality are low when using this procedure.^{8,9} Several reports from thoracic surgeons quote thoracotomy and decortication is the best treatment for chronic empyema especially in stage of fibrothorax.¹⁰⁻¹² We reviewed our experience with thoracotomy and decortication in the management of chronic empyema, (fibrothorax) focusing on morbidity, mortality, postoperative management, and functional results.

METHODS

The present study was carried out at a tertiary care hospital attached to a teaching institute. This is a descriptive, retrospective and observational study. Records of patients who were treated for empyema in the hospital between September 2007 and March 2012 were reviewed. The information obtained from the records included gender, age, smoking habits, comorbidities, etiology of empyema, blood tests, imaging studies, results of smears, cultures of pleural fluids, biochemical parameters of empyema, signs/symptoms and their duration until definitive surgery, procedures performed before definitive surgery, duration of operation in terms of time taken for operation, average blood loss during operation, duration of chest intubation, length of hospital stay, complications (morbidity) and mortality and follow up.

Diagnosis of empyema was confirmed by one of the following criteria: (1) drainage of grossly purulent pleural fluid, (2) pleural fluid culture or gram stain showing bacteria or (3) biochemical parameters of empyema (pH<7.2), lactate dehydrogenase level > 1000 IU/L.

Glucose level<40 mg/dl) chronic empyema was defined in accordance with the American thoracic society staging system, where stage III empyema corresponds to chronic empyema or the organizing stage.^{9,18} This diagnosis was corroborated by illness- duration of more than 15 days before definitive treatment as well as supportive imaging, such as constriction of the chest cavity.

Empyema evolves through three phases-exudative, fibrinopurulent and organized empyema-chronic /fibrothorax.

Management protocol: - in stage I empyema (exudative phase), when ultrasound examination identified anechoic collections and absent loculation, needle aspiration confirmed the presence of fluid and an thoracostomy tube was positioned. Early stage II disease (fibrinous septations, absence of homogenous echogenic loculations or thickened parietal rind on ultrasound) was evaluated for video assisted thoracoscopic adhesiolysis by creation of a single port and thoracoscope insertion. Late stage II disease and stage III disease were treated by open thoracotomy and decortication. The aims of surgery were

to perform a complete debridement and to achieve full lung re-expansion without air leaks or residual spaces or if underlying lung parenchyma is not healthy then do a lung resectional surgery.¹⁰

The surgical protocol consisted of double lumen intubation, placement of epidural catheter for post-operative analgesia. The surgical approach was oriented by imaging study findings.

Using a limited incision-latissimus dorsi preserving incision, posterolateral thoracotomy. The latter were used for large or loculated empyema. Surgery included evacuation of all purulent material and formal decortication with aim of obtaining the largest possible pulmonary expansion, without major air leaks, no residual space in the pleural cavity. In most cases, decortication of parietal pleura was partial and performed in accordance with need for complete decortication of visceral pleura.¹⁰ Single chest tube is inserted at the safe point in the 6th interspace between anterior axillary line and mid axillary line. Just at the end of operation. Confirmed that all the holes are in the pleural cavity. Connected to underwater seal drainage. Patients were extubated in the operating room itself and then sent to the ward for postoperative management. Patients were managed in the intensive care unit only when mechanical ventilation or vasopressors were required. Aggressive spirometry was given from very next day. Chest tubes were removed when there was no air leak, when the chest drainage is serous and less than 50 to 100 ml. in 24 hrs. for two consecutive days. Follow-up took place in the outpatient clinic and when needed, and patients were contacted telephonically.

RESULTS

One hundred and twenty-six patients were diagnosed with Empyema were treated over a period of 4.5 years. Of those, 58 satisfied the criteria for chronic empyema. Two patients were excluded from the study as they were managed with placement of an empyema tube as these patients did not undergo thoracotomy and decortication due to high surgical and anesthesia risk. The remaining 68 cases were treated with tube thoracostomy, video thoracoscopy and decortication, and will not be discussed.

Thus, 56 patients were managed with the previously described surgical protocol and form the basis of this study. Thirty-nine patients (69.6%) were male and seventeen (30.4 %) were female. The average age of the patients was 31.4 years (range 14 to 69 years) The cause of chronic empyema was synpneumonic effusion in 49 (87.5 %) sub pleural malignancy in 3 patients (5.3 %), trauma in 2 patients (3.5 %) and ruptured hydatid cyst in 2 patients (3.5 %) of these 34 cases were reported as nonspecific inflammation on pleural peel examination and fluid examination, 19 patients were tuberculous and three were malignant. Pre-operative pulmonary function

test 37 patients had restrictive and 19 had obstructive lung disease.

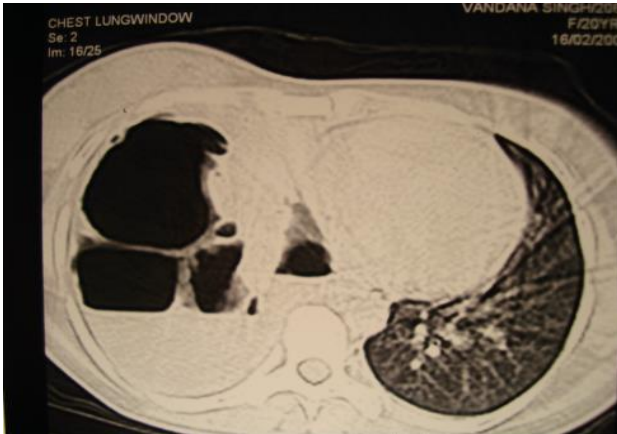

Figure 1: CT Scan of patient with Rt. Empyema.

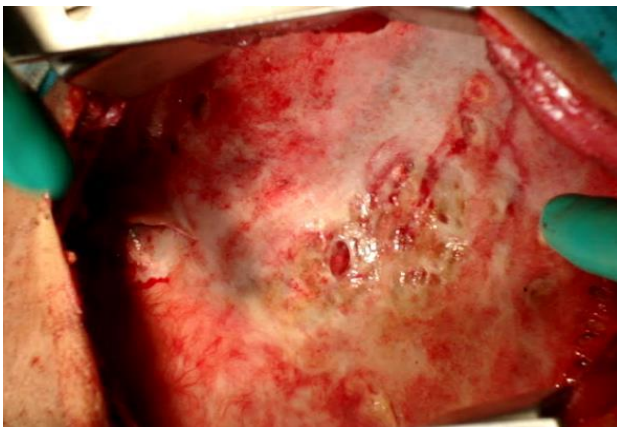

Figure 2: Thick pleura - no visible lung parenchyma, no visible lung.

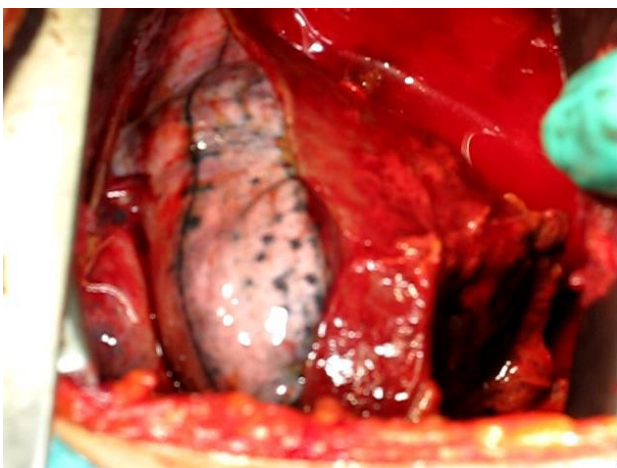

Figure 3: Lung Parenchyma Visible after decortication.

The most frequent habits included 31 (55.3 %) patients with alcoholism, 27 (48.2 %) smokers. Co-morbidities consisted of 4 (7.1 %) patients with diabetes mellitus type

II, two patients with bronchial asthma and high blood pressure and AIDS was reported in one case (1.8 %) bronchoscopy was done in all patients at least a day prior to Thoracotomy for the confirmation of any stricture in the tracheobronchial tree.

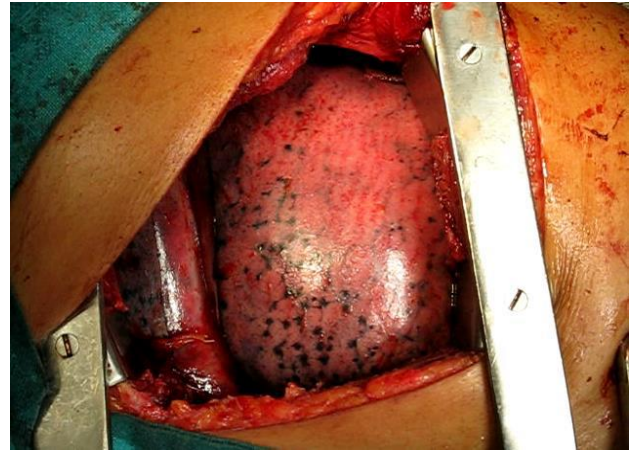


Figure 4: Complete lung expansion on the table after decortication.

Symptoms included cough in 49 (87.5 %) patients, chest pain and fever in 38 patients (67.8 %) and fever (≥ 38.5) in 34 patients (60.7 %) dyspnea was found in 41 (73.2%) patients. Thirty-nine (69.6%) patients had leukocytosis. The average white blood cell count was 12,566 per mm³ range (3900 to 26,400 per mm³) and 26 (46.4 %) patients were anemic. The average hemoglobin was 10.4 gms/dl (range 8.6 to 13.5 gms/dl) and 9.4 g/dl (range 8.0 to 11.6 g/dl) for men and women, respectively.

All patients were treated with antibiotics for a variable period before being admitted to our unit. Twenty-four patients underwent chest tube insertion before definitive surgery. Pleural fluid was routinely cultured and bacterial growth was found in 20 (35.7 %) samples. Among the assessed biochemical parameters, lactic dehydrogenase was consistently raised with an average value of 5162.4 UI/L (range 1,124- 9,320 UI/L). The average time prior to definitive surgery was 43 days (range 15 to 90 days). The chest tube was moved after an average of 5 days (range 2 to 28 days). Fifty-three patients did not have complications. Two patients developed prolonged air leak (minor bronchopleural fistula) that was managed with Heimlich valve and, it was necessary to leave an empyema tube for 4 weeks due to purulent drainage and a residual cavity. There was no mortality or recurrence of empyema. The average post-operative stay was 11.2 days (range 5 to 42 days) The patient who remained in the hospital for 42 days after thoracotomy and decortication was septic with empyema cavity.

The average operative time was around 130 to 150 mins. The average blood loss is around 100 to 150 ml. But transfusion was not given during surgery in any patient.

DISCUSSION

It is generally accepted that pleural empyema should be treated early to avoid complications, extensive operations and lengthy hospital stay.^{11,12} There are some patients for whom initial treatment is not possible and in whom chronic empyema will develop, mainly due to delayed diagnosis or late referral. At this stage, the standard treatment is open thoracotomy and decortication. Historically, other surgical procedures have been practiced, including open window thoracotomy, rib resection, thoracoplasty, Claggett's procedure and percutaneous drainage guided by ultrasound or CT.¹¹⁻¹³ With the increasing popularity of minimally access surgery, video-thoracoscopy has been proposed for the treatment of chronic empyema.¹³ There are reports in which open procedures have shown higher morbidity and mortality.¹⁴ It is for those reasons that we decided to analyse our experience with open thoracotomy and decortication in the management of chronic empyema. In western world, most cases of empyema are diagnosed early in first two stages, therefore Video assisted thoracic Surgery is the choice of treatment.¹⁵ In Indian scenario usually the first option in the initial stages is tube thoracostomy and wait so the disease evolves through two early phases of empyema and patient often presents to the surgeon in the stage of fibrothorax. During our analysis, we experienced lots of technical difficulties in VATS. Most common one was Injury to the underlying lung Parenchyma.¹⁴ We have in our series 9 patients who needed lung resectional surgery at the time of decortication as the underlying lung parenchyma was not healthy, especially those patients where empyema was of tubercular origin. In all those cases, the lung resectional surgery was technically difficult by VATS and so thoracotomy was a better option. Entering the thoracic cavity was a big problem in VATs as, in all our patients there was crowding of ribs and many patients needed rib resection during decortication.

In study cases, pleural fluid cultures showed bacterial growth in 35.7 % of patients, which is comparable to several previous reports.¹⁵ Additionally, lactic dehydrogenase, was consistently elevated with an average value of 5162.4UI/L Soriano et al established a direct relationship between higher levels of lactic dehydrogenase and longer disease duration Imaging studies consisted of chest roentgenograms, ultrasound and chest CT.^{15,16} These studies demonstrated a thick pleural cortex and constriction of thoracic cage. Chest CT was particularly useful for showing the pleural thickening and, loculations, size of empyema and evidence of constriction of thoracic cage.¹⁶ There are no specific indicators to confirm the chronicity of empyema; however in this study, the presence of pleural cortex and the constriction of the thoracic cage coupled with evolution times more than 15 days was indicative of chronic empyema in all cases.¹⁷ During surgery, reduction in the intercostal space size and the fibrous pleural cortex was evident, these are the features of

fibrothorax. In addition to showing the characteristic of the empyema, chest CT allows the surgeon to locate and determine the best surgical approach, either limited or posterolateral thoracotomy.^{16,17} We have routinely performed chest CT before surgery for all patients diagnosed with empyema at our Institute. In present work, it is important to note that chest intubation time averaged five days, and post-operative stay averaged 11.2 days. Only three patients presented with complications and there was no mortality. These results show shorter duration of chest intubation, fewer postoperative days and less or similar complication rate and mortality as compared to patients treated with video-thoracoscopy.^{16,17}

The definitive results of the surgical procedure were assessed using the scheme proposed by Melloni et al which takes into account elimination of symptoms, normalization of white blood cell count, removal of pleural drains, return to pre- illness physical activities, and roentgenography.^{16,17} The results of all patients in this study were classified as “ very good “symptoms resolved, white blood cell counts become normal, no patients required a new pleural drain (one patient had a chest tube converted to an empyema tube for 4 weeks) and patients returned to their regular activities by post-operative week 4. Roentgenography did not show residual pleural effusion, and pulmonary expansion was complete or slightly diminished. Spirometry for evaluation of functional results was not used on regular basis, as there were no points of comparison, since many patients were too ill to establish a pre-surgery baseline. Additionally, spirometry during illness would not reflect the real spirometric values of the patient.¹⁷

This study had several limitations; the sample size was relatively small although all patients were operated on by a single surgeon using the same approach and technique. The number of days range, from symptom manifestation to definitive surgery might be considered low, but these patients were classified using the staging system of American thoracic society.¹⁸ It is not always possible to recognize the exact beginning of the disease process due to the indolent presentation of infection in many patients. Empyema treatment is included in the category 3b level evidence based medicine and expert opinions.^{17,18} In present study open thoracotomy and decortication was found to be an excellent surgical procedure with low morbidity and mortality. Functional results were also excellent, as all patients returned to normal activities that they use to perform before surgery. Open thoracotomy and decortication is the standard treatment for chronic empyema, but there have been no prospective, randomized studies comparing open thoracotomy and decortication with video-thoracoscopy. Conversions to open thoracotomy are more frequent than after other thoracoscopic procedures, but this should be considered an exercise of sound surgical judgment rather than a failure of the technique. To mention a few contraindications for video thoracoscopy-prior

thoracotomy, prior talc pleurodesis, and previous empyema are relative contra indications. The inability to tolerate single lung ventilation and the presence of fibrothorax are absolute contraindications for VATS.⁵ Patients who develop empyema following esophageal perforation should not be managed thoroscopically but by thoracotomy.¹⁸

CONCLUSION

Treatment must be based on radiological staging and clinical status. Open thoracotomy and decortication is meant for those patients who have chronic empyema in the stage of fibrothorax, where there is a technical difficulty in VATS for fear of injury to underlying lung parenchyma. It can also be considered as a preferred procedure over VATS when the underlying parenchyma during decortication was seen to be diseased, and you prefer to do lung resectional surgery. The VATS procedure is choice of treatment may be in the fibro purulent stage. The procedure of open decortication is associated with acceptable morbidity and low mortality. Long term functional results are especially promising.

More studies comparing open method and minimal access method are necessary to define with certainty which patients would benefit from open thoracotomy and which ones for video thoracoscopy. In stage II and stage III empyema, open thoracotomy and decortication is followed by drain removal within 5 days, prompt hospital discharge, and complete resolution. Using these results as a benchmark, alternative treatments should only be undertaken in carefully selected patients.

Funding: No funding sources

Conflict of interest: None declared

Ethical approval: The study was approved by the institutional ethics committee

REFERENCES

1. Yim APC. Paradigm shift in empyema management. Chest. 1999;115:611-2.
2. Somers J, Faber LP. Historical Developments in the management of empyema. Chest Surg Clin North Am. 1996;6:403-18.
3. Waller DA, Rengarajan A. Thoracoscopic decortication: a role for video assisted surgery in chronic post pneumonic pleural empyema. Ann Thoracic Surg. 2001;71:1813-6.
4. Hope WW, Bolton WD, Stephenson JE. The utility and timing of intervention for para pneumonic empyema in the era of video assisted thoracoscopy. Am Surg. 2005;71:512-4.
5. Roberts JR. Minimally invasive surgery in the treatment of empyema: intraoperative decision making. Ann Thoracic Surg. 2003;76:225-30.
6. Luh SP, Chou MC, Wang LS, Chen JY, Tsai TP. Video-assisted thoracoscopic surgery in the treatment of complicated para pneumonic effusions or empyema. Chest. 2005;127:1427-32.
7. Chan DT, Sihoe AD, Chan S, Tsang DS, Fang B, Lee TW, et al. Surgical treatment of empyema thoracic; Is video assisted thoracic surgery "better than thoracotomy? Ann Thoracic Surg. 2007;84:225-31.
8. Lardinos D, Gock M, Pezzetta E, Buchli C, Rousson V, Furrer M, et al. Delayed referral and gram negative organisms increase the conversion thoracotomy rate in patients undergoing video assisted thoracoscopic surgery for empyema. Ann Thoracic Surg. 2005;79:1851-5.
9. AATS guidelines for management of empyema, AATS empyema guideline working group, Shen RK MD, 95th, AATS annual meeting; Seattle WA; 2015.
10. Alegre RA, Garisto GD, Zobede S. Open thoracotomy and decortication for chronic empyema. Clinics. 2008;63(6):789-93.
11. Thourani VH, Brady KM, Mansour K, Miller JJ, Lee RB. Evaluation of treatment modalities for thoracic empyema: cost effective analysis. Ann Thoracic Surg. 1998;66:1121-7.
12. Soraino T, Alegre J, Aleman C, Ruiz E, Vasquez A, Carrasco JL, et al. Factors influencing the hospital stay in patients with bacterial pleural effusion. Respiration. 2005;72:587-93.
13. Light RW. Para pneumonic effusions and empyema. Proc Am Thorac Soc. 2006;3:75-80.
14. Drain AJ, Ferguson JJ, Sayeed R, Wilkinson S, Ritchie A. Definitive management of advanced empyema by two window video assisted surgery. Asian Cardiovasc Thorac Ann. 2007;15:238-39.
15. Melloni G, Caretta A, Ciriaco P, Negri G, Voci C, Augello G, et al. Decortication for chronic para pneumonic: empyema results of prospective study. World J Surg. 2004; 28:488-93.
16. Kearney SE, Davis CW, Davis RJ, Gleeson FV. Computed tomography and ultrasound in para pneumonic effusion and empyema. Clin Radiol. 2005;55:542-7.
17. LeMense GP, Strange C, Sahn SA. Empyema thoracic, therapeutic management and outcome. Chest. 1995;107:1532-7.
18. Andrews NC, Parker EF, Shaw RR, Wilson NJ, Webb WR. Management of Non-tuberculous empyema. Am Rev Respir Dis. 1962;85:935-6.

Cite this article as: Nichkaode PB, Agrawal R, Patel SK. Thoracotomy and decortication in chronic empyema (fibrothorax), in the era of video assisted thoracic surgery. Int Surg J 2017;4:2741-5.