

Original Research Article

Cancer penis evaluation of role of prophylactic inguinal lymph nodes dissection

Prabhat B. Nichkaode^{1*}, Rajendra Agrawal¹, Sayali Kulkarni²

¹Department of Surgery, Chandulal Chandrakar Memorial Medical College, Kachandur, Durg-490024, Chhattisgarh, India

²Department of Gynaecology and Oncology, Gujarat Cancer and Research Institute, Ahmedabad, Gujarat, India

Received: 01 June 2017

Accepted: 27 June 2017

*Correspondence:

Dr. Prabhat B. Nichkaode,

E-mail: rajanichkaode@gmail.com

Copyright: © the author(s), publisher and licensee Medip Academy. This is an open-access article distributed under the terms of the Creative Commons Attribution Non-Commercial License, which permits unrestricted non-commercial use, distribution, and reproduction in any medium, provided the original work is properly cited.

ABSTRACT

Background: Incidence of penile cancer is considerably variable across the globe; this disease is uncommon in the western world. But it is not uncommon to see the disease in Indian subcontinent. Also, it is not uncommon to see Penile growths with palpable unilateral or bilateral lymph nodes. In this retrospective observational study, we would like to present our data of 31 cases of Penile cancer with variable presentations, in terms of palpable groin lymph nodes. FNAC from palpable lymph nodes may not be diagnostic of metastasis. It is said that battle of cancer penis is either won or lost depends on how you deal with groin. It is a clear understanding that in presence of positive groin nodes Lymphadenectomy is the choice of treatment but it is unclear, how to deal with negative groin? In this study we present experience, in terms of deal with the groin lymph nodes aggressively, even when they not palpable for a better outcome after balancing the morbidity of the procedure. Aim was to evaluate the role of early prophylactic inguinal node dissection in patients with squamous cell cancer of Penis.

Methods: This retrospective observational study was carried out at tertiary care teaching institute from 2003 till 2012. The clinical, investigational, operative, pathology details and follow-up data were collected from patient records.

Results: Study showed data of 47 patients treated during the period from 2003 to 2012 and included 31 patients in this study, 21 patients (67.74%) presented with palpable inguinal nodes at the time of primary presentation. FNAC from these lymph nodes could prove metastasis, only in 16 patients (76.19 %). 5 patients (23.80) on FNAC had no metastasis. Remaining 10 patients were without lymph node enlargement at the time of primary presentation. Patients presented without palpable lymph nodes were offered modified inguinal block dissection. Histology showing 8 nodes positive for metastatic disease. And were FNAC was negative 4 (80 %) out of 5 patients with negative nodes shown positive for metastasis.

Conclusions: This retrospective observational study concludes with fact that palpable lymph nodes in the groin, is no doubt an indication for Inguinal node dissection but even when nodes are negative on FNAC or not palpable then prophylactic lymph nodes dissection should be undertaken. Delay in inguinal lymphadenectomy in non-palpable nodes you may lose the battle on cancer penis, as many reports say that, delayed lymphadenectomy has a strong impact on the survival. The only drawback with prophylactic lymph node dissection is the associated morbidity. But with modified procedures this can be very well minimized.

Keywords: Inguinal node, Lymph node dissection, Morbidity, Outcome, Penile cancer

INTRODUCTION

Penile cancer is an uncommon cancer in men. Incidence of penile cancer is significantly variable across the globe. As it is rarely seen in the Western world.¹ In Indian scenario penile cancer is not an uncommon disease, and it is associated with definite morbidity and mortality.¹ Incidence is less than 1/100000 males in Europe and the United states, this comes to 0.4-0.6 % of all malignancies.^{2,3} Indian cancer Registry records account it for 2-6% of all malignancies. Indian incidence ranges from 0.7-3per100000 males There is considerable difference in incidence in Urban and Rural population i.e. 0.7-2/100000 men and 3.2/100000 men, respectively at my Institute the incidence of cancer penis is between 0.5 to 1% of all malignancies.^{4,5} We do not know the exact etiology of this disease but Phimosis, chronic inflammatory conditions, HPV DNA are probable important risk factors associated with carcinoma Penis.⁶

The common most histological type of penile cancer is squamous cell type, tends to arise from epithelium of inner prepuce and glans.²⁻⁵ Natural history suggests, the spread occurs to ileo inguinal lymph nodes in quite a predictable manner.⁶⁻⁹

Incidence of palpable groin nodes during initial presentation is around 30% to 60%. More than 50% are positive for a metastatic disease but rest of the enlarged nodes are because of amatory reaction.⁹⁻¹²

Thus, it must address to complex surgical issues involving the management of the regional lymph nodes. which is of critical importance to both outcome and quality of life for these patients.^{13,14} Though we have so many pathological criteria, clinical guidelines available for decision making, still it remains a complex issue as far as predicting the outcome.^{14,15} An improved understanding of the natural history of the disease, better technology have improved the cure rates from 50% in 1990s to almost 75-80% in recent years.¹⁵⁻¹⁷ The presence of metastatic disease produces considerable morbidity in patients with penile cancer. Thus, we aimed present study to act aggressively and do prophylactic lymph node dissection rather than waiting for lymph nodes to appear or then thinking that they are enlarged because of amatory reaction.^{18,19}

METHODS

This retrospective observational study was carried out at tertiary care teaching institute from September 2003 till December 2012. The clinical, investigational, operative, pathology details and follow-up data were collected from patient records and entered a prestructured chart. Only those patients are included who were in follow up and relevant clinical details could be retrieved, all other patients were excluded. Thus, we could include 31 patients out of 47 patients of cancer penis. Majority of our patients belonging to the age group 40 years and

above, with mean age between 46 to 60 years. we had 3 patients who belong to the age of 26 to 32 years.

Among 31 cases diagnosed with pathological diagnosis of Squamous cell cancer of Penis, 21 patients had clinically significant unilateral inguinal nodes at the time of primary presentation. FNAC done from inguinal nodes was positive only in 16 patients. In remaining five patients the FNAC was negative and rest 10 patients had no palpable lymph nodes. We did radical inguinal block dissection in 16/ 31 patients with simultaneous partial or total penectomy. And remaining 15 patients were subjected for modified inguinal block dissection with primary penile surgery. We did not offer a course of antibiotics to those five patients where FNAC was negative.

Technique

Decision making for primary disease site depends on the standard criteria, if you can preserve the functional penis from the palpable margins of Tumor. Appropriate techniques like partial penectomy or total penectomy with perineal urethrotomy were used. Simultaneous Inguinal node dissection was done in all 31 Patients.

Limits of dissection

The classic radical groin dissection involves dissection of superficial and deep inguinal nodes in a quadrilateral bounded by the inguinal ligament superiorly, a line extending 15 cm down from the pubic tubercle medially, a line extending 20 cm down from the anterior superior iliac spine laterally and a line connecting the inferior ends of the lateral and medial lines. A modification of the radical inguinal lymphadenectomy involves removal of superficial and deep nodes within the triangle bounded by the inguinal ligament, the sartorius muscle laterally and the adductor longus muscle medially, with skin flaps containing all tissue above the Scarpa fascia, and sparing of the saphenous vein and its tributaries, limiting the lateral extent of the node dissection to the femoral vessels. Catalona pioneered a well-adopted modification that shortens the skin incision, limiting the lateral extent of the node dissection to the femoral vessels.¹⁶ Radical dissection remains the procedure of choice for cases of documented nodal metastases to the groin.

All these procedures were done by an experienced surgeon of a level of associate professor. Follow up record includes, characters of primary tumor, like grade, T stage, Lymphovascular invasion and correlated with pathologically positive nodes. We also followed the grading system, as well differentiated (Grade-1) moderately differentiated (Grade-2) poorly differentiated (Grade 3). Complications in terms of major and minor, within 30 days of operation and 30 days after operation were noted. Complications needing any second procedure is also recoded.

RESULTS

Among 47 cases with pathological diagnosis of squamous cell cancer of penis, 31 patients were included in the study. Remaining 16 patients were not included because they did not fulfil the inclusion criteria-3 of them had disseminated systemic disease, 5 patients lost to follow up after 3 years, Other 8 patients the data was incomplete. Out of 31 patients included, 21 patients (67.74 %) had clinically significant nodes at the time of primary presentation. But FNAC from inguinal nodes was positive only in 16 patients (76.19 %). We did radical inguinal block dissection in 16 patients with simultaneous Partial or total penectomy. Modified inguinal node dissection was done in remaining 15 patients surprisingly histopathology revealed positive nodal metastasis in 27 patients (87.09 %) out of 31 patients. Interestingly 4 out of 5 patients, (80 %) where the FNAC from inguinal nodes was negative were turned out to be node positive on histopathology.

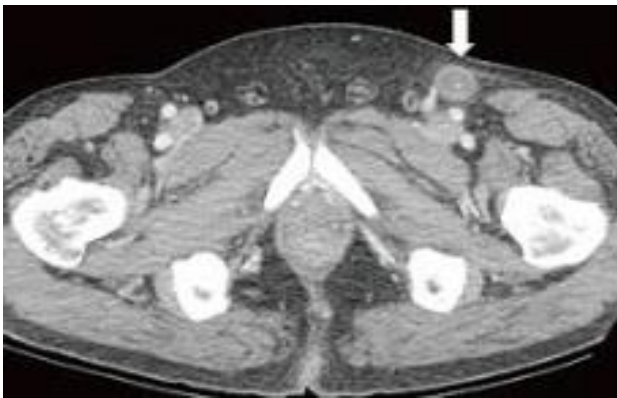


Figure 1: Imaging by CT scan of groin nodes.

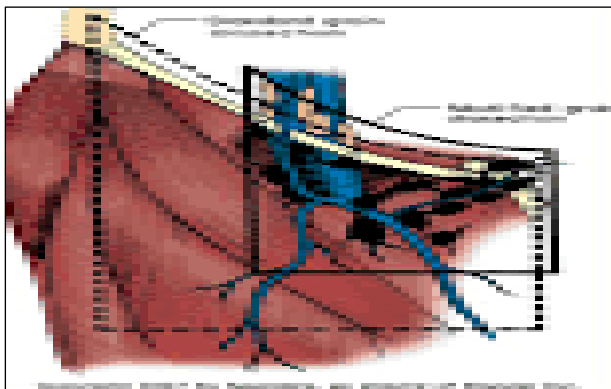


Figure 2: Limits of modified inguinal node dissection.

The average period for follow up of these patients 4-7 years. Mean age of our patients was 40 years and above with age ranging between 26 to 78 years. In all our patients, there was a pathological diagnosis of squamous cell carcinoma of penis. We did not give them a course of antibiotics and waited even when FNAC was negative. Concern was morbidity of surgical procedure in node

negative patients, so here we did Radical inguinal node block dissection in patients with positive nodes, and modified inguinal node dissection in patients with negative nodal disease, and or patients with no palpable nodes. This addresses to morbidity associated with radical inguinal block dissection in node negative patients. Risk stratification has also been done in present study before and after surgery. It was in terms of Stage and grade of the disease. In 26 out of 31 (83.87%) Patients had T2 N1 disease. Rest 5 patients (16.12 %) the disease was T3N1. It was a Grade 1 (well differentiated cancer) disease in 23 patients. 6 Patients (74 %) had Grade II (moderately differentiated cancer) and remaining 2 patients (6.4 %) had Grade III (poorly differentiated) cancer.

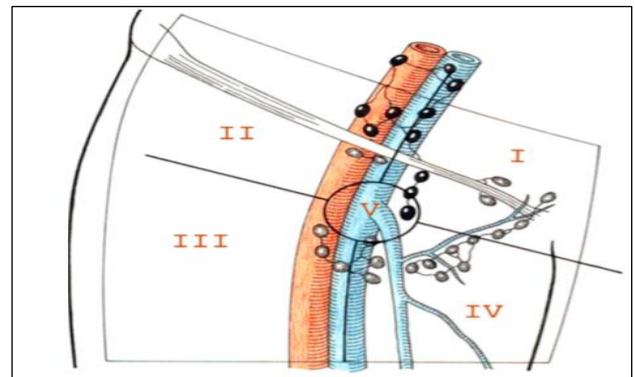


Figure 3: Limits of radical inguinal node dissection.

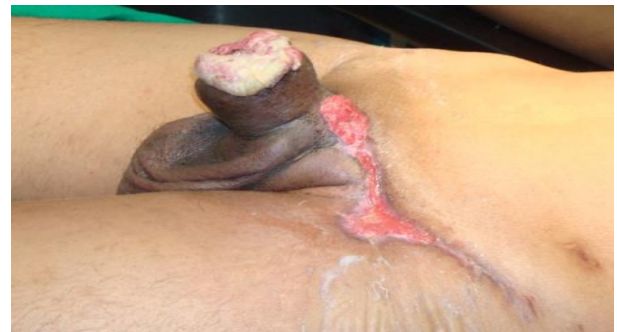

Figure 4: Poorly differentiated cancer penis with one sided lymphadenectomy done outside.

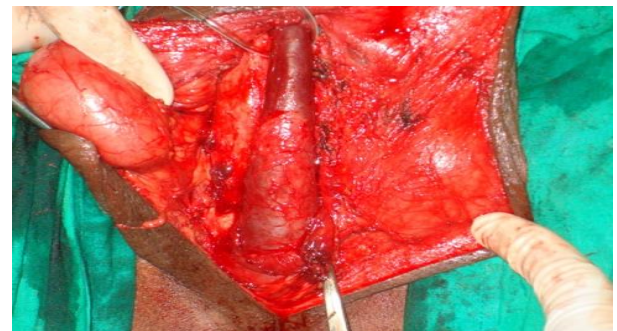

Figure 5: Planned total penectomy with other side inguinal lymphadenectomy.

Partial penectomy was done in 26 patients. 5 patients had total penectomy with perineal ureterostomy. Two patients with poorly differentiated carcinoma had Lymphovascular invasion at the time of 1st operation with involvement of pelvic lymph nodes, develop metastasis in the other groin so underwent inguinal block dissection on the other side also.

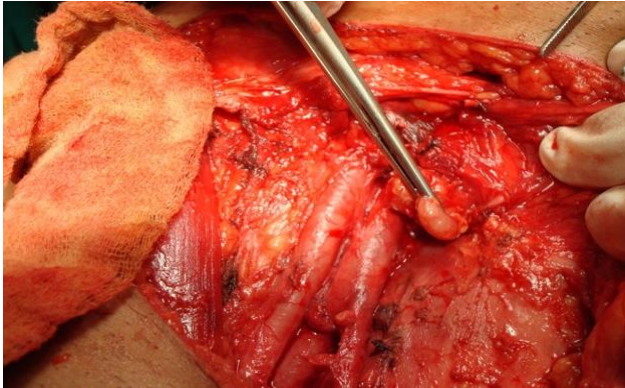


Figure 6: Inguinal lymph node dissection Cloquet's lymph node.

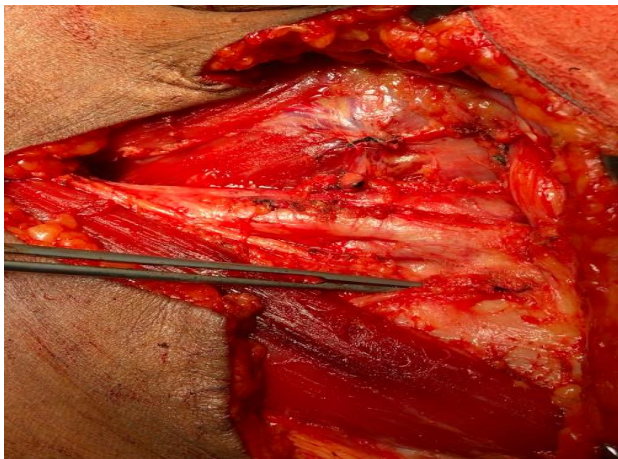


Figure 7: Completed inguinal block dissection.

Left groin lymph nodes were palpable in 16 patients while only 5 patients had nodes in the right groin. When number of involved nodes were counted then average 3-6 were involved. This is to add adjuvant radiotherapy to the patients with more than 4 positive nodes. Morbidity has long been of great concern with radical groin dissection and is reported in up to 57% of groins in 39% of patients.¹³ In our series we have morbidity in terms of complications. We divided them in major and minor complication, (decided by requirement of second procedure or just routine treatment) So also, we noted morbidity in first 30 days and morbidity after 30 days. In patients of modified lymphadenectomy incidence of complications was low and all were minor complications. But most of the morbidity is seen with radical lymph node dissection patients. Common complications causing morbidity 1) lymphedema, 2) wound infection 3) wound edge necrosis 4) lymphorrhoea. Average time required

for surgical procedure was almost 90 to 120 mins. With average blood loss was 30-50 ml.

Follow up protocol was-every 3 months for 1 year, every six months for 2 years then every year for 3 years or if patient has any complaints. We had 2 patients poorly differentiated squamous cell carcinoma-had later underwent inguinal node dissection on other side. Along other 1 patient who had a disease involving the whole thickness of penis. There was no patient develop local or regional recurrence on the side of operation. We lost 3 patients after a follow up of almost 7 years.

DISCUSSION

The penile cancer though a rare malignancy with incidence varying (0.4 to 20 %), but not an uncommon malignancy with significant morbidity and mortality in Indian subcontinent.¹⁻⁴ It has got a variable presentation across the globe. The spread of carcinoma penis is mainly lymphogenic-in 96 % cases management of inguinal nodes forms major crux in outcome of patients with cancer penis.⁵⁻⁷ Inguinal lymph node management is the key issue if you want to win a battle against cancer penis.

Incidence of inguinal node involvement in cancer penis is almost 30 to 60 % at the initial presentation.⁸⁻¹⁰ In present study 21 (67.74 %) of 31 patients had palpable nodes at the time of initial presentation. Incidence of distant metastasis at the time of primary presentation is as low as 1.9% to 7%.¹¹ We have not included patients with distant metastasis in present study. In the present study, the number of positive nodes on FNAC 16 (76.19 %) out of 21 patients. After inguinal node dissection, the number of patients with metastatic deposits were 27 (87.09 %). This suggest that even if nodes are not palpable, > 20 % patients have lymph nodes on dissection and micro metastasis was present in almost > 70% patients. This suggest that there is a considerable inaccuracy in clinical assessment of groin.^{12,13} The Involvement of groin nodes is quite sequential and a predictable. Left groin nodes are involved more frequently 67 % than right 27%, bilateral node involvement was 4 %.^{14,15}

Table 1: Patients with clinically palpable nodes with FNAC from palpable nodes.

Patients with palpable nodes	Non-palpable nodes	FNAC positive	FNAC negative
21	10	16	5

Imaging investigations like USG alone has very little sensitivity and specificity to detect morphologically metastatic node, But Ultrasound in combination with fine- needle aspiration cytology (FNAC) has a sensitivity and specificity of 39% and 100%, CT Scan has sensitivity of 36%, MRI with 100 % sensitivity, 97 % specificity PET CT with positive predictive value of 94% and negative predictive value of 96 % in detecting enlarged

nodes with micro metastasis.¹⁶⁻¹⁹ The imaging investigations though sensitive but they cannot be as definitive as histopathology or cytology. Considering this fact nonsurgical means of determining the true status of the regional lymph nodes are also inaccurate. We did not have facility of investigations like sentinel node biopsy, minimally invasive dynamic sentinel node biopsy or microparticle MRI scan to detect metastatic disease.²⁰⁻²² In study we noticed, lymph node involvement also depends on the biology of primary disease, stage and grade, with lymphovascular invasion and anatomical site of the penile involvement (Table 2). We did not do molecular work up in these patients for predicting the metastasis in inguinal nodes but even after extensive work done in literature these markers (Ki67, HPV DNA) did not accurately predict the metastasis.^{23,24}

Table 2: Anatomical site of penile involvement in cancer penis.

Site of penile cancer	Number of patients	Histological type
Prepuce	Nil	Nil
Glans and prepuce	26	Squamous cell cancer
Shaft or glans and part of Shaft	5	Squamous cell cancer

Many reports suggest that histologically positive nodes cure is almost 20-60 %.^{15,24,25} And 5 years recurrence free rates reported 75 to 95 %.^{26,27} Considering these facts we decided to adopt the aggressive approach of no observation in cases of non-palpable inguinal nodes and prophylactic lymph node dissection. Many reports shown improved survival.³¹ Observation and recurrence in

follow up, these patients are in danger as far as survival and (bad) outcome.²⁸

Table 3: Grade wise lymph node involvement.

Histological grade	Number of patients with positive inguinal nodes	Number of patients with pelvic nodes
Grade I	23	Nil
Grade II	06	Nil
Grade III	02	02

Morbidity has long been of great concern with radical groin dissection and is reported in up to 57% of groins in 39% of patients.²⁹ Radical inguinal lymphadenectomy has demonstrated increase morbidity as compared with modified approaches.³⁰ In study when we calculated the morbidity in terms complications though we have definite morbidity in procedures associated with radical dissection but very low morbidity in patients with modified inguinal node dissection. Historically, studies have reported a 30% to 50% incidence of major morbidity and a mortality rate of up to 3% with radical lymphadenectomy. Recent series have reported a much more acceptable complications rate of approximately 15%.^{30,31}

Table 4: Side wise involvement of inguinal nodes in cancer penis.

Patients with nodes left groin	Patients with nodes left groin
16 (76 %)	5 (23%)

All the morbid conditions are related to 1) lymphedema, 2) wound infection 3) wound edge necrosis 4) lymphorrhoea (Table 5).^{30,31}

Table 5: Complications/morbidity associated with inguinal node dissection.

Complications	After radical inguinal lymphadenectomy	After modified lymph node dissection
Lymphedema	4 out of 21 (19.04 %)	1/10 temporary (10%)
Lymphocele	1 out of 21 (4.76 %)	Nil (0 %)
Wound edge necrosis	3 out of 21 (14.28 %)	3 needed simple dressings (30%)
Wound infection	3 out of 21 (14.28 %)	2 simple change in antibiotics and dressings (20%)

Not a single patient in present study had a second procedure done for complications. But in present study, we used modified approach for Inguinal lymphadenectomy in patients with negative FNAC and non-palpable nodes. So, morbidity has been reduced considerably plus no second procedure required in any patient. Pathologic staging and grading is important parameter for predicting the prognosis, TNM staging was standard for staging the penile cancer, higher the stage bad is the outcome.^{32,33} Most of our patients belong to clinical stage II and III only a couple of patients belong to

stage T1b. So, timing of inguinal lymphadenectomy is an important factor for the outcome.

CONCLUSION

Present study concludes with following facts-inguinal lymphadenectomy is the best predictor of Survival and quality of life in patients with penile cancer. The ultimate determination of survival in patients presenting with penile cancer rests with the complete resection of nodal metastases. Considering the inaccuracy in clinical examination, and failure of nonsurgical means of

determining the true status of the regional lymph nodes, unavailability of Sentinel node mapping or minimally invasive dynamic sentinel node biopsy the best option for better outcome, was to offer the choice of prophylactic lymphadenectomy rather than just observe or thinking that the nodes are because of amatory reaction.

Many reports suggest that lymphadenectomy done in delayed scenario has affected the survival in patients with carcinoma penis. There is clear advantage of prophylactic lymphadenectomy, but there runs a definite risk of morbidity in node negative patients. That's why it can't be considered as gold standard in the management of carcinoma of the penis bypassing the need for identifying those with positive nodes. This has forced us to follow protocols and techniques to maximize detection and minimize morbidity. Battle for cancer penis treatment is lost or won at the level of inguinal nodes.

Funding: No funding sources

Conflict of interest: None declared

Ethical approval: The study was approved by the institutional ethics committee

REFERENCES

1. Algaba F, Horenblas S, Piva GP, Solsona E, Windahl T. EAU guidelines on penile cancer. *Eu Urol.* 2002;42(3):199-203.
2. Horenblas S. Lymphadenectomy for squamous cell carcinoma of the penis. Part 2: the role and technique of lymph node dissection. *BJU Int.* 2001;88:473-83.
3. ENCR (European network of cancer registries). Eurocim version 4.0. European incidence database V.2.2 (1999) Lyon IARC, 2001. Available at: http://www.encl.com.fr/encl_EUROCIMI.htm
4. Reddy CR, Raghavaiah NV, Mouli KC. Prevalence of carcinoma of penis with special reference to India. *Int.Surg.* 1975;60:474-6.
5. Penile cancer (Internet) 2009 (cited 2014 September 10) Available at: <http://www.indiacancersurgerysite.com/penile-cancer-treatment-india.html>.
6. Dillner J, von Krogh G, Horenblas S, Meijer CJ. Etiology of squamous cell carcinoma of penis. *Scand J Urol Nephrol.* 2000;205:189-93.
7. Ornellas AA, Seixas AL, Marota A, Wisnesky A, Campos F, de Moraes JR. Surgical treatment of invasive squamous cell cancer of penis; retrospective analysis of 350 cases. *J Urol.* 1994;151:1244-9.
8. Abi-Aad AS, De Kernion JB. Controversies in ilioinguinal lymphadenectomy for cancer of the penis. *Urol Clin North Am.* 1992;19:319-24.
9. Rangabashyam N, Gnanaprakasam D, Meyyappan P, Vijayalakshmi SR, Thiruvadanam BS. Carcinoma of penis. Review of 214 cases. *J R Coll Surg Edinb.* 1981;26:104-9.
10. Ravi R. Morbidity following groin dissection for penile cancer. *Br J Urol.* 1993;126:108-10.
11. Saisorn I, Lawrentschuk N, Leewansangtong S, Bolton DM. Fine-needle aspiration cytology predicts inguinal lymph node metastasis without antibiotic pretreatment in penile carcinoma. *BJU Int.* 2006;97:1225-8.
12. Gursel EO, Georgountzos C, Uson AC, Melicow MM, Veenema RJ. Penile cancer: clinicopathologic study of 54 cases. *J Urol.* 1973;1:569-573.
13. Ornellas AA, Seixas AL, De Moraes JR. Analysis of 200 lymphadenectomies in patients with penile carcinoma. *J Urol.* 1991;146:330-2.
14. Protzel C, Alcaraz A, Horenblas S, Pizzocaro G, Zlotta A, Hakenberg OW. Lymphadenectomy in the surgical management of Penile cancer. *Eur Urol.* 2009;55:1075-88.
15. Ravi R. Correlation between the extent of nodal involvement and survival following groin dissection for carcinoma of the penis. *BJU International.* 1993;72(5):817-9.
16. Catalona WJ. Modified inguinal lymphadenectomy for carcinoma of the penis with preservation of saphenous veins: technique and preliminary results. *J Urol.* 1988;140:306-10.
17. Bevan-Thomas R, Slaton JW, Pettaway CA. Contemporary morbidity from lymphadenectomy for penile squamous cell carcinoma: the M.D. Anderson cancer center experience. *J Urol.* 2002;167:1638-42.
18. Bouchot O, Rigaud J, Maillet F, Hetet JF, Karam G. Morbidity of inguinal lymphadenectomy for invasive penile carcinoma. *Eur Urol.* 2004;45:761-6.
19. Horenblas S, Van Tinteren H, Delemarre JF, Moonen LM, Lustig V, Van Waardenburg EW. Squamous cell carcinoma of the penis III. Treatment of regional lymph nodes. *J Urol.* 1993;149:492-7.
20. Pettaway CA, Lance RS, Davis JW. Campbell-Walsh Urol. Philadelphia: Elsevier-Saunders; Tumors of the penis In Wein AJ (editor); 2012:901-33.
21. Leijte JA, Horenblas S. Inguinal metastasis in penile cancer: diagnosis and management. *Eau-ebu Update Series.* 2007;5(4):145-52.
22. Graafland NM, Teertstra HJ, Besnard AP, van Boven HH, Horenblas S. Identification of high risk pathological node positive penile carcinoma: value of preoperative computerized tomography imaging. *J Urol.* 2011;185:881-7.
23. Tabatabaei S, Harisinghani M, McDougal WS. Regional lymph node staging using Lymphotropic nanoparticle enhanced MRI with ferumoxtran-10 in patients with penile cancer. *J Urol.* 2011;174:923-7.
24. Pandey D, Mahajan V, Kannan RR. Prognostic factors in carcinoma penis. *J Surg Oncol.* 2006;93:133-8.
25. Omellas AA, Nobrega BL, Wei Chin E. Prognostic factors in invasive squamous cell carcinoma of penis analysis of 196 patients treated at the Brazilian

- National Cancer Institute. *J Urol.* 2008;180:1354-59.
26. Protzel C, Knoedel J, Wolf E, Kleist B, Poetsch M, Giebel J. Prognostic parameters of penis carcinoma. *Der Urologe A.* 2007;46:1162.
 27. Protzel C, Kakies C, Kleist B, Poetsch M, Giebel J. Down- regulation of the metastasis suppressor protein KAI1/ CD82 correlates with occurrence of metastasis, prognosis and presence of HPV DNA in human penile squamous cell carcinoma. *Virchows Arch.* 2008;452:369-75.
 28. Schlenker B, Scher B, Tiling R, Siegert S, Hungerhuber E, Gratzke C, et al. Detection of inguinal lymph node involvement in penile squamous cell carcinoma by 18F-fleurodeoxyglucose PET/CT: a prospective single center study. *Urol Oncol.* 2012;30:55-9.
 29. Leijte JA, Kerst JM, Bais E, Antonini N, Horenblas S. Neoadjuvant chemotherapy in advanced penile carcinoma. *Eur Urol.* 2007;52:488-94.
 30. Mistry T, Jones RW, Dannatt E, Prasad KK, Stockdale AD. A 10 years retrospective audit of penile cancer management in the UK. *BJU Int.* 2007;100:1277-81.
 31. McDougal WS. Carcinoma of penis: improved survival by early regional lymphadenectomy. *J Urol.* 1995;154:1364-6.
 32. Leijte JA, Horenblas S. Shortcomings of the current TNM classification for penile carcinoma, time for change? *World J Urol.* 2009;27:151-4.
 33. Leijte JA, Hughes B, Graafland NM, Kroon BK, Olmos RA, Nieweg OE, et al. Reliability and safety of current dynamic sentinel node biopsy for squamous cell penile carcinoma. *J Clin Oncol.* 2009;27:3325-9.

Cite this article as: Nichkaode PB, Agrawal R, Kulkarni S. Cancer penis evaluation of role of prophylactic inguinal lymph nodes dissection. *Int Surg J* 2017;4:2495-501.