

Case Report

Pure mucinous (colloid) carcinoma of gall bladder: a rare entity

Gireesha Rawal, Charanjeet Ahluwalia*, Amit Kumar Yadav, Indrani Dhawan

Department of Pathology, Vardhman Mahavir Medical College and Safdarjung Hospital, New Delhi, India

Received: 27 May 2017

Accepted: 23 June 2017

*Correspondence:

Dr. Charanjeet Ahluwalia,

E-mail: charanjeet.ahluwalia@rediffmail.com

Copyright: © the author(s), publisher and licensee Medip Academy. This is an open-access article distributed under the terms of the Creative Commons Attribution Non-Commercial License, which permits unrestricted non-commercial use, distribution, and reproduction in any medium, provided the original work is properly cited.

ABSTRACT

In the biliary tract, 'mucinous' carcinomas in which extracellular mucin constitutes more than 50% of the tumour volume, are very rare. Those tumours in which the mucinous pattern comprises of at least 90% of the tumour are called 'pure mucinous' carcinomas and are exceedingly rare in the gallbladder. We describe the case of a 55 years old female, who presented with the complaints of jaundice and dull aching pain in right hypochondriac region. USG abdomen was suggestive of carcinoma along with cholelithiasis, following which cholecystectomy was performed. Grossly, a large grey-white tumour was identified whose cut surface was variegated. Sections showed a tumour which was entirely composed of pools of extracellular mucin, in which clusters of tumour cells were floating. Based on morphology and immunohistochemistry, a final diagnosis of 'pure mucinous (colloid) adenocarcinoma' of the gallbladder was given. This case is described owing to the rarity of this neoplasm. The clinical features, natural history and prognosis of mucinous carcinoma of GB are not very well known, due to their extreme rarity. These have been discussed in this case report. Histopathological examination is vital for a decisive diagnosis of such cases.

Keywords: Colloid, Gall bladder, Mucinous, Pure

INTRODUCTION

Gallbladder carcinoma is a rather uncommon malignancy. The National Cancer Registry Programme of India showed the incidence of gall bladder carcinoma in north India as 4.5 cases per 1,00,000 in males and 10.1 cases per 1,00,000 in females.¹ In the biliary tract, carcinomas with prominent stromal mucin deposition are rare, and 'mucinous' carcinomas in which extracellular mucin constitutes more than 50% of the tumour volume, are even more rare.^{2,3} Those tumours in which the mucinous pattern comprises of at least 90% of the tumour are called 'pure mucinous' ('colloid phenotype') carcinomas and are exceedingly rare in the gallbladder (GB).^{2,3} These present in middle to late age group (47 to 78 years), usually don't have a sex predilection, and clinically exhibit symptoms of acute cholecystitis.⁴ Approximately twenty cases of mucinous carcinoma of

the GB have been reported so far. We report a very rare case of pure mucinous carcinoma of the GB.

CASE REPORT

A 55 years old female presented with the complaints of jaundice for three months and dull aching pain in right hypochondriac region for 1 week. USG abdomen was done, which showed an irregularly margined hypoechoic mass in the fundus of gallbladder, thickened wall, as well as echogenic shadowing foci from gallstones, and was suggestive of carcinoma along with cholelithiasis. Cholecystectomy was performed and the specimen was received for histopathological examination. Grossly, the gall bladder was enlarged measuring 12x9x7 cm. External surface was congested and nodular (Figure1a). On cut, a large grey-white tumour was identified measuring 11.6x8.5x6.6 cm. Cut surface was

variegated showing mucoid areas along with areas of haemorrhage and necrosis. A single mixed stone was identified at the fundus (Figure 1b).

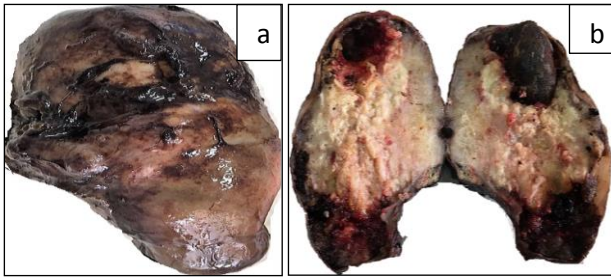


Figure 1(a): Gross specimen of mucinous carcinoma, gall bladder; 1(b): Cut section of mucinous carcinoma, gall bladder.

Haematoxylin and eosin stained section showed a tumour which was entirely composed of pools of extracellular mucin, in which clusters of tumour cells were floating. Individual tumour cells were round to oval with moderate amount of cytoplasm and large, hyperchromatic nuclei. Intracellular mucin vacuoles could be appreciated. Signet-ring cells were also present. The surrounding stroma showed extensive desmoplasia. The tumour was involving the muscle coat and was reaching upto the serosa layer of the gall bladder (Figure 2a, 2b, 2c).

Immunohistochemistry for MUC1, CK7, CK20 and CDX2 was applied. On evaluation, it was found to be positive for MUC1 and CK7, and negative for CK20 (ruling out intestinal carcinoma) and CDX2 (ruling out pancreatic mucinous carcinoma) (Figures 3a, 3b, 3c, 3d).

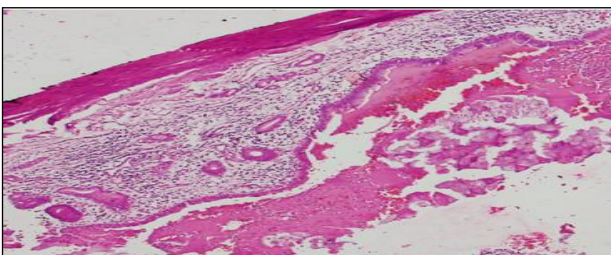


Figure 2a: Mucinous carcinoma, gall bladder (X10). Section shows wall of gall bladder with tumour arising from epithelium.

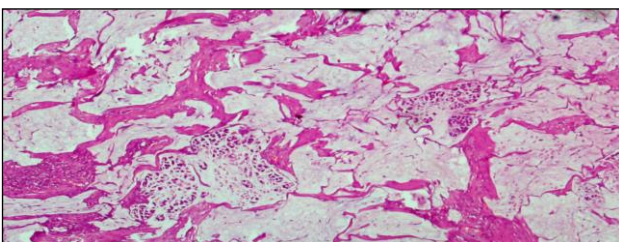


Figure 2b: Mucinous carcinoma, gall bladder (X10). Section shows tumour cells floating in pools of mucin. Desmoplastic response is also seen.

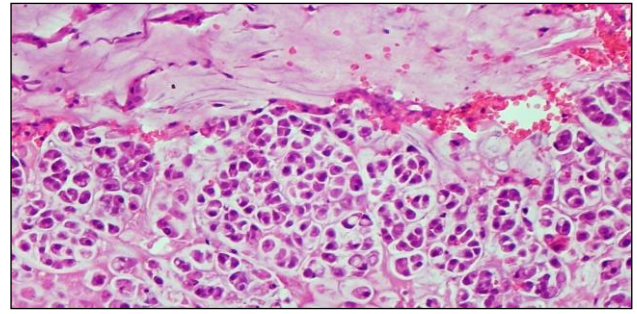


Figure 2(c): Mucinous carcinoma, gall bladder (X40). Section shows round to oval tumour cells with moderate amount of cytoplasm and large, hyperchromatic nuclei. Intracellular mucin vacuoles and signet-ring cells are present.

A final diagnosis of 'pure mucinous (colloid) adenocarcinoma' of the gallbladder was given.

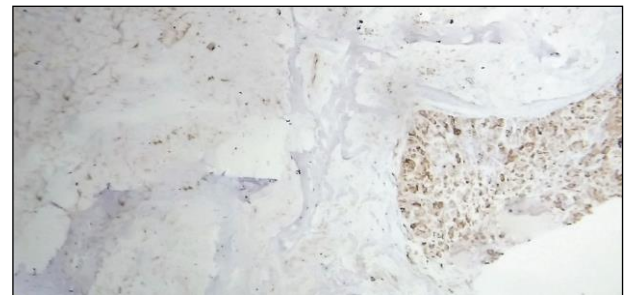

Figure 3a: Tumour cells showing positivity for Muc1 on IHC (X10).

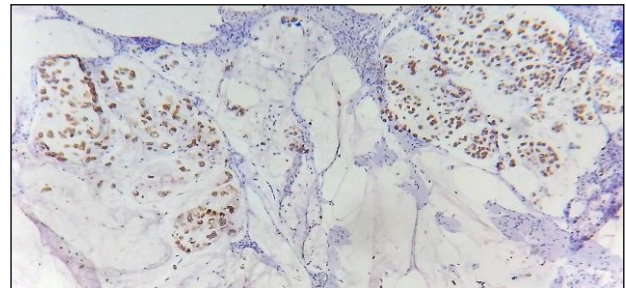


Figure 3b: Tumour cells showing positivity for CK7 on IHC (X10).

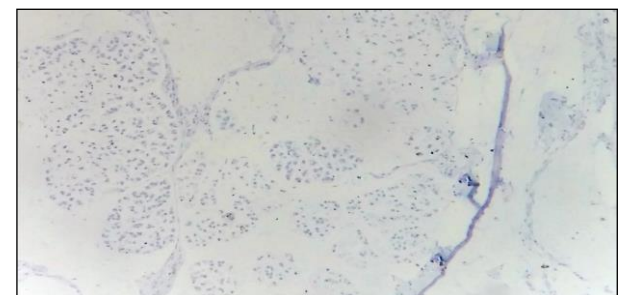


Figure 3c: Tumour cells showing negativity for CK20 on IHC (X10).

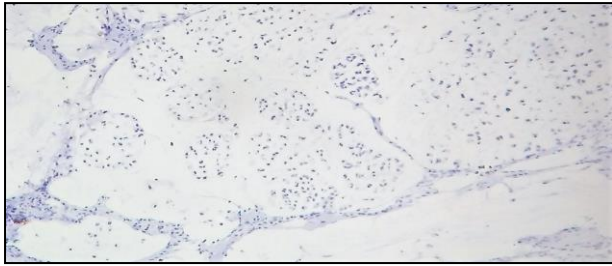


Figure 3d: Tumour cells showing negativity for CDX2 on IHC (X10).

DISCUSSION

Majority of the carcinomas of the GB are adenocarcinomas of the pancreatobiliary type while other subtypes such as papillary, clear cell and mucinous adenocarcinomas comprise the rest.^{2,3} Mucinous carcinomas are tumours in which extracellular mucin constitutes more than 50% of the tumour volume, and is seen as mucin lakes containing scant clusters of floating carcinoma cells.^{2,3} These tumours are rare in the GB and, if present, the mucinous pattern usually constitutes 50 to 90% of the tumour, with the rest of the tumour being comprised of conventional adenocarcinoma.^{2,3} 'Pure mucinous (colloid) carcinoma', i.e. tumours with 90% or more mucinous pattern, as seen in the breast, are exceedingly rare in the gallbladder.^{2,3,5} The reported incidence rate varies from 5% to 10.8%.⁶⁻⁸ About twenty cases of mucinous carcinoma of the GB have been reported so far. However, exactly how many of these had pure mucinous phenotype is unclear. The reported female to male ratio is 1.1 for mucinous carcinomas (versus 3.9 for conventional pancreatobiliary-type GB adenocarcinomas). Perineural invasion has been reported in 73% cases, however, it was not seen in the present case.⁴ In the cases showing perineural invasion, nerve bundles present in mucin pools can be identified by special stains for mucin (Alcian blue, mucicarmine), as well as IHC for mucin (Muc1) and for nerve bundles (S100). Immunophenotypically, mucinous carcinomas of gall bladder differ from intestinal carcinomas by an inverse CK7/20 profile, and from pancreatic mucinous carcinomas by CDX2 negativity (Figure 4).⁴

The risk factors, associated features, natural history and prognosis of mucinous carcinoma of GB are not very well known, owing to their extreme rarity. They are typically large and advanced tumours at the time of diagnosis, with 87% of the cases showing T3 tumours, as opposed to 48% in conventional GB adenocarcinomas, and thus exhibit more-aggressive behavior than conventional GB carcinomas.⁴

They may lead to pseudomyxoma peritonei. Giang et al, in a review of 23 GB carcinomas, discussed the potential pitfall of confusing primary mucinous adenocarcinoma of GB with pseudomyxoma peritonei from a low-grade

appendiceal neoplasm disseminated to GB, especially when only the GB is removed.⁹

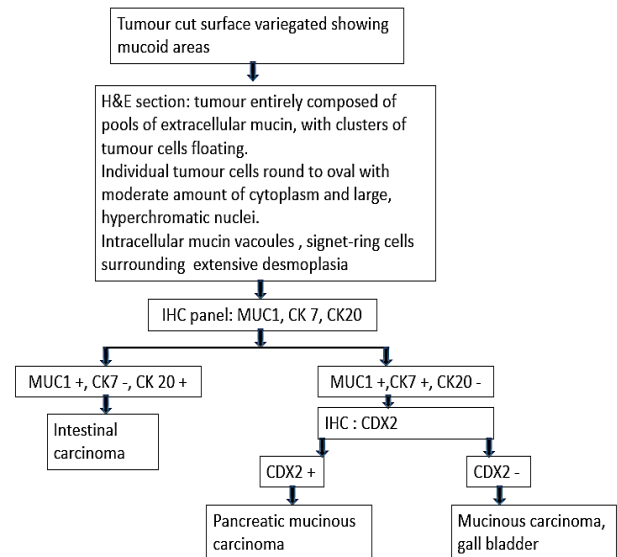


Figure 4: Approach to mucinous carcinoma, gall bladder.

CONCLUSION

Overall the survival of mucinous carcinoma is significantly worse than that of conventional adenocarcinomas. Moreover, overall survival of patients who have carcinomas with signet-ring cells appears to be worse (6 months) than for pure colloid cases and mixed mucinous ones (14 months).⁴

Funding: No funding sources

Conflict of interest: None declared

Ethical approval: Not required

REFERENCES

1. National Cancer Registry Programme, Consolidated reports of the population based cancer registries 1990-96. Indian Council of Medical Research, New Delhi, India: 2001.
2. Adsay VN, Klimstra DS. Benign and Malignant Tumours of the gallbladder and extrahepatic biliary tract. In: Odze RD, Goldblum JR, editors. Surgical pathology of the GI tract, liver, biliary tract, and pancreas. 2nd ed. Philadelphia: Saunders Elsevier. 2009;857-70.
3. Adsay VN. Gallbladder, Extrahepatic biliary tree, and ampulla. In: Mills SE, editor. Sternberg's diagnostic surgical pathology. 5th Ed. Lippincott Williams and Wilkins; 2010:1620-4.
4. Dursun N, Escalona OT, Roa JC, Basturk O, Bagci P, Cakir A, et al. Mucinous carcinomas of the gallbladder: clinicopathologic analysis of 15 cases identified in 606 carcinomas. Archives of Pathol Laboratory Med. 2012;136(11):1347-58.

5. Rosen PP, editor. Rosen's Breast Pathology. 3rd ed. Lippincott Williams and Wilkins. 2009:515-35.
6. Joo YE, Kim HS, Choi SK, Rew JS, Kim HJ, Kang HK, et al. Case of mucinous adenocarcinoma with porcelain gallbladder. *J Gastroenterol Hepatol.* 2003;18(8):995-8.
7. Shani M, Hart J, Modan B. Cancer of the biliary system: a study of 445 cases. *Br J Surg.* 1974;61:98-100.
8. Lack EL. Tumours of the gallbladder and cystic duct. In: Lack EL, ed. *Pathology of the Pancreas, Gallbladder, Extrahepatic Biliary Tract, and Ampullary Region.* New York, NY: Oxford University Press, Inc; 2003:465-511.
9. Giang TH, Ngoc TTB, Hassell LA. Carcinoma involving the gallbladder: a retrospective review of 23 cases: pitfalls in diagnosis of gallbladder carcinoma. *Diagn Pathol.* 2012;7:10.

Cite this article as: Rawal G, Ahluwalia C, Yadav AK, Dhawan I. Pure mucinous (colloid) carcinoma of gall bladder: a rare entity. *Int Surg J* 2017;4:2858-61.