

## Original Research Article

# Bladder injuries during obstetrical and gynecological surgeries

Beena Vaidya<sup>1</sup>, Manish Chaudhari<sup>1\*</sup>, Deep Parmar<sup>1</sup>, Vipul Chaudhari<sup>2</sup>,  
Taha Daginawala<sup>1</sup>, Ritesh Shah<sup>1</sup>

<sup>1</sup>Department of Surgery, Government Medical College, Surat, Gujarat, India

<sup>2</sup>Department of Community Medicine, Government Medical College, Surat, Gujarat, India

**Received:** 19 May 2017

**Accepted:** 29 May 2017

**\*Correspondence:**

Dr. Manish Chaudhari,

E-mail: [drmanishchaudhari@gmail.com](mailto:drmanishchaudhari@gmail.com)

**Copyright:** © the author(s), publisher and licensee Medip Academy. This is an open-access article distributed under the terms of the Creative Commons Attribution Non-Commercial License, which permits unrestricted non-commercial use, distribution, and reproduction in any medium, provided the original work is properly cited.

### ABSTRACT

**Background:** The reproductive and urinary tracts in women are closely related anatomically and embryologically. Knowledge of this anatomy plays an important role in the prevention of urinary tract injury during gynaecologic surgery. The primary approach to prevention is careful surgical dissection and knowledge of the position of urinary tract structures within the surgical field.

**Methods:** Prospective interventional study consisted of 28 patients with obstetrics and gynecological surgeries was carried out at department of surgery, new civil hospital, Surat during December 15<sup>th</sup> to January 16<sup>th</sup>. Out of 28 patients 13 patients had bladder injuries which repaired and studied in detail.

**Results:** Out of these 28 patients undergone various obstetrics and gynecological surgeries, 13 patients were having iatrogenic urinary bladder injuries. Bladder injury occurred commonly during in LSCS and in hysterectomies. Out of 13 urinary bladder injuries, 8 injuries repaired in 2 layers by Vicryl 2-0 without insertion of SPC and 5 injuries were managed by primary repair with vicryl 2-0 with insertion of SPC (SPC= suprapubic cystostomy).

**Conclusions:** Surgery adjacent to or within urinary bladder continue to result in occasional iatrogenic injury. These injuries can be minor with no long-term sequelae, or they can result in significant morbidity and inconvenience to patients.

**Keywords:** Bladder injuries, Obstetrical and gynaecological surgeries

### INTRODUCTION

The close embryologic development and anatomic proximity of the urinary and genital organs, predisposes the urinary tract to injury during surgical procedures in the female pelvis.<sup>1</sup> Injury to urinary tract in medical practice was first described on 1030 AD in the opus called "Al-Kanoun".<sup>2</sup> Injuries to urinary bladder and ureter are not uncommon complication after obstetric or gynecological surgeries.<sup>3-5</sup>

In gynecologic surgery, bladder injury most commonly occurs during abdominal hysterectomy. Bladder injury is

noted at this time, it usually can be easily managed by a two- or three-layer closure with absorbable suture and Foley catheter bladder drainage. Retrograde bladder filling with blue-colored saline again makes bladder injury diagnosis easier.<sup>6</sup> Many obstetricians and gynecologists share a common fear of injury to the ureter.<sup>7</sup>

Traditionally, gynecological procedures have been reported to account for between 50 and 75% of iatrogenic ureteric injuries since the ureter lies very near the female reproductive organs throughout its course from the pelvic brim to the bladder.<sup>8-10</sup>

During the operation, the diagnosis of bladder injury is suggested by the presence of gas filling up the Foley bag or visibly bloody urine in the Foley bag. Other signs of injury are urinary/fluid drainage from a secondary trocar site incision, or fluid pooling in the abdomen/pelvis. If a bladder injury is suspected, the bladder should be filled with methylene blue-colored saline. The forcing out of fluid/dye indicates a bladder injury inside the abdominal membrane. If there is no fluid forced out and a bladder injury outside the abdominal membrane is suspected, a cystogram (X-ray of the bladder after injection of contrast medium) should be performed. Injuries outside the abdominal membrane are managed conservatively through prolonged Foley drainage. Delayed diagnosis of bladder injury also is done by cystography. Irritation of the abdominal membrane that persists more 12 hours after laparoscopy also should raise suspicion of an undiagnosed bladder injury.<sup>11-13</sup>

Veress needle injuries and other small injuries to the bladder can be successfully managed conservatively by catheter drainage for seven to 14 days followed by cystography. Large bladder injuries, such as from 5 or 10 mm trocar or surgical dissection, often require suturing the injuries closed (either laparoscopically or by open repair) and prolonged catheter drainage. A bladder injury recognized by laser or electrocautery should be closely evaluated and typically managed with catheter drainage for five to 10 days. Sharp dissection, electrocautery and laser bladder injuries also have been reported during laparoscopic-assisted vaginal hysterectomy, adnexectomy (removal of one of the uterine tubes and an ovary), diagnostic laparoscopy and endometriosis surgery.<sup>11,12</sup>

## METHODS

*Study Design:* Prospective interventional study

*Sample Size:* With Convenient sampling method 13 patients with bladder injuries repaired and studied in detail out of 28 patients at Department of Surgery, New Civil Hospital, Surat during December-15<sup>th</sup> to January-16<sup>th</sup>. Obstetrics and gynaecological surgeries

### Diagnosis/staging

Iatrogenic injuries to the bladder are staged as;<sup>14</sup>

- Grade 1: contusion, intramural hematoma or partial thickness laceration
- Grade 2: extraperitoneal bladder wall laceration <2 cm
- Grade 3: extraperitoneal >2 cm or intraperitoneal <2 cm
- Grade 4: intraperitoneal bladder wall laceration >2 cm
- Grade 5: intra- or extraperitoneal bladder wall laceration involving the trigone or bladder neck.

Injuries to the bladder can present in a delayed fashion or at the time of surgery. Risk factors for bladder injury include previous operations, radiation, malignant infiltration, chronic infection, and inflammation. Intraoperative identification allows for immediate repair (cystorrhaphy). An unrecognized bladder injury will usually present clinically in the early postoperative period. Signs and symptoms can include drainage from a surgical incision, increased output from surgical drains, vaginal leakage, ileus, apparent oliguria, and urinary ascites with elevated BUN and serum creatinine due to reabsorption. Diagnosis can be made radiographically by a CT cystogram or fluoroscopic cystogram. Passive filling of the bladder with opacification from filtered contrast from the kidneys is not sufficient to diagnose a bladder injury and is not a true CT cystogram. A CT cystogram is performed with retrograde contrast instillation (through a Foley catheter) of 200 to 300 cc of water-soluble contrast prior to the exam. The Foley is clamped during the scan. Extraperitoneal injuries are identified by contrast extravasation being confined to the lateral pelvic side walls or within the space of Retzius.

The development of a Colovesical or enterovesical fistula is a delayed complication of cystotomy. An abdominal-pelvic CT scan with oral and rectal water-soluble contrast has a greater sensitivity than cystoscopy in accurately diagnosing and staging an enterovesical/colovesical fistula.<sup>15</sup> Although not used for staging, the poppy seed test is the most sensitive and specific for diagnosis of a fistula.<sup>6</sup>

All injuries recognized intraoperatively should be repaired. For small extraperitoneal injuries (grade 2) without complicating factors, treatment is a Foley catheter for 7 to 14 days. Late presentation of grade 3 to grade 5 injuries require operative repair. Closed suction drains should be left in place after repairs. Suprapubic tube placement is not necessary in most cases.

For injuries to the ventral bladder, dome, or posterior bladder away from the ureteral orifices, the mucosa is closed in a running fashion using 3-0 vicryl followed by a seromuscular running suture of 2-0 vicryl. The bladder can then be irrigated to ensure a watertight closure. A third layer in a Lembert fashion can be used in cases at high risk for fistula formation or when a leak is identified. In the laparoscopic setting, a one-layer closure is performed using 2-0 vicryl to close all layers of the bladder. An additional layer can then be added using a 2-0 vicryl in a Lembert fashion for more extensive injuries.

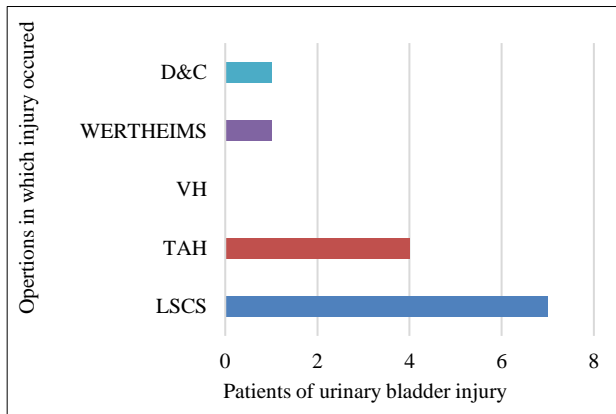
*Data Collection methods:* The pretested, semi-structured questionnaire was used for data collection.

*Data Management and Analysis:* After the completion of data collection, data entry and analysis was done by Excel 3.0.

## RESULTS

Out of 28 patients 13 patients were having Urinary bladder injuries. Due to its relation to Uterus in proximity, it is most commonly injured in LSCS (Lower Segment Caesarian Section) and in hysterectomies.

In patients who had previous history of LSCS have more chances of Urinary bladder injuries because of severe adhesions (Figure 1).

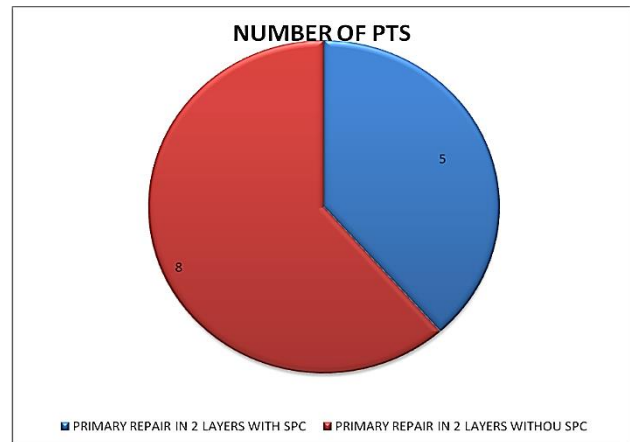


**Figure 1: Distribution of urinary bladder injuries during different surgeries.**

Out of 13 urinary bladder injuries, 7 injuries were only 1\*1 cm sized rent detected over POSTEROSUPERIOR SURFACE of urinary bladder. 5 injuries were > 1 cm in length, out of which 3 injuries were Vertical in manner in posterosuperior surface, and 2 injuries were of transverse tear in posterosuperior surface. 1 injury detected in late post-operative period by urinary leak per vaginum, on investigating the patient it was found that patient was having vesico uterine fistula. Posterosuperior surface is most commonly injured due to its relation to Uterus. Urinary bladder injured either during Adhesiolysis in Hysterectomy, during Incision over Uterus in LSCS or during suturing of uterine edges sometimes urinary bladder stitched along with the uterus. No bladder injuries reached up to Trigon, and No injuries in bladder involve Ureters. Out of 13 urinary bladder injuries 9 were detected Intra operatively due to urinary leak and 4 were detected in Post-operative period due to Hematuria, abdominal distension and complain of Fever because of Urinary leak in peritoneum and pyoperitoneum formation.

Out of 13 urinary bladder injuries, 8 injuries repaired in 2 layers by Vicryl 2-0 without insertion of SPC whereas 5 injuries were managed by primary repair with vicryl 2-0 with insertion of SPC (SPC= suprapubic cystostomy). All patients were monitored in post-operative period for vitals, urine output and stitch sites of wounds. In 12 patients Foleys catheter and SPC catheter removed after 14 days of operation and no complication found postoperatively and they were discharged after 15 days of

operation. 1 mortality detected in 1st 6 hours. of post op period because patient was referred from private hospital for post-partum hemorrhage, and patient as in poor general condition and hemodynamically instability of patient.



**Figure 2: Management of urinary bladder injuries.**

## DISCUSSION

Out of total bladder injury, (53.8%) patients had injury occurred during LSCS followed by trans abdominal hysterectomy (TAH) (30.8%), wertheims (7.7%) and dilatation and curettage (D and C) (7.7%). The frequency of bladder injury was higher in abdominal hysterectomy (AH) being 2.4%<sup>1</sup> as compared to 0.5%<sup>16</sup> in Vaginal Hysterectomy (VH). Close anatomic association of genital and urinary organ, predisposes the urinary tract to injury, during pelvic surgery.<sup>1</sup> The most important surgical tool for surgeon is his / her knowledge and understanding of the anatomy in which he operates.<sup>17</sup> Bladder injury appears to be the most prominent urological complication in our review. It occurs most commonly during the incision in to the utero-vesical space to dissect bladder caudally. It is conceivably so because of the increased scarring that may occur between the bladder base and pubovesical fascia.<sup>18</sup>

Out of 13 urinary bladder injuries 9 were detected Intra operatively due to URINARY leak and 4 were detected in Post-operative period. Out of 13 urinary bladder injuries, 8 injuries repaired in 2 layers by Vicryl 2-0 without insertion of SPC whereas 5 injuries were managed by primary repair with vicryl 2-0 with insertion of SPC (SPC= suprapubic cystostomy). There is general agreement that when inadvertent injury to the bladder was detected during surgery, immediate on table repair is the optional treatment.<sup>19</sup> Intraoperative corrections carry less morbidity and provide better quality of life.<sup>20</sup>

## CONCLUSION

High incidence of organ injury suggest that one should be very careful while doing any major pelvic surgery and counseling and informed consent are essential. Rate of

complication can be reduced by good knowledge of anatomy of Genitourinary Tract, being careful while doing dissection during surgeries and maintenance of asepsis, early detection of complication and better post-operative care. Patients who had undergone previous caesarian sections and other Laparotomies are more vulnerable to Iatrogenic injuries. High index of suspicion required in those patients operated previously.

If iatrogenic injuries detected intraoperative then it will be managed better in comparison to if detected in late period. Surgery adjacent to or within the urinary bladder and will continue to result in occasional iatrogenic injury. These injuries can be minor with no long-term sequelae, or they can result in significant morbidity and inconvenience to patients.

Patients require adequate preoperative counselling about the potential risk of these injuries and its consequences. Due caution must be exercised while doing pelvic anatomy in open or laparoscopic surgery.

*Funding: No funding sources*

*Conflict of interest: None declared*

*Ethical approval: The study was approved by the institutional ethics committee*

## REFERENCES

- Raut V, Shrivastava A, Nandanwar S, Bhattacharya M. Urological injuries during obstetric and gynecological surgical procedures. J Postgrad Med. 1991;37:21-3.
- Kremling H. Labor-induced bladder injuries: historical observation. Gynakol Geburtshilfliche Rundsch. 1996;36(4):197-200.
- El-Tabey NA, Ali-El-Dein B, Shaaban AA, El-Kappany HA, Mokhtar AA, El-Azab M, et al. Urological trauma after gynecological and obstetric surgeries: an 18-year single-center experience. Scand J Urol Nephrol. 2006;40(3):225-31.
- Dark MJ, Nobbe JG. Ureteric trauma in gynaecological surgery. Int Uro-Gynecol J Pelvic Floor Dysfunction. 1998;9:108.
- Badenoch DF, Tiptaft RC, Thakar DR, Fowler CG, Blandy JP. Early repair of accidental injury to the ureter or bladder following gynaecological surgery. Br J Urol. 1987;59(6):516-8.
- Ricardo Azziz, Geoffrey W. Cundiff, Robert E Bristow. Linde's Atlas of Gynecologic Surgery. Lippincott Williams and Wilkins. 64 ed.2014.
- Jha S, Coomasamy A, Chan KK. Ureteric injury in obstetric and gynaecological surgery. Obstetrician Gynecologist. 2004;6(4):203-8.
- Liapis A, Bakas P, Giannopoulos V, Creatsas G, Ureteral Injuries during gynaecological surgery. Int Urogynecol J. 2001;12:391-4.
- Prober R. Surgical atlas, surgical anatomy of the ureter. BJU Int. 2007;100:949-65.
- Tijani KH, Onwuzurigo KI, Ojewola RW, Afolabi BB, Akanmu NO. Iatrogenic ureteric injuries in a Nigerian teaching hospital: experience in the last decade. East Afr Med J. 2011;88:304-9.
- Mann WJ, Arato M, Patsner B, Stone ML. Ureteral injuries in an obstetrics and gynecology training program: etiology and management. Obstet Gynecol. 1988;72:82-5.
- Goodno JA, Powers TW, Harris VD. Ureteral injury in gynecologic surgery: a ten-year review in a community hospital. Am J Obstet Gynecol. 1995;172(6):1817-20. discussion 1820-1822
- Brooks JD. Campbell-Walsh Urology. In: Wein AJ, Kavoussi LR, Novick AC, Partin AW, Peters CA, editor. 9th ed, vol. 1. Philadelphia: Elsevier. Anatomy of the lower urinary tract and male genitalia. 2007:53-60.
- Van Goor H. Consequences and complications of peritoneal adhesions. Colorectal Dis. 2007;9(s2):25-34.
- Wiskind AK, Thompson JD. Should cystoscopy be performed at every gynecologic operation to diagnose unsuspected ureteral injury? J Pelvic Surg. 1995;1:134-7.
- Purandare CN. Urological injuries in gynaecology. Obstet Gynecol India. 2007;57:203-4.
- Francis SL, Magrina JF, Novicki DE, Cornella JL. Intraoperative injuries of the urinary tract. CME J Gynecol Oncol. 2002;7:65-77.
- Siow A, Nikam YA, Ng C, Su BM. Urological complications of laparoscopic hysterectomy: a four-year review at KK Women's and Children's Hospital, Singapore. Med J. 2007;48(3):217-21.
- Eilber KS, Kavalier E, Rodriguez LV, Rosenblum N, Raz S. Ten-year experience with transvaginal vesicovaginal fistula repair using tissue interposition. J Urol. 2003;169(3):1033-6.
- Turk SK, Muneer L, Memon AS. Treatment of Gynecological and obstetric ureteric injuries. J surg Pakistan Int. 1999;4:31-4.
- Yousef SM, kama EBH, Ibrahim HBH. Ureteric injuries during obstetric and gynecologic procedures. Saudi Med J. 2003;24(04):365-8.

**Cite this article as:** Vaidya B, Chaudhari M, Parmar D, Chaudhari V, Dagainawala T, Shah R. Bladder injuries during obstetrical and gynecological surgeries. Int Surg J 2017;4:2177-80.