

## Original Research Article

# Primary intrathoracic goiter: a rare mediastinal tumor

Hazem Zribi<sup>1</sup>, Amina Abdelkbir<sup>1\*</sup>, Sarra Maazaoui<sup>2</sup>, Imen Bouacida<sup>1</sup>,  
Hanen Smadhi<sup>3</sup>, Tahar Mestiri<sup>4</sup>, Adel Marghli<sup>1</sup>

<sup>1</sup>Department of Thoracic and Cardiovascular Surgery, Abderrahmene Mami University Hospital, Ariana, Tunisia

<sup>2</sup>Department of Pneumology, Charles Nicolle University Hospital, Tunis, Tunisia

<sup>3</sup>Department of Pneumology, Abderrahmene Mami University Hospital, Ariana, Tunisia

<sup>4</sup>Department of Anesthesia, Abderrahmene Mami University Hospital, Ariana, Tunisia

**Received:** 11 April 2017

**Accepted:** 08 May 2017

### \*Correspondence:

Dr. Amina Abdelkbir,

E-mail: [aminaabdelkbir@gmail.com](mailto:aminaabdelkbir@gmail.com)

**Copyright:** © the author(s), publisher and licensee Medip Academy. This is an open-access article distributed under the terms of the Creative Commons Attribution Non-Commercial License, which permits unrestricted non-commercial use, distribution, and reproduction in any medium, provided the original work is properly cited.

## ABSTRACT

**Background:** Substernal goiters are usually classified as secondary or primary intrathoracic goiters. Primary ones result from an abnormal embryologic migration of the thyroid and represents less than 1% of all goiters. Secondary substernal goiters develop from the descent of the thyroid into the mediastinum and represents 98-99% of goiters.

**Methods:** This was a retrospective study which discuss the symptoms, the diagnosis and the treatment of 7 primary intrathoracic goiters.

**Results:** Goiter was located in the anterior mediastinum in 5 cases, in the posterior mediastinum in 1 case and in the medium mediastinum in 1 case. The mass was located on the right in 5 cases cervical approach was performed in 3 cases. Two patients required a transthoracic approach, 1 required sternotomy and in 1 case video-thoracic surgery was sufficient. Only one patient had postoperative complication which was secondary pneumothorax. All tumors were benign.

**Conclusions:** Mediastinal ectopic goitre is rare. However it should be discussed among the different etiologies of mediastinal masses.

**Keywords:** Ectopic, Mediastinal tumor, Mediastinum, Surgery, Thoracic, Thoracoscopy

## INTRODUCTION

Ectopic thyroid neoplasms are uncommon tumors and rarely suspected. They may be found anywhere along the line of the obliterated thyroglossal duct (from the base of the tongue to the level of the diaphragm). Mediastinal location is rare. Primary ectopic goiters account for approximately 6% of mediastinal masses and less than 1% of all goiters.<sup>1,2</sup> It is defined by the presence of a thyroid tissue in mediastinal seat with its own vascularization, without anatomical connection with the cervical gland and which is not the metastasis of a thyroid cancer. They present both a diagnostic and treatment challenge. The circumstance of discovery varies

according to its local evolution in the mediastinum.<sup>1-3</sup> Primary intrathoracic goiters (PIG) are commonly asymptomatic. However, they may cause compression on the surrounding structures.

In present study we performed a retrospective analysis of patients who underwent surgical treatment for PIG, analyzing clinical and pathologic features, and addressing anatomical distribution, diagnosis and treatment.

## METHODS

Patients were identified through a database search of surgical cases treated between January 2000 and

December 2016 for intrathoracic goiter. We observed and treated 122 patients with intrathoracic goiter in which 7 had PIG. Preoperative variables such as age, sex, comorbidities and the presence of a malignant disease.

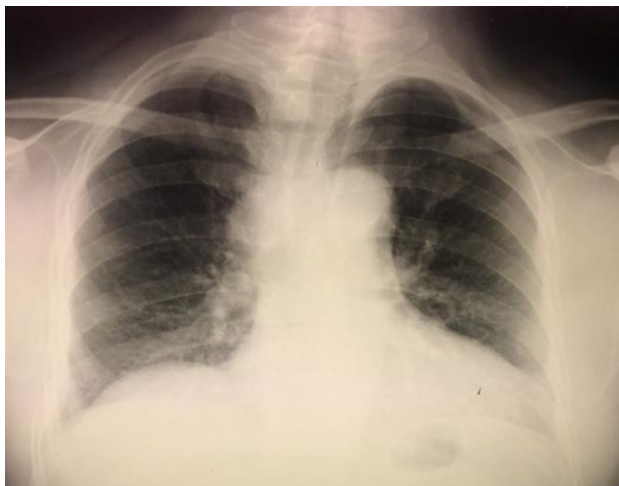
Clinical and instrumental evaluation consisted of:

- Chest X-ray
- Computer tomography (CT) or magnetic resonance imaging (MRI)
- Scintigraphy.

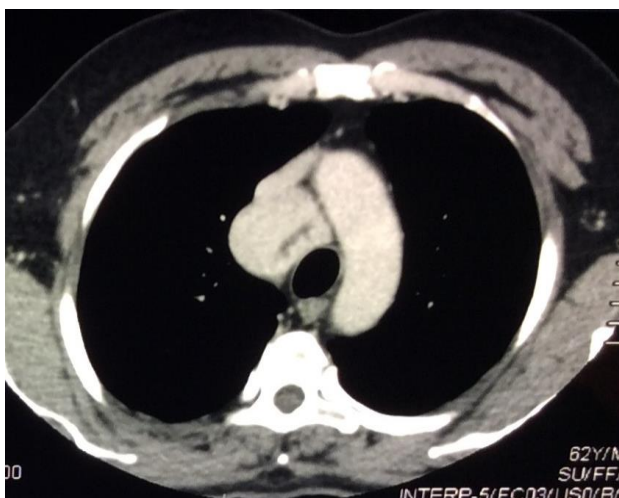
We also recorded surgical techniques, intraoperative findings and postoperative course.

## RESULTS

During the study period, we identified 122 cases of intrathoracic goiters of whom 7 patients (5.7%) had PIG with different locations.

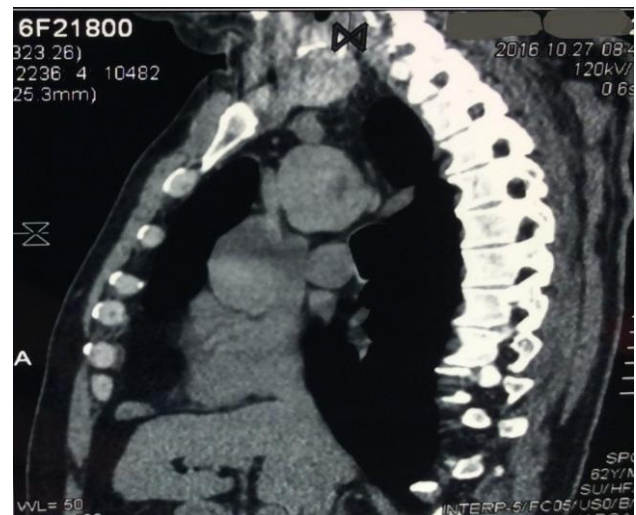


**Figure 1: Chest X-ray showing enlargement in medium mediastinum.**



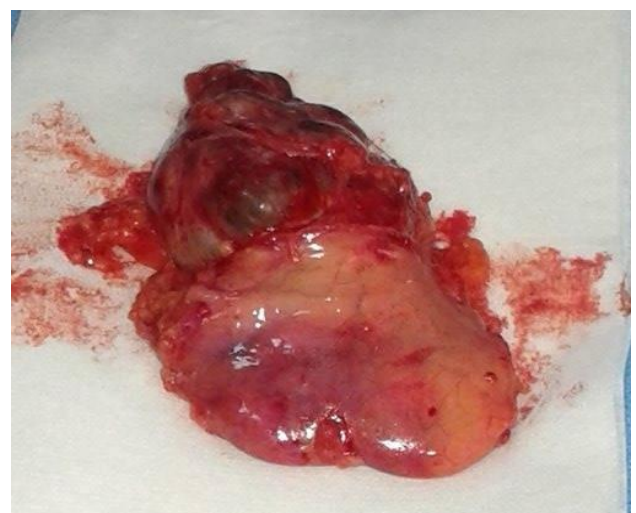**Figure 2: Computed tomography scan of thorax showing mediastinal mass in an axial section.**

The mean age was 48.5 years and 6 were female. Two patients had a history of previous thyroid surgery. The main symptoms were mainly due to compression such as dyspnea, cough for 4 patients and dysphagia for 3 patients. Mediastinal masses were investigated by neck and CT scan, MRI, and thyroid scintigraphy. The diagnosis was confirmed by histological examination (Figures 1, 2 and 3). Goiter was located in the anterior mediastinum in 5 cases, in the posterior mediastinum in 1 case and in the medium mediastinum in 1 case. All patients had a euthyroid preoperative status. The PIG was located on the right in 5 cases and on the left in 2 cases.



**Figure 3: Computed tomography scan of thorax showing mediastinal mass in a coronal section.**

The cervical approach was sufficient in 3 cases. Two patients required a transthoracic approach. Sternotomy was necessary in 1 case and video-thoracic surgery for 1 patient. Excision of the ectopic mass was combined with total thyroidectomy in 3 cases (Figure 4).



**Figure 4: Macroscopic view of an excised ectopic goiter.**

Postoperative negative pressure drainage was used and the mean hospital stay was 5 days. There was no mortality. Only one patient had postoperative complication which was secondary pneumothorax. All tumors were benign.

## DISCUSSION

The formation of the thyroid gland begins during the fourth week of the embryonic life at the tongue. It migrates at the seventh week to its normal position in front of the trachea. This is why the Lingual thyroid is the most common of the ectopic goiters (90%).<sup>3</sup> However, other ectopic localizations of the thyroid gland can be found such as lateral-cervical position, at the level of the pharynx, the larynx, the trachea, the esophagus, around the aorta.<sup>4,5</sup>

Mediastinal location is rare with an incidence of less than 1%.<sup>3</sup> This location is explained by the connection between thyroid and pericardium during embryonic life. Thyroid will later be attracted downwards with the descent of the heart into the caudal part.<sup>2</sup> Development is often done in the anterior mediastinum in 75% to 94%, it is done in the posterior mediastinum in 10% to 15% and it is done more on the right side than on the left side.

PIG has no connections with the thyroid and its blood supply come from local mediastinal vessels such as the innominate arteries or the intrathoracic aorta and internal mammary.<sup>4</sup>

PIG is seen mostly in women with (sex ratio = 1/4).<sup>4</sup> It can manifest itself at any age. In most cases, the age of discovery is during the childhood, the adolescence and around menopause because at these periods the use of thyroid hormones by the body increases and causes the production of TSH resulting in an increase in the volume of the ectopic thyroid.<sup>5,6</sup>

The ectopic thyroid may coexist with a normal thyroid gland.<sup>7</sup> Clinical and biological euthyroidism is the rule in the majority of patients with ectopic goiter but clinical cases of hyperthyroidism are reported in the literature.<sup>4</sup> Ectopic goiters remain asymptomatic for a long period. At diagnosis, more than half of them are symptomatic.<sup>3</sup>

The clinical manifestations are not specific. They are especially due to compression on the surrounding structures such as dysphagia, dyspnea, an upper vena cava syndrome.<sup>8</sup> A chest pain (71%) may be present in case of nerve compression which can also be responsible for a paresis or paralysis of the vocal cord, or a syndrome of Claude Bernard-Horner.<sup>5</sup>

In present study, dyspnea and dysphagia were the major symptoms. Chest X-ray may show a mediastinal opacity, the CT scan remains the exam of choice in the diagnosis. It has a sensitivity of 100% for Michel and all, showing a regular and heterogeneous mass.<sup>6</sup> Magnetic resonance

imaging gives a fine morphological study of goiter and its relationships. The superiority of MRI on CT was suggested by Janati et al in aberrant mediastinal goiter, and vascular component goiters.<sup>5</sup> Scintigraphy can help in diagnosis, showing intrathoracic mass with no connection with the cervical thyroid.<sup>2</sup> Once the diagnosis of ectopic goiter has been made or before the diagnosis is uncertain, surgery should be considered because of the risk of organ compression and the risk of malignancy.<sup>2,4,9,10</sup>

The approach depends on the localization of goiter. PIG generally requires resection by median sternotomy or thoracotomy. Cervicotomy is doomed to failure and is dangerous due to thoracic vascularization.<sup>2</sup> It would risk uncontrollable bleeding. It may be use when goiter is located in superior mediastinum. Preoperative differentiation between PIG and secondary goiters is important and determines the adequate approach.<sup>2</sup>

The histological structure of the thyroid glands in PIG is identical to that of normal thyroids. Thus, all pathologies that may affect a normal thyroid gland can be found on the ectopic gland such as adenoma, hyperplasia, nodules and malignant tumors.<sup>4</sup> The risk of malignancy does not exceed that of cervical goiters and is of the order of 3-20% according to the authors.<sup>2,4,5,9</sup> In present study, all tumors were benign. The malignant transformation of PIG is rare, accounting for about 15% of cases.<sup>5,6</sup>

## CONCLUSION

The mediastinal location of ectopic goiter is rare and can coexist with a normal thyroid gland and have the same pathological changes of an eutopic thyroid gland. Surgery should be considered and the approach depends on the localization.

*Funding: No funding sources*

*Conflict of interest: None declared*

*Ethical approval: The study was approved by the institutional ethics committee*

## REFERENCES

1. Grondin SC, Buenaventura P, Luketich JD. Thoracoscopic resection of an ectopic intrathoracic goiter. *Ann Thorac Surg.* 2001;71(5):1697-8.
2. Bodner J, Lottersberger CA, Kirchmayr W, Schmid T. Ectopic mediastinal thyroid adenoma. *Eur J Cardio-Thorac Surg.* 2004;26(1):211-2.
3. Hajhosseini B, Montazeri V, Hajhosseini L, Nezami N, Beygui RE. Mediastinal goiter: a comprehensive study of 60 consecutive cases with special emphasis on identifying predictors of malignancy and sternotomy. *Am J Surg.* 2012;203(4):442-7.
4. Kumar S, Sultania M, Vatsal S, Sharma MC. Primary ectopic mediastinal goiter in a patient with crohn's disease presenting as myasthenia gravis. *Ann Thorac Surg.* 2015;100(6):2333-6.

5. Santangelo G, Pellino G, De Falco N, Colella G, D'Amato S, Maglione MG, et al. Prevalence, diagnosis and management of ectopic thyroid glands. *Int J Surg.* 2016;28(1):S1-6.
6. Fenane H, Bouchikh M, el Maldi M, Lamboni D, Achir A, Ouchen F, et al. A rare cause of mediastinal cyst. *Pan Afr Med J.* 2014;19:24.
7. Noussios G, Anagnostis P, Goulis DG, Lappas D, Natsis K. Ectopic thyroid tissue: anatomical, clinical, and surgical implications of a rare entity. *Eur J Endocrinol.* 2011;165(3):375-82.
8. Batsakis G, El-Naggar AK, Luna MA. Thyroid gland ectopias. *Am Otol Rhinol Laryngol.* 1996;105:996-1000.
9. Gamblin TC, Jennings GR, Christie DB III, Thompson WM Jr, Dalton ML. Ectopic thyroid. *Ann Thorac Surg.* 2003;75:1952-3.
10. Collins HD. III. Retrosternal accessory thyroid tumor: report of a case requiring removal, terminating fatally. *Ann Surg.* 1905;41:661-6.

**Cite this article as:** Zribi H, Abdelkbir A, Maazaoui S, Bouacida I, Smadhi H, Mestiri T, et al. Primary intrathoracic goiter: a rare mediastinal tumor. *Int Surg J* 2017;4:1833-6.