

Original Research Article

Corrosive injury of upper gastrointestinal tract and its outcome

Uday Shankar Baluni^{1*}, Tejas Mistry², Ankur Kothari², Tejas Patel²

¹Department of Surgery, Government Doon Medical College and Hospital, Dehradun, Uttarakhand, India

²Department of Surgery, Baroda Medical College, Vadodara, Gujarat, India

Received: 05 April 2017

Accepted: 08 April 2017

*Correspondence:

Dr. Uday Shankar Baluni,

E-mail: udaybaluniuki@gmail.com

Copyright: © the author(s), publisher and licensee Medip Academy. This is an open-access article distributed under the terms of the Creative Commons Attribution Non-Commercial License, which permits unrestricted non-commercial use, distribution, and reproduction in any medium, provided the original work is properly cited.

ABSTRACT

Background: Corrosive gastrointestinal tract injuries are a source of considerable morbidity all over the world and differ in their presentations.

Methods: In the present work, study was done on 41 patients with history of acute corrosive injury with a period of 24 hours of ingestion and analysis on the parameters of age, sex, mode of ingestion, nature of corrosive, clinical symptoms. Further UGI scopy was also done within 24 to 48 hours of admissions.

Results: With the study it was found that, the incidence of corrosive ingestion was reducing as the age was increasing and among all patients 27 were females and only 14 were males. The most common cause of corrosive ingestion was suicidal found in 30 cases and only 11 were accidental and most common nature of corrosive used was acid. 2 patients get expired during the initial resuscitation. On GI scopy, 18 have grade 1, 12 have grade 0, 4 have grade 2 and 7 have grade 3 according to Zargar classification. Initially 35 patients were given conservative treatment and 4 cases were treated surgically by feeding jejunostomy. On follow up 31 were advised for conservative management and 7 required surgical management, out of which esophageal dilatation was done in 2 cases, esophagectomy in 2 cases and gastrojejunostomy was done in cases and one case get expired.

Conclusions: Corrosive ingestion patient are managed on the basis of UGI scopic grading.

Keywords: Corrosive ingestion, Management, UGI scopy, Zargar classification

INTRODUCTION

Ingestion of corrosive substances is increasingly reported in our country due to lack of education and prevention. It is an important cause of morbidity and mortality in our country, where significant proportion of ingestions are suicidal. The word 'corrosive' is derived from the Latin verb *corrodere*, which means 'to gnaw away', indicating how these substances seem to 'gnaw' their way through flesh or other material.

Corrosive injuries to the upper gastrointestinal tract are a serious issue in India, where the corrosive substances are easily obtainable to common people including

adolescents. These substances are consumed usually in the form of toilet cleaning agents, soaps, bleaches, etc. Corrosive injury of the oesophagus and stomach is a cause of major morbidity and is usually seen in the younger age group. Full thickness esophagogastric necrosis is a severe form of injury associated with substantial morbidity and mortality. It may occur owed to ingestion of a large amount or highly concentrated corrosive substance.¹ The severity of the subsequent damage depends essentially on the corrosive properties and the concentration of the ingested agent.² These injuries occur as a result of accidental ingestion as in adolescents or because of suicidal or homicidal intentions and under the influence of alcohol or drugs in case of adults.³

There are various clinical manifestations including acute, short term and long term complications. They are depending on multiple factor such as type of agents, its concentration, quantity and physical state, duration of exposure.⁴ According to these clinical pictures management of corrosive injury is multimodal. Thus, it is important to evaluate patient in emergency room, and assign patient to suitable mode of management.

Corrosive ingestion is major public health concern In India. There is poor data collection of corrosive injury case and their outcome.

In this context, we planned this prospective study to find the incidence of corrosive ingestion in patients at tertiary health care centre and to ascertain the morbidity and mortality in such cases of corrosive ingestion and observe sequel for period of 6 months.

METHODS

Forty one patients with history of acute corrosive injury who presented to emergency room within a period of 24 hours of ingestion were included in this prospective observational and analytic study. Corrosive details that were recorded include the nature of corrosive, intent suicidal or accidental, demographic data, clinical presentations. After initial clinical evaluation patients was admitted and undergone upper GI endoscopy within 24 hours of admission to assess the degree and extent of injury in stable patients and severity was graded based on Zagars's classification.⁵ Patients were in follow up for periods 6 months and managed according to their clinical presentations conservatively or different surgical modality of treatment. Statically analysis was done using computer software (SPSS version 20).

RESULTS

The mean age was 26.24 ± 3.12 years. The mean age of male cases was slightly higher than the female cases. The mean age of females was 24 ± 7.58 years while that of males was 30.5 ± 13.9 years.

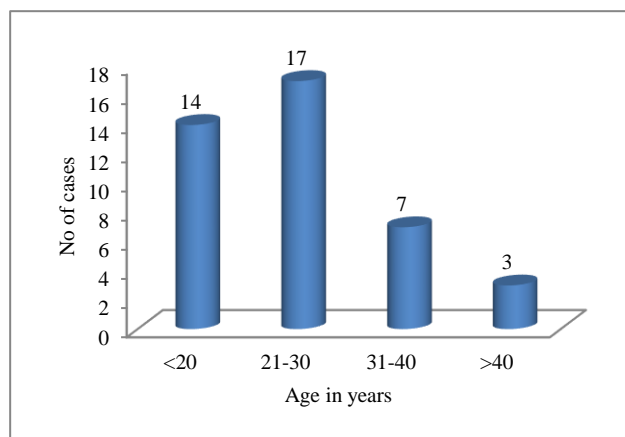


Figure 1: Age distribution of corrosive ingestion.

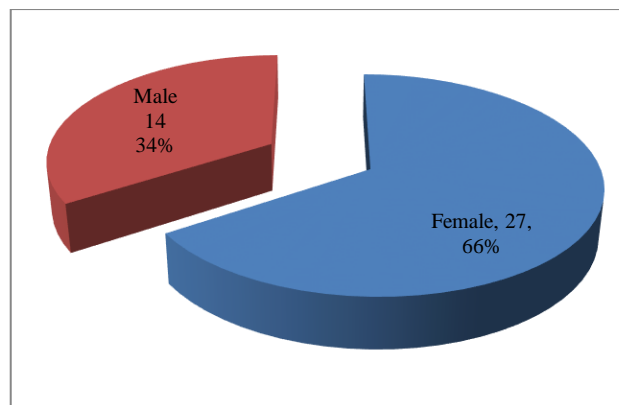


Figure 2: Sex distribution of corrosive ingestion.

Out of total 41 cases majority were females- 27 (65.9%) and only 14 (34.1%) were males, the male: female ratio was 1:1.9.

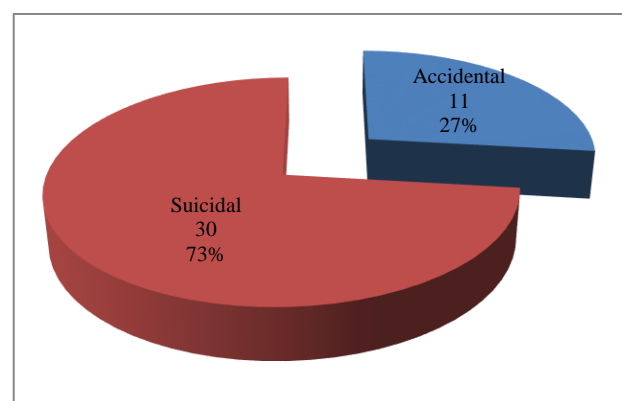


Figure 3: Mode of ingestion.

The most common cause of corrosive ingestion was suicidal found in 30 (73.2%) cases and only 11 (26.8%) were accidental.

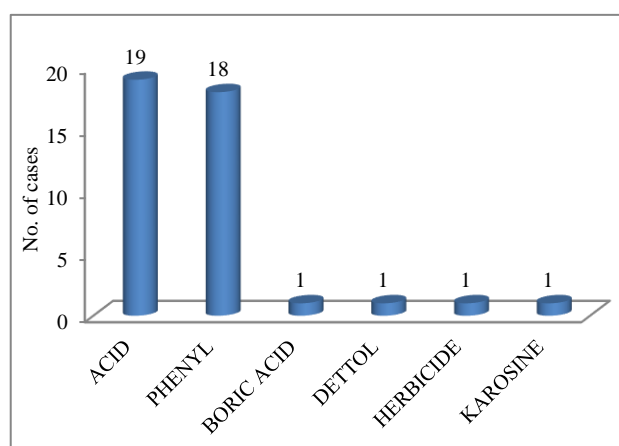


Figure 4: Nature of corrosive.

In present study the most common nature of corrosive used was acid- 19 (46.3%) followed by phenyl in 18 (43.9%) cases.

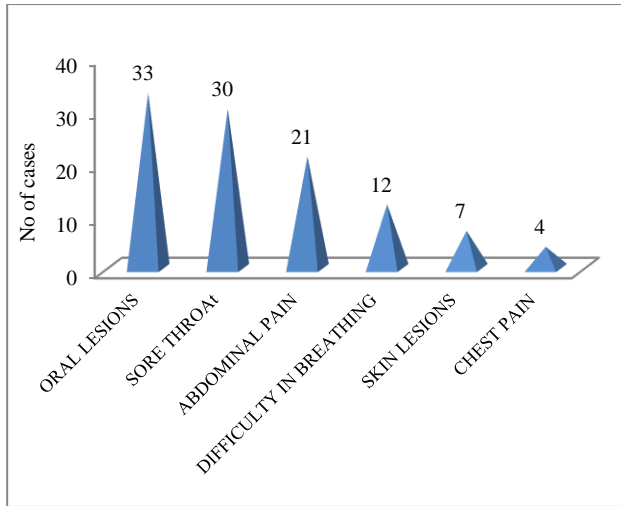


Figure 5: Clinical symptoms of corrosive ingestion.

On clinical examination it was found that in 33 (80.5%) of the cases had oral lesions due to corrosive action of the liquid ingested, 30 (73.2%) cases had sore throat, 21 (51.2%) had abdominal pain. 12 (29.3%) cases had difficulty in breathing may be because of simultaneous inhalation of the corrosive. Only 7 (17.1%) had skin lesions and 4 (9.8%) even complained of chest pain.

Out of 41 patients 2 patients died in emergency room during initial resuscitation. Rest 39 patients undergone Upper GI endoscopy within 24 to 48 hrs of admission and classified according to Zargars classification.

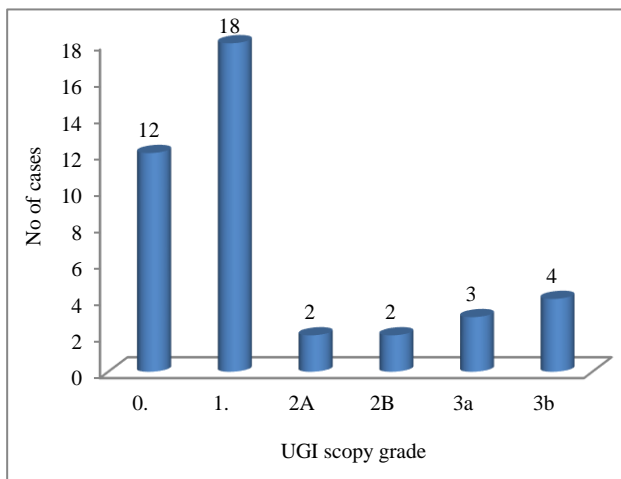


Figure 6: UGI scopy grade.

Upper gastro intestinal (UGI) endoscopy was performed, it was found that majority cases had grade 1 (18, 43.9%) and 12 (29.3%) cases were of grade 0. Four (9.7%) cases were of grade 2 and 7 (17%) were of grade 3.

On initial presentation of the patients, majority was given conservative treatment (35, 85.4%) and 4 (9.8%) cases were treated surgically by feeding jejunostomy. However 2 (4.9%) cases expired before upper GI endoscopy.

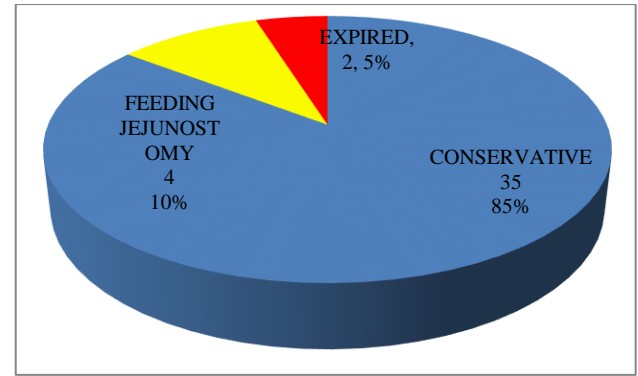


Figure 7: Management at initial presentations.

All the survived cases were called for follow up, and all of them turned up for re-visit. Out of 39 cases, 8 (20.5%) had dysphagia and 5 (12.8%) still had abdominal pain and only 3 (7.7%) had hoarseness. These are the long term complications of corrosive ingestion.

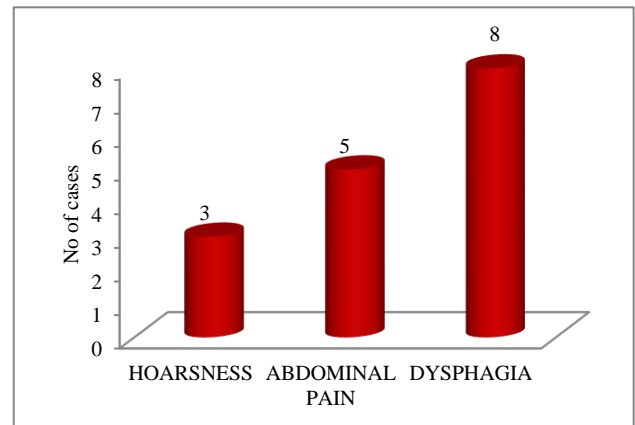


Figure 8: Clinical features at follow-up.

At the follow up visit of the cases most were advised for conservative management (31, 75.6%) but 7 (17%) required surgical management.

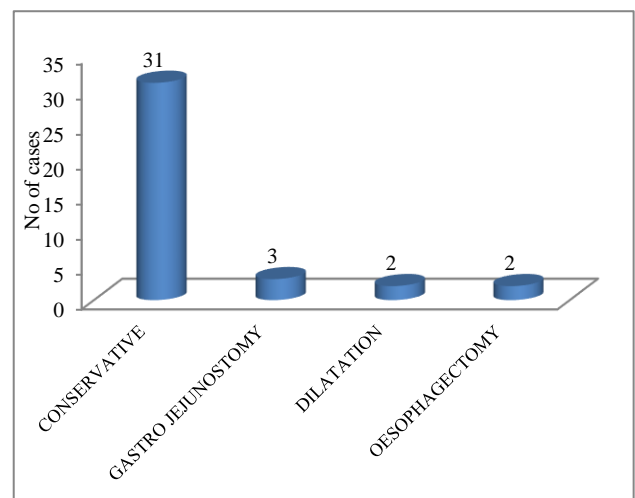


Figure 9: Management at follow up

Esophageal dilatation was done in 2 (4.9%) cases and 2 (4.9%) cases required esophagectomy and gastro jejunostomy was conducted in 3 (7.3%) cases. One cases further expired during follow up. So, in total 3 cases expired in the study and finally 38 survived.

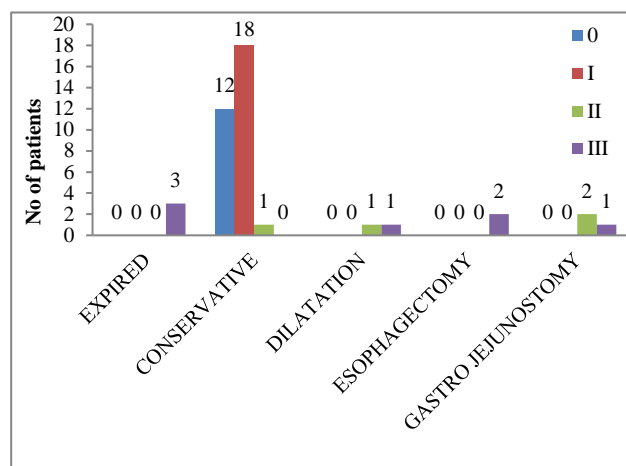


Figure 10: Correlation of UGI endoscopy grade with final outcome.

Majority of the cases were of grade 1 (18, 43.9%) in the UGI endoscopy, 12 (29.2%) were of zero grade, 4 (9.7%) and 7 (17.1%) were of grade 2 and 3 respectively. All the expired patients were of grade 3, this was statistically significant ($p < 0.001$).

DISCUSSION

All the patients presenting to emergency department with history of corrosive ingestion were admitted and initial resuscitation was performed. Upper GI endoscopy was done within 48 hours of admission to assess the degree and extent of injury. The injury was graded on the basis of classification by Zargar.⁵

Out of the total 41 cases majority were in the age group of 21-30 years- 17 (41.5%) cases, followed by age group of below 20 years- 14 (34.1%) and only 3 (7.3 %) cases were above 40 years. Overall the incidence of corrosive ingestion was reducing as the age was increasing.

In comparison to the present study, from the previous studies done by Mirji P et al, the age of the patients ranged from 14 years to 67 years, where by Dey S et al⁷, the patients of age 10-55 years and by Rajabi MT et al the age of the subjects ranged from 18 to 54 years.⁶⁻⁸

In present study out of total 41 cases majority were females- 27 (65.9%) and only 14 (34.1%) were males. This shows higher preponderance of females that was similar to the previous studies done by Mirji P et al 62.5% were females and 37.5% were males and by Satar S et al, 56.8% females and 43.2% males.⁹ Overall the most common cause of corrosive ingestion was suicidal found in 30 (73.2%) cases and only 11 (26.8%) were

accidental. Similar finding was in study of Mirji P et al where in 15 patients, the corrosive ingestion was suicidal (93.75%) and in one patient it was accidental (6.25%). However, no cases of homicidal injuries were seen. Where as in the study of Rajabi MT et al the caustic ingestion was accidental in 6 patients and a suicidal attempt was in 8 patients.

In present study the most common nature of corrosive used was acid- 19 (46.3%) followed by phenyl in 18 (43.9%) cases. These two agents are easily available in all households; thus cases tend to consume them more readily. Also they could be accidentally mixed with potable things (water/ cold drinks/alcohol etc.) thus are also consumed accidentally.

Present finding was similar to Mirji P et al, who noted that 10 patients out of the 16 consumed acids (62.5%), 3 patients consumed alkalis (18.75%) and 3 patients consumed substances which were difficult to find out (18.75%). In the study of Dey S et al the offending agent was found to be acids (muriatic acids, Harpic and others) in all cases. In the study of Satar S et al the agents included sodium hypochlorite, used as household bleach, in 24 patients and hydrochloric acid, used as a surface cleaner, drain opener, and toilet and bowl cleaner, in 13 patients. All the patients ingested these agents orally. Rajabi MT et al found that the corrosive agents were a strong acid in 13 cases (nitric acid in four, hydrochloric acid in seven and sulfuric acid in two cases). Liquid lye (potassium hydroxide) in only one case.

On clinical examination it was found that, 33 (80.5%) of the cases had oral lesions due to corrosive action of the liquid ingested. 30 (73.2%) cases had sore throat, 21 (51.2%) had abdominal pain due to local irritation by the corrosives. 12 (29.3%) cases had difficulty in breathing may be because of simultaneous inhalation of the corrosive. Only 7 (17.1%) had skin lesions and 4 (9.8%) even complained of chest pain.

In the study of Mirji P et al the predominant symptoms in the early cases were pain, hematemesis and retching. In the late cases, the symptom was difficulty in swallowing. Other symptoms were the drooling of saliva, anxiety, cough and hoarseness of the voice.

Dey S et al found that acute symptoms like peri-oral ulceration present in 17 cases (26.15%), while aspiration pneumonitis was present in 7 cases (10.8%). Dysphagia to solids was found to be the commonest presentation and was reported by 53.8% patients, followed by absolute dysphagia in the rest. Vomiting was present in cases of gastric outlet obstruction. The early symptoms were pain and burning sensation in the mouth and throat.

Upper gastro intestinal (UGI) endoscopy was performed on all the cases and it was found that majority cases had grade 1. (18, 43.9%) and 12 (29.3%) cases were of grade 0. 4 (9.7%) cases were of grade 2 and 7 (17%) were of

grade 3. All the expired patients were of grade 3. This was statistically significant ($p < 0.001$).

Mirji P et al conducted upper GI endoscopy and found that the cases had oesophageal injury, whether the case was an early or late one or whether it was caused by acid or alkali. In the study of Satar S et al endoscopic results were as follows: grade 0 in 8 (21.6%) patients, grade 1 in 17 (45.9%) patients, grade 2a in 5 (13.5%) patients, and grade 2b in 7 (18.9%) patients.

In present study, among registered 41 cases of corrosive ingestion, 52 cases get expired. And in remaining 39 cases, 35 cases were given conservative treatment to have nothing per mouth and were treated with antibiotic and parenteral nutrition. Feeding jejunostomy was done in 4 cases at 2 to 3 weeks or later to maintain nutrition followed by Barium meal at 6 weeks and decisions were taken accordingly. In 4 cases oesophagus was affected, among which 2 have short segment involvement and 2 have long segment involvement. For short segment involvement regular dilation ranging from 2 to 6 sitting was done and for long segment esophagectomy with colon bypass was done. Gastro jejunostomy done in 3 cases of gastric outlet obstruction.

In the study of Mirji P et al, the initial management was conservative in 13 cases (81.25%). 3 cases underwent surgery for the initial management. One case underwent antrectomy and Billroth 1 gastro-duodenostomy. One more patient needed antrectomy with anterior gastrojejunostomy. Another patient underwent feeding jejunostomy and oesophageal dilatation. The same patient developed tracheo-oesophageal fistula on follow up and needed definitive surgery. The most common complication was stricture in the oesophagus (62.5%), two cases developed an antral stricture and chest complications were seen in one case. No patient developed hiatus hernia or malignancy during this study period.

Rajabi MT et al found that because of extensive gastric necrosis in the cases, total gastrectomy and blunt esophagectomy without thoractomy was performed and a left terminal esophagostomy and a feeding jejunostomy completed the procedure. The remaining 12 patients were discharged from the hospital as soon as they could tolerate oral fluids. Feeding jejunostomy was performed 8-89 days (mean 48 days) after caustic ingestion. Follow-up esophagograms showed severe esophageal stricture requiring the patients to be referred to an endoscopist for antegrade esophageal dilatation. In three cases, due to the long stricture of the esophagus, dilations were not performed. However, in the remaining cases, dilatation of the esophagus were attempted over 1-3 sessions. As these attempts were unsuccessful, the patients were referred for definitive surgery.

CONCLUSION

Most of the case in the study was young. 31 (75.6%) were below 30 years of age that is highly productive age. The most common mode of ingestion of corrosive was suicidal found in 30 (73.2%) of the cases. At first visit 35 (85.4%) cases were provided conservative management out of them none expired. Four (11.4%) cases required surgical intervention (feeding jejunostomy). On follow up 31 cases continued in conservative treatment and one patient got expired, oesophageal dilation were done in 2 patients, oesophagectomy in 2 cases and gastrojejunostomy in 3 patients.

Funding: No funding sources

Conflict of interest: None declared

Ethical approval: The study was approved by the institutional ethics committee (ECR/85/Inst/GJ/2013)

REFERENCES

1. Lakshmi CP, Vijayahari R, Kate V, Ananthakrishnan N. A hospital-based epidemiological study of corrosive alimentary injuries with particular reference to the Indian experience. *Nat Med J India*. 2013;26(1):31-6.
2. Hughs TB, Kelly MD. Corrosive ingestion and the surgeon. *J Am Coll Surg*. 1999;50:5-22.
3. Spechler SJ, Taylor MB. Caustic ingestion. In: Taylor MB ed. *Gastrointestinal emergencies*, 1st edition. Williams and Wilkins; 1997:19-28.
4. Goldman LP, Weigert JM. Corrosive substance ingestion: A review. *Am J Gastroenterol*. 1984;79:85.
5. Zargar SA, Kochhar R, Mehta S, Mehta SK. The role of fiberoptic endoscopy in the management of corrosive ingestion and modified endoscopic classification of burns. *Gastrointest Endosc*. 1991;37:165-9.
6. Mirji P, Joshi C, Management of corrosive injuries of the upper gastrointestinal tract. *J Clin Diagn Res*. 2011;5(5):944-7.
7. Dey S, Dey I. Epidemiology of oesophageal stricture and its outcome: a study among patients attending a tertiary hospital of Kolkata. *Al Ameen J Med Sci*. 2013;6(2):176-9.
8. Rajabi MT, Maddah G, Bagheri R. Corrosive injury of the upper gastrointestinal tract: review of surgical management and outcome in 14 adult cases. *Iranian J Otorhinolaryngol*. 2015;27(1):78.
9. Satar S, Topal M, Kozaci N. Ingestion of caustic substances by adults. *Am J Therap*. 2004;11:258-61.

Cite this article as: Baluni US, Mistry T, Kothari A, Patel T. Corrosive injury of upper gastrointestinal tract and its outcome. *Int Surg J* 2017;4:1594-8.