

Letter to the Editor

Acromegaly with negative immunostaining for growth hormone on the contrary to silent somatotroph tumor

Sir,

Silent somatotropinomas are not rare. On the contrary to that, the absence of GH immunostaining in acromegaly has not been well defined. So, we would like to draw the clinician's attention to such an entity through a case of acromegaly with negative GH staining.

Fifty-four-year-old male patient applied for the complaints of acral enlargement, headache and excessive sweating. Acromegaloid appearance was remarkable. The gap between teeth was increased. On his laboratory examination; the level of Growth Hormone (GH) and IGF-1 level were 19.7 ng/mL and 965 ng/mL (71-284), respectively. There was a lesion with 10x10x13 mm in diameters located on left pituitary gland showing pituitary adenoma. Trans-sphenoidal operation was performed and the pathology was consistent with pituitary adenoma with positive immunostaining for follicle stimulating hormone (FSH) and focal thyroid stimulating hormone (TSH) (Figure 1A, B). After diagnosis of acromegaly, as immunostaining for GH was negative, evaluation of pathological slides was repeated but the result was the same indicating negative GH immunostaining. In the postoperative period, GH and IGF-1 levels were 4 ng/mL and 800 ng/mL, respectively. Somatostatin analog treatment was started postoperatively to provide biochemical and clinical control of the disease.

Pituitary tumors are classified according to specific immunohistochemical staining patterns. When the clinical features are absent in context of positive immunostaining for somatotroph, corticotroph, thyrotroph, gonadotroph, those adenomas are defined as silent adenomas.^{1,2} Chinezu et al found that silent somatotroph adenoma was 2% of total 80 pituitary adenoma (n=21 silent, n=59 active acromegaly).³ The opposite condition in which there is negative staining for GH in patients with clinical acromegaly diagnosed biochemically is more rare. To our knowledge in the literature there is one case report and five case series of negative GH immunostaining in acromegalic patients.^{4,5} Schroeder et al stated that five cases of negative GH immunostaining comprises 3.7% of patients (out of total 136 acromegaly patients).⁴ This ratio shows that this issue may not be so rare. One of the possible explanation for this condition is technical failure. As regarding to technical failure, adequate pituitary tissue may not be taken or histopathological evaluation may not be correct.

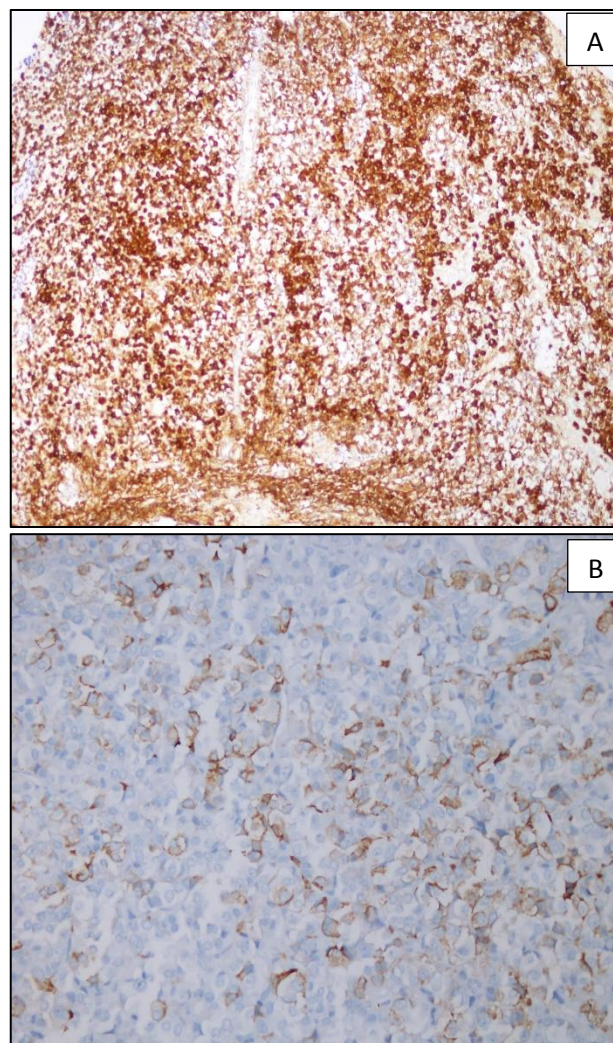


Figure 1: The adenoma demonstrated diffuse cytoplasmic reactivity for follicle-stimulating hormone (A) and focally for thyroid stimulating hormone (B) (Immunohistochemistry x20).

Sometimes antigenicity may be lost during fixation or embedding leading to negative immunostaining.⁴ In our case, the pathological slides were evaluated second time and the result didn't change. GH producing adenomas are divided into densely-granulated and sparsely-granulated somatotrop adenoma. Secretory activity of GH adenoma may affect synthesis, storage and excretion of GH. So, GH could not be stained immunohistochemically due to secretory activity features of sparsely-granulated somatotrop adenoma.⁴ Immunohistochemistry can detect

hormones stored in remarkable proportion. GH protein may be secreted immediately so, negative staining can occur with the lack of cytoplasmic stores. Somatotroph tumors are derived from Pit-1-lineage. Chinezu et al.¹ found that silent somatotroph adenomas were mostly sparsely granulated and had lower expression of Pit-1 when compared to acromegaly. Unfortunately, we couldn't perform Pit-1 test for our case.

If we suspect the diagnosis of acromegaly, further test should be done even if the GH immunostaining is negative. There is a need for further studies to decide whether this situation has a prognostic significance.

**Hatice Ozisik^{1*}, Banu Sarer Yurekli¹,
Nilufer Ozdemir Kutbay¹, Ilker Altun¹,
Yesim Ertan², Fusun Saygılı¹**

¹Department of Endocrinology and Metabolism,
²Department of Pathology, Ege, University, İzmir,
Turkey

***Correspondence to:**

Dr. Hatice Ozisik,
E-mail: drhaticege@hotmail.com

REFERENCES

1. Chinezu L, Vasiljevic A, Trouillas J, Lapoirie M, Jouanneau E, Raverot G. Silent somatotroph tumour revisited from a study of 80 patients with and without acromegaly and a review of the literature. *Eur J Endocrinol.* 2017;176(2):195-201.
2. Sidhaye A, Burger P, Rigamonti D, Salvatori R. Giant somatotropinoma without acromegalic features: more "quiet" than "silent": case report. *Neurosurgery.* 2005;56(5): E1154
3. Baldeweg SE, Pollock JR, Powell M, Ahlquist J. A spectrum of behaviour in silent corticotroph pituitary adenomas. *Br J Neurosurg* 2005;19:38-42.
4. Schroeder JL, Spiotta AM, Fleseriu M, Prayson RA, Hamrahian AH, Weil RJ. Absence of immunostaining for growth hormone in a subset of patients with acromegaly. *Pituitary* 2014;17:103-8.
5. Lloyd RV, Cano M, Chandler WF, Barkan AL, Horvath E, Kovacs K. Human growth hormone and prolactin secreting pituitary adenomas by in situ hybridization. *Am J Pathol.* 1989;134:605-13.

Cite this article as: Ozisik H, Yurekli BS, Kutbay NO, Altun I, Ertan Y, Saygılı F. Acromegaly with negative immunostaining for growth hormone on the contrary to silent somatotroph tumor. *Int Surg J* 2017;4:1506-7.