International Surgery Journal
Palanisamy V et al. Int Surg J. 2026 Dec;13(12):2656-2659
https://www.ijsurgery.com
pISSN 2349-3305 | eISSN 2349-2902
DOI: https://dx.doi.org/10.18203/2349-2902.isj20264382

Case Report

Povidone-iodine instillation through an indwelling drain for a persistent perinephric collection following renal transplantation: a case report

Vimala Palanisamy*, B. Palanikumar, J. Sivabalan, V. Ezhil Sundar, P. V. Thiruvarul

Institute of Urology, Rajiv Gandhi Government General Hospital and Madras Medical College, Chennai, Tamil Nadu, India

Received: 20 October 2026
Revised: 16 November 2026
Accepted: 18 November 2026

***Correspondence:**
Dr. Vimala Palanisamy,
E-mail: vimala.palanisamy@yahoo.com

Copyright: © the author(s), publisher and licensee Medip Academy. This is an open-access article distributed under the terms of the Creative Commons Attribution Non-Commercial License, which permits unrestricted non-commercial use, distribution, and reproduction in any medium, provided the original work is properly cited.

ABSTRACT

Perinephric collections are recognised complications following kidney transplantation and may pose diagnostic and therapeutic challenges. Persistent collections with high drain output require evaluation to determine their underlying cause and guide management. A 38-year-old woman with chronic kidney disease stage G5D underwent ABO-compatible, living-related kidney transplantation. She had immediate graft function, with serum creatinine decreasing to 0.7 mg/dL by postoperative day (POD) 2. Subsequently, she developed right iliac fossa tenderness, fever and an enlarging perinephric collection. Computed tomography demonstrated a complex collection with internal air locules, initially interpreted as an infected haematoma/abscess. Despite conservative management and antimicrobial therapy, the collection and high drain output persisted. Drain-fluid analysis did not support a urinoma. A lymphocele was subsequently suspected, and three instillations of 50ml of 10% povidone-iodine solution were performed through the existing drain on POD 24, 27 and 29, with a two-hour dwell time per instillation. Drain output initially remained high but subsequently declined, allowing drain removal on POD 45. The patient remained clinically well for three months after transplantation, with preserved graft function at discharge. Drain-based povidone-iodine instillation may be a potential management option for selected persistent post-transplant perinephric collections. Further evidence is required to establish its efficacy and safety.

Keywords: Kidney transplantation, Perinephric collection, Lymphocele, Povidone-iodine, Sclerotherapy

INTRODUCTION

Kidney transplantation is the preferred treatment for eligible patients with end-stage kidney disease, but postoperative perinephric fluid collections remain an important cause of morbidity. These collections may represent hematomas, urinomas, lymphoceles or abscesses, and their differentiation is essential because management varies according to the underlying pathology. Clinical presentation, imaging findings and fluid analysis are complementary in establishing the diagnosis.[1,2] Lymphoceles are among the recognised urological complications following kidney transplantation, resulting from disruption of recipient lymphatic channels or donor hilar lymphatics during surgical dissection. They commonly present within the first few weeks to months after transplantation and may manifest as persistent drain output, graft-region discomfort, urinary obstruction or vascular compression. Ultrasonography is generally the initial imaging modality, while computed tomography helps delineate the extent and anatomical relationships of complex collections.[1,2]

Management depends on the size, symptoms and persistence of the collection. Observation may be

appropriate for small, asymptomatic lymphoceles, whereas symptomatic or persistent collections may require percutaneous drainage, sclerotherapy, laparoscopic fenestration or open surgical marsupialisation. Sclerotherapy using agents such as povidone–iodine has been described as a minimally invasive approach intended to obliterate the lymphatic cavity and reduce recurrence, although the evidence supporting individual agents and protocols remains limited.[3,4]

This case describes a persistent, complex perinephric collection following living-related kidney transplantation, initially complicated by imaging features suggestive of an infected hematoma or abscess. Following exclusion of a urinoma and failure of conservative management, the collection was managed with povidone–iodine instillation through the existing drain, with gradual reduction in drain output and preservation of graft function.

CASE REPORT

A 38-year-old woman with chronic kidney disease (CKD) stage G5D and systemic hypertension, with an unknown primary kidney disease, underwent ABO-compatible, living-related kidney transplantation at our institution.

The patient initially presented with pedal oedema approximately 10 months before transplantation and was subsequently found to have advanced kidney disease. Pre-transplant investigations revealed a urine protein–creatinine ratio of 3.2, microscopic hematuria (RBC ++), negative antinuclear antibodies and normal C3 and C4 levels. An attempted native kidney biopsy was unsuccessful. The patient underwent hemodialysis twice weekly through a left radiocephalic arteriovenous fistula, with a dialysis vintage of approximately six months. The patient received antithymocyte globulin induction with perioperative methylprednisolone. Maintenance immunosuppression comprised tacrolimus, mycophenolate mofetil and prednisolone.

The graft kidney was placed in the right iliac fossa. The donor renal artery was anastomosed end-to-end to the right internal iliac artery and the renal vein was anastomosed end-to-side to the right external iliac vein. Neocystoureterostomy was performed and a 28-Fr drain was placed in the operative bed after hemostasis was secured. The patient had immediate graft function, with serum creatinine decreasing to 0.7 mg/dL by postoperative day (POD) 2. Ultrasonography on POD 2 showed a graft measuring 10.8×5.5 cm, with preserved corticomedullary differentiation, normal echogenicity and a normal pelvicalyceal system. No perinephric collection was identified.

On POD 4, ultrasonography performed during assessment for drain removal revealed a small perinephric collection measuring 4.9×1.5 cm. On POD 6, the patient developed right iliac fossa tenderness, an increase in drain output to 300 ml and a fall in hemoglobin. CT of the kidneys, ureters and bladder demonstrated a perinephric collection measuring 6×3.6×3.5 cm, extending into the pelvis and a separate lower-pole collection measuring 3.1×2×5 cm.

Between POD 7 and POD 10, the patient developed fever and persistent graft-region tenderness and was commenced on meropenem and liposomal amphotericin B. CT transplant angiography on POD 10 demonstrated an enlarging, complex perinephric collection measuring approximately 6.6×7.6×14 cm, with mixed attenuation, peripheral rim enhancement and internal air locules, interpreted radiologically as an infected hematoma/abscess. The collection extended into the right perihepatic space and anteriorly towards the right psoas muscle. The graft was enlarged and oedematous, with renal pelvic urothelial thickening. The transplant renal vessels were patent, with no active contrast extravasation.

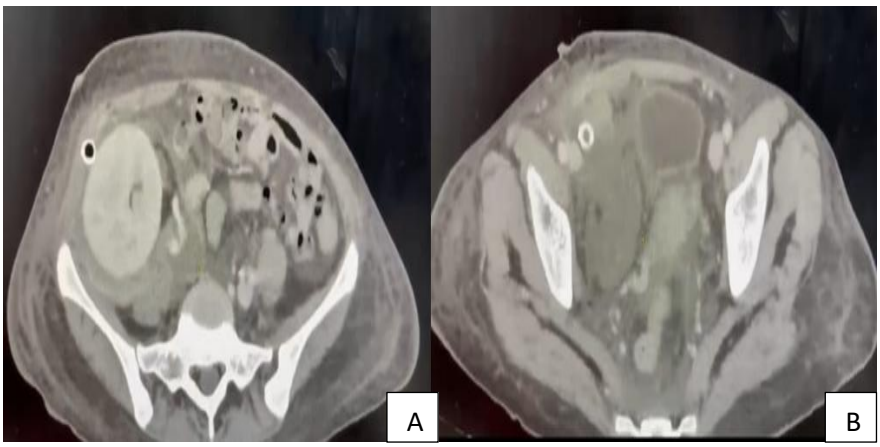

Figure 1 (A and B): CT transplant angiography on POD 10- left image showing transplanted kidney in the right iliac fossa showing normal cortical enhancement. Left image showing complex perinephric collection measuring approximately 6.6×7.6×14 cm, with mixed attenuation, peripheral rim enhancement. Drain noted inside the collection.

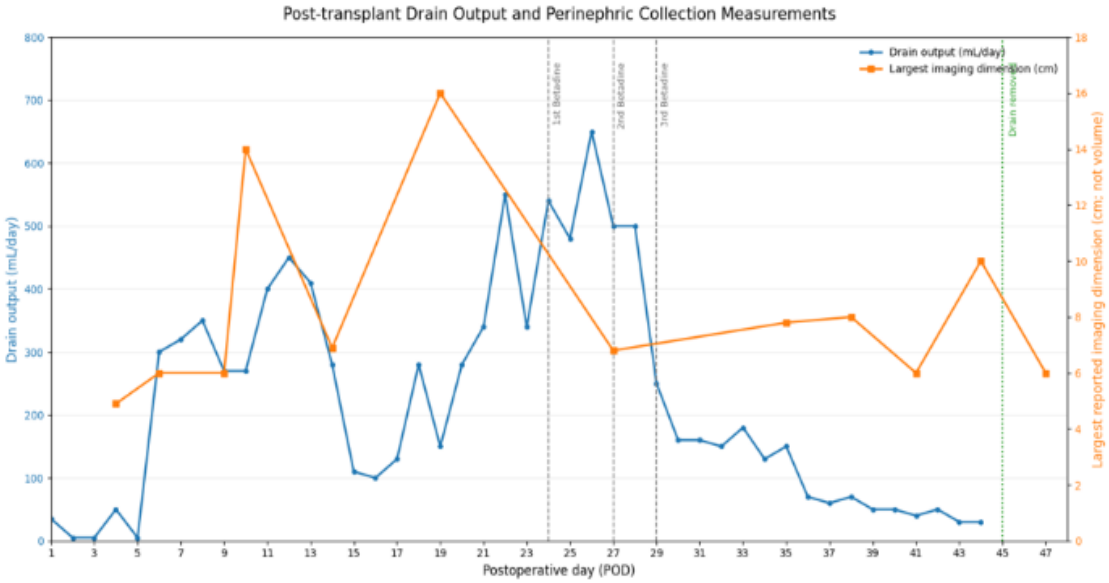

Figure 2: Post-transplant drain output and perinephric collection measurements in relation to postoperative day and sclerotherapy.

Serial postoperative drain output and largest reported perinephric collection dimension following kidney transplantation. Vertical dashed lines indicate povidone–iodine instillations on POD 24, 27 and 29, and the green dotted line indicates drain removal on POD 45. Drain output is expressed in ml/day, and collection size is expressed in centimetres.

Drain-fluid analysis did not support a urinoma and the perinephric collection and high drain output persisted despite conservative management and antimicrobial therapy. CT performed on POD 19 demonstrated a persistent perinephric fluid collection measuring 3.5×5.3×16 cm, extending into the pelvis. In view of the persistent collection and continued drain output, a lymphocele was subsequently suspected. The urology team performed three instillations of 50 ml of 10% povidone-iodine solution through the existing drain on POD 24, 27 and 29, at alternate-day intervals. The solution was retained for two hours during each instillation, after which the drain was unclamped.

Table 1: Perinephric drain fluid analysis.

Drain fluid analysis	Result
Total cell count/differential	Less than 15 cells/µl
Drain-fluid urea	29 mg/dl
Drain-fluid creatinine	1.0 mg/dl
Total cholesterol	75 mg/dl
Triglycerides	69 mg/dl
Bacterial culture	No growth
KOH mount	Negative
Fungal culture	No growth

Drain output remained substantial following the initial instillation, reaching 650 ml on POD 26. Output subsequently declined, measuring 500 ml on POD 27 and 250 ml on POD 29, with a further gradual reduction over the ensuing days. The drain was removed on POD 45 following a sustained decrease in output. Ultrasonography on POD 47 demonstrated a residual perinephric collection measuring approximately 6×4 cm. At discharge on POD 48, serum creatinine was 0.66 mg/dL, indicating preserved graft function. The patient remained clinically well during follow-up, with no further febrile episodes or reported clinical deterioration during the first three months after transplantation.

DISCUSSION

Perinephric fluid collections are recognised complications following kidney transplantation and include hematomas, urinomas, lymphoceles and abscesses. Their clinical significance depends on their size, location, rate of accumulation and potential effects on graft function. Early postoperative collections are particularly challenging because their clinical and radiological features may overlap, necessitating serial imaging and biochemical analysis of drain fluid to establish the likely diagnosis.[1]

Lymphoceles arise from disruption of recipient pelvic lymphatics or donor renal hilar lymphatic channels during transplantation. They may present with persistent drain output, graft-region discomfort, infection or compression of adjacent structures. Ultrasonography provides an initial assessment, while computed tomography helps delineate the extent of complex collections and identify features such as hemorrhage, rim enhancement or gas. In this patient, the enlarging collection, internal air locules and fever initially raised

concern for an infected hematoma or abscess. The subsequent absence of biochemical evidence supporting a urinoma, together with persistent drainage, prompted consideration of a lymphatic collection. However, without definitive fluid analysis or histopathological confirmation, a lymphocele remains a presumptive diagnosis.[5]

Management of symptomatic or persistent lymphoceles includes percutaneous drainage, sclerotherapy and surgical fenestration. Drainage alone may be insufficient because the underlying lymphatic leak can persist, resulting in recurrence. Sclerotherapy aims to induce inflammation and adhesion of the opposing cavity walls, thereby reducing further fluid accumulation. Povidone–iodine has been used as a sclerosant in post-transplant lymphoceles, offering a minimally invasive alternative to surgery in selected patients.[6]

In a contemporary cohort of 60 kidney transplant recipients treated with povidone–iodine sclerotherapy, Baboudjian et al. reported treatment success in 55% of cases, with recurrent collections successfully managed using repeat sclerotherapy or surgical fenestration in many patients. These findings suggest that sclerotherapy can be useful, although treatment failure and procedure-related complications remain possible.[4]

In the present case, three instillations of 50 ml of 10% povidone–iodine were administered through the existing drain at alternate-day intervals, with a two-hour dwell time. Although the drain output initially remained high, it subsequently declined, permitting drain removal on postoperative day 45. The residual collection on ultrasonography did not compromise graft function, and serum creatinine remained stable at discharge. This outcome demonstrates the potential utility of drain-based sclerotherapy when persistent drainage makes continued conservative management impractical. Nevertheless, spontaneous resolution or the contribution of concurrent drainage cannot be excluded.

An important limitation is the absence of definitive confirmation of the collection's lymphatic origin and the relatively short follow-up period. Furthermore, the concentration and dwell time of povidone–iodine should be individualized according to institutional protocols and specialist guidance, considering potential local tissue injury and other complications. Longer follow-up is necessary to establish durable resolution and exclude recurrence.[7]

CONCLUSION

Persistent perinephric fluid collections following kidney transplantation pose diagnostic and therapeutic challenges, particularly when clinical and radiological findings overlap. Povidone–iodine sclerotherapy through an existing drain may be a minimally invasive treatment option for persistent collections suspected to represent lymphoceles, potentially avoiding surgical intervention in selected patients. Careful patient selection, appropriate monitoring and longer follow-up are essential to confirm durable resolution and ensure preservation of graft function.

Funding: No funding sources
Conflict of interest: None declared
Ethical approval: Not required

REFERENCES

1. Richard HM III. Perirenal transplant fluid collections. Semin Intervent Radiol. 2004;21(4):235-7.
2. Golriz M, Klauss M, Zeier M, Mehrabi A. Prevention and management of lymphocele formation following kidney transplantation. Transplant Rev (Orlando). 2017;31(2):100-5.
3. Guachetá-Bomba PL, Sandoval Guerrero MF, Ramirez G, Garcia-Perdomo HA. Lymphocele complication after kidney transplant: current literature review and management algorithm. Exp Clin Transplant. 2023;21(11):855-9.
4. Baboudjian M, Tadrist A, Gondran-Tellier B, McManus R, Akiki A, Gaillet S, et al. Povidone-iodine sclerotherapy of primary symptomatic lymphocele after kidney transplantation. Int Urol Nephrol. 2021;53(4):685-90.
5. Alshamsi I, Alshamsi H, Al Falahi S, Sharma A, Halawa A. Perinephric transplant fluid collection approach and management. Saudi J Kidney Dis Transpl. 2019;30(3):564-70.
6. Lucewicz A, Wong G, Lam VW, Hawthorne WJ, Allen RDM, Craig JC, et al. Lymphatic disorders after renal transplantation: new insights for an old complication. Clin Kidney J. 2015;8(5):615-22.
7. Chandrasekaran D, Meyyappan RM, Rajaraman T. Instillation of povidone iodine to treat and prevent lymphocele after renal transplantation. BJU Int. 2003;91(3):296.

Cite this article as: Palanisamy V, Palanikumar B, Sivabalan J, Sundar VE, Thiruvarul PV. Povidone-iodine instillation through an indwelling drain for a persistent perinephric collection following renal transplantation: a case report. Int Surg J 2026;13:2656-9.