International Surgery Journal
Ninan MK et al. Int Surg J. 2026 Dec;13(12):2652-2655
https://www.ijsurgery.com
pISSN 2349-3305 | eISSN 2349-2902

DOI: https://dx.doi.org/10.18203/2349-2902.isj20264381

Case Report

Awake cranioplasty under ultrasonography-guided selective scalp block in a high-risk patient: a case report

Melvin K. Ninan*, Vishnu P. Shelley, Anand P. Nair

Department of Neurosurgery, Dr. K. M. Cherian Institute of Medical Sciences, Kallissery, Kerala, India

Received: 21 October 2026
Accepted: 16 November 2026

***Correspondence:**
Dr. Melvin K. Ninan,
E-mail: drmelvinkn@gmail.com

Copyright: © the author(s), publisher and licensee Medip Academy. This is an open-access article distributed under the terms of the Creative Commons Attribution Non-Commercial License, which permits unrestricted non-commercial use, distribution, and reproduction in any medium, provided the original work is properly cited.

ABSTRACT

The aim of the study was to describe the anaesthetic management of awake cranioplasty using selective scalp nerve blocks and dexmedetomidine sedation in a patient with significant cardiopulmonary comorbidities and a history of recurrent bronchospasm-associated cardiac arrests. Awake cranioplasty may be considered in carefully selected patients when general anaesthesia poses substantial risks. Successful management requires effective scalp analgesia, appropriate sedation, patient cooperation, and preparedness for emergency airway intervention. This case highlights an individualized anaesthetic approach in a patient with severe bronchial asthma and previous perioperative and intensive care unit cardiac arrests associated with bronchospasm. A 68-year-old woman with diabetes mellitus, hypertension, dyslipidaemia, coronary artery disease status post percutaneous transluminal coronary angioplasty, and bronchial asthma sustained severe traumatic brain injury with a right front temporoparietal subdural hematoma (SDH). She underwent emergency decompressive craniectomy and evacuation of the SDH under general anaesthesia. The perioperative course was complicated by severe bronchospasm and cardiac arrest, followed by a second episode of severe bronchospasm-associated cardiac arrest in the intensive care unit on the following day. Return of spontaneous circulation was achieved after cardiopulmonary resuscitation during both episodes. Following neurological recovery, she was discharged and subsequently presented for cranioplasty. Considering her significant cardiopulmonary comorbidities, history of recurrent bronchospasm and cardiac arrest, and preference to avoid general anaesthesia and mechanical ventilation, awake cranioplasty was planned. Awake cranioplasty using selective scalp nerve blocks with ultrasound-guided (USG) guidance, dexmedetomidine sedation, and supplementary topical local anaesthesia may be a feasible alternative in carefully selected patients in whom general anaesthesia presents substantial cardiopulmonary concerns. This case emphasizes individualized anaesthetic planning, effective analgesia, close patient communication, careful assessment of cumulative local anaesthetic doses, and readiness for emergency airway management. Further evidence is required to establish the safety and generalizability of this approach.

Keywords: Awake cranioplasty, Scalp nerve block, Dexmedetomidine, Bronchial asthma, Cardiac arrest, Dural analgesia, Neuroanaesthesia

INTRODUCTION

Cranioplasty is a reconstructive surgery following craniectomies to prevent trephined syndrome, hemispheric collapse and improves cerebral haemodynamics.[1] It is commonly done under general anaesthesia; however, the anaesthetic approach must be individualized according to the patient's comorbidities, airway and respiratory risks, cardiovascular status, surgical requirements, and preferences.

Awake cranioplasty poses additional challenges because of the potential for dural adherence to surrounding tissues, discomfort during dissection, difficulty in obtaining landmarks. Evidence specifically addressing awake cranioplasty remains limited compared with the literature on awake craniotomy for intracranial lesions.

We describe the anaesthetic management of a patient with bronchial asthma, coronary artery disease, and two previous episodes of bronchospasm-associated cardiac arrest during an earlier neurosurgical admission, who subsequently underwent cranioplasty using ultrasound-guided selective scalp nerve blocks and dexmedetomidine sedation.

CASE REPORT

A 68-year-old woman with diabetes mellitus, hypertension, dyslipidemia, coronary artery disease status post percutaneous transluminal coronary angioplasty, and bronchial asthma sustained severe traumatic brain injury. Computed tomography (CT) brain demonstrated a right frontotemporoparietal subdural hematoma (SDH) and a maximum thickness of 18 mm. She underwent right frontotemporoparietal decompressive craniectomy with evacuation of the subdural hematoma under general anaesthesia. The patient developed severe bronchospasm during the decompressive craniectomy. The episode was associated with acute cardiovascular instability, progressing to ventricular fibrillation. Cardiopulmonary resuscitation was initiated promptly according to advanced cardiovascular life support protocols, and return of spontaneous circulation was achieved. She had a second similar episode during her intensive care unit (ICU) stay. The patient subsequently recovered neurologically and was discharged with a Glasgow coma scale score of 15. She later presented for elective cranioplasty.

In view of severe bronchial asthma, coronary artery disease, history of two episodes of severe bronchospasm associated with cardiac arrest, and patient's preference to avoid general anaesthesia, Following individualized risk assessment, multidisciplinary meeting and detailed preoperative counselling, an awake anaesthetic technique was planned using ultrasound-guided selective scalp nerve blocks supplemented by dexmedetomidine sedation. The patient was counselled regarding the proposed technique, the anticipated stages of surgery and the possibility of discomfort during dural manipulation. The potential need for additional analgesia, airway intervention, and conversion to general anaesthesia in the event of inadequate analgesia, agitation, respiratory compromise, cardiovascular instability, or surgical complications was discussed. Her regular asthma medications were continued during the preoperative period; antiplatelet was stopped 5 days prior to surgery. Preoperative optimization was undertaken to achieve the best possible respiratory status before surgery. A contingency plan for emergency airway management and resuscitation was established.

The patient was transferred to the operating room, and standard monitoring was established. Antiepileptic, antiemetic, and antacid medications were administered. The patient's eyes were taped to prevent inadvertent exposure to the surgical antiseptic solution. Dexmedetomidine was administered as a loading dose of 1 µg/kg over 10 minutes, followed by a continuous infusion of 0.3-0.7 µg/kg/hour. Under aseptic precautions, ultrasound-guided (linear array transducer (8-14 MHz)) and landmark assisted selective scalp nerve blocks were performed on the operative side. The target nerves and local anaesthetic volumes were as follows.

Supraorbital nerve

The probe was positioned over the medial supraorbital rim to identify the supraorbital foramen as a focal interruption in the bony contour. Under real-time ultrasound guidance, the needle was advanced using an in-plane approach, and 2 ml of local anaesthetic (LA) was deposited in the superficial tissues overlying the foramen to block the supraorbital nerve (Figure 1).

Supratrochlear nerve

Following the supraorbital injection, the needle was redirected medially and superiorly from the supraorbital foramen. A further 2 ml of LA was infiltrated into the subcutaneous plane, with the injection extended towards the midline to achieve blockade of the supratrochlear nerve (Figure 1).

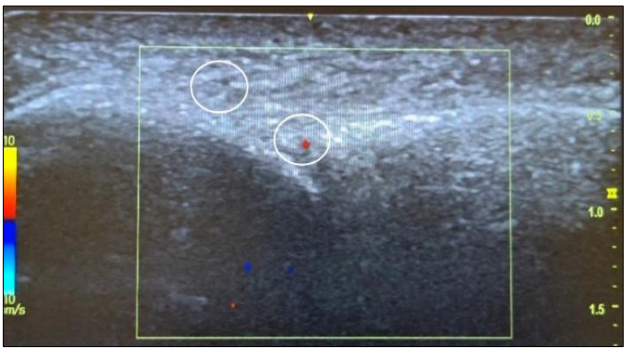

Figure 1: Supraorbital foramen with supraorbital artery and supraorbital nerve, supratrochlear nerve medial to it.

Zygomaticotemporal nerve

The ultrasound probe was placed immediately posterior to the frontal process of the zygomatic bone, allowing identification of the temporal fascia, temporalis muscle, and underlying temporal bone. A two-plane injection technique was used. Initially, the needle tip was positioned adjacent to the temporal bone, and 2.5 ml of LA was injected between the bone and the temporalis muscle. The needle was subsequently withdrawn to the level of the superficial temporal fascia, where an additional 2.5 ml was administered superficial to the fascia (Figure 2).

Auriculotemporal nerve

The transducer was aligned along the surface extending from the lateral canthus of the eye to the tragus. After identifying the superficial temporal artery with ultrasound,

the adjacent auriculotemporal nerve was located. A volume of 2 ml of LA was then injected around the nerve under ultrasound guidance (Figure 3).

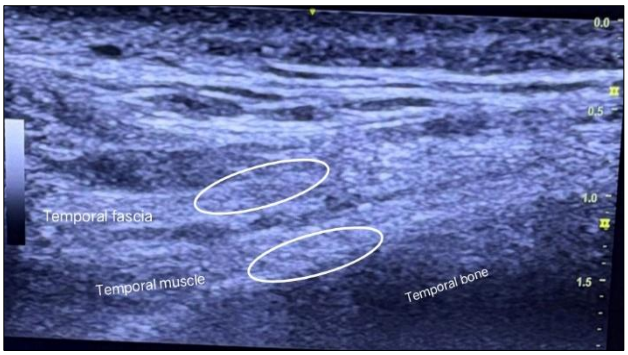

Figure 2: Zygomaticotemporal nerve, probe was placed immediately posterior to the frontal process of the zygomatic bone, allowing identification of the temporal fascia, temporalis muscle, and underlying temporal bone. A two-plane injection technique was used.

Greater auricular and lesser occipital nerves

These nerves were targeted through an ultrasound-guided superficial cervical plexus block. The probe was positioned at the midpoint of the posterior border of the sternocleidomastoid muscle, where the superficial cervical plexus was identified by its characteristic honeycomb-like appearance. A total of 4 ml of LA was deposited around the plexus to provide blockade of the greater auricular and lesser occipital nerves (Figure 4).

Greater occipital nerve

The ultrasound transducer was aligned along the anatomical line connecting the mastoid process and the external occipital protuberance. The occipital artery was identified, and the greater occipital nerve was located in its vicinity. Using an in-plane needle trajectory, 3 ml of LA was deposited around the nerve (Figure 5).

The total volume of local anaesthetic for the scalp block was 20 ml, comprising 10 ml of 2% lignocaine with adrenaline at a concentration of 1:200,000 and 10 ml of 0.5% ropivacaine. A long 26-gauge needle was used for block administration. Local anaesthetic was injected slowly after repeated aspiration to minimize the risk of inadvertent intravascular injection and unintended dural penetration.

During dural manipulation, the patient experienced pain despite the selective scalp nerve blocks which was managed by placing pledgets soaked in lignocaine was applied topically to the corresponding pain-sensitive dural area. Postoperatively, the patient received oral tablet paracetamol 650 mg 8 hourly. After a postoperative non-contrast computed tomography (NCCT) scan, antiplatelet was restarted. Patient was discharged on the fifth postoperative day.

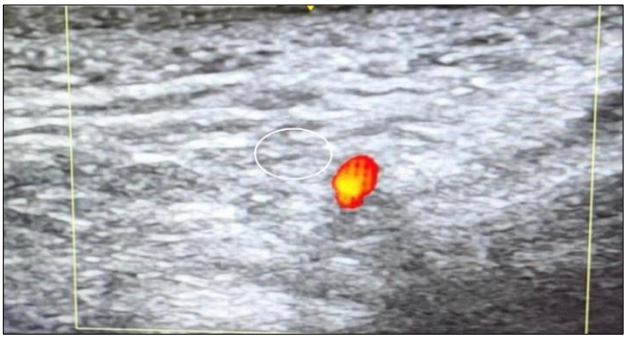

Figure 3: Auriculotemporal nerve, adjacent to superficial temporal artery.



Figure 4: Greater auricular and lesser occipital nerves, midpoint and posterior border of sternocleidomastoid muscle.



Figure 5: The occipital artery was identified, and the greater occipital nerve was located in its vicinity.

DISCUSSION

Severe bronchospasm can complicate airway management and ventilation during general anaesthesia, particularly in patients with poorly controlled asthma.[2] However, awake anaesthesia does not eliminate respiratory or cardiovascular risk, and general anaesthesia is not automatically contraindicated by a previous cardiac arrest. The risks of either technique depend on the underlying cause of the previous events, the current degree of asthma

control, cardiac function, arrhythmia susceptibility, and the patient's physiological status.[3] The anaesthetic technique should therefore be understood as an individualized decision based on risk assessment and shared decision-making.

Scalp nerve blocks are an established component of awake neurosurgical anaesthesia. They provide analgesia by targeting the sensory nerves supplying the scalp and can reduce the requirement for systemic analgesics and sedatives.[4,5] In the present case, selective blocks of the ipsilateral supraorbital, supratrochlear, zygomatico-temporal, auriculotemporal, greater occipital, and lesser occipital nerves were performed. Ultrasound guidance was intended to facilitate targeted injection while accounting for the anticipated adherence of the dura to the tissues around the craniectomy defect and to prevent use of excessive local anaesthetic volume. Nevertheless, scalp nerve blocks do not reliably eliminate pain arising from all pain-sensitive intracranial structures. Manipulation of the dura and meningeal vessels may provoke discomfort despite an apparently adequate scalp block. Additional local anaesthetic measures or carefully titrated systemic analgesia may therefore be required. Dural pain is a recognized challenge during awake neurosurgery, the use of lignocaine-soaked pledgets over the middle meningeal artery to manage discomfort associated with dural manipulation during awake craniotomy.[4]

Dexmedetomidine was used to facilitate cooperative sedation while allowing spontaneous ventilation. Its relatively limited respiratory-depressant effect compared with many conventional sedatives can be advantageous in selected awake neurosurgical procedures. However, dexmedetomidine can cause bradycardia and hypotension, which are important considerations in a patient with coronary artery disease and previous serious perioperative arrhythmias. Continuous cardiovascular and respiratory monitoring, careful titration, and immediate access to airway and resuscitation equipment remain essential.[6]

The principal limitations are the single patient design, the case demonstrates the feasibility of the reported anaesthetic approach in one patient but does not establish comparative safety, superiority over general anaesthesia, or the safety of the reported topical local anaesthetic preparation. In patients with bronchial asthma, inadequate analgesia and anxiety during awake surgery may provoke physiological stress and haemodynamic responses. Although pain is not an established independent predictor of perioperative bronchospasm, minimizing nociceptive stimulation and ensuring adequate regional analgesia are important components of the anaesthetic strategy.[7]

CONCLUSION

Awake cranioplasty using selective scalp nerve blocks with USG guidance, dexmedetomidine sedation, and supplementary topical local anaesthesia may be a feasible alternative in carefully selected patients in whom general anaesthesia presents substantial cardiopulmonary concerns. This case emphasizes individualized anaesthetic planning, effective analgesia, close patient communication, careful assessment of cumulative local anaesthetic doses, and readiness for emergency airway management. Further evidence is required to establish the safety and generalizability of this approach.

Funding: No funding sources
Conflict of interest: None declared
Ethical approval: Not required

REFERENCES

1. Depuru A, Bhatia NS, Bhagat H, Singh A. Awake cranioplasty in a patient with rheumatic heart disease: a novel approach. J Neuroanaesth Crit Care. 2022;9(03):183-5.
2. Bayable SD, Melesse DY, Lema GF, Ahmed SA. Perioperative management of patients with asthma during elective surgery: A systematic review. Ann Med Surg. 2021;70:102874.
3. Thompson A, Fleischmann KE, Smilowitz NR, de Las Fuentes L, Mukherjee D, Aggarwal NR, et al. 2024 AHA/ACC/ACS/ASNC/HRS/SCA/SCCT/SCMR/SVM guideline for perioperative cardiovascular management for noncardiac surgery: a report of the American College of Cardiology/American Heart Association Joint Committee on Clinical Practice Guidelines. Circulation. 2024;150(19):e351-442.
4. Prabhakaran K, Mohan CV, Tripathy PC, Sahoo PK, Mathai KI. Awake craniotomy for tumour excision. Med J Armed Forces India. 2008;64(4):308-10.
5. Fontaine D, Almairac F, Santucci S, Fernandez C, Dallel R, Pallud J, et al. Dural and pial pain-sensitive structures in humans: new inputs from awake craniotomies. Brain. 2018;141(4):1040-8.
6. Goettel N, Bharadwaj S, Venkatraghavan L, Mehta J, Bernstein M, Manninen PH. Dexmedetomidine vs propofol-remifentanil conscious sedation for awake craniotomy: a prospective randomized controlled trial. Br J Anaesth. 2016;116(6):811-21.
7. Woods BD, Sladen R. Perioperative considerations for the patient with asthma and bronchospasm. Br J Anaesth. 2009;103(1):i57-65.

Cite this article as: Ninan MK, Shelley VP, Nair AP. Awake cranioplasty under ultrasonography-guided selective scalp block in a high-risk patient: a case report. Int Surg J 2026;13:2652-5.