International Surgery Journal
Eweida A et al. Int Surg J. 2026 Dec;13(12):2467-2473
https://www.ijsurgery.com
pISSN 2349-3305 | eISSN 2349-2902

DOI: https://dx.doi.org/10.18203/2349-2902.isj20264352

Original Research Article

Intraoperative exploration of central lymph node compartment predicts occult metastasis in patients with Bethesda V thyroid nodules

Ahmad Eweida[1,2]*, Mohamed Ellboudy[1], Ahmed Elsherif[1], Marwa Abd El Aziz[3], Ahmed Saleh[1], Ayman Nabawi[1], Tarek Koraitim[1]

[1]Head, Neck and Endocrine Surgery Unit (HNESU), Department of Surgery, Faculty of Medicine, University of Alexandria, Egypt
[2]Department of Plastic and Reconstructive Surgery, University of Heidelberg, Germany
[3]Department of Pathology, Faculty of Medicine, University of Alexandria, Egypt

Received: 20 October 2026
Accepted: 16 November 2026

***Correspondence:**
Dr. Ahmad Eweida,
E-mail: ahamd.eweida@alexmed.edu.eg

Copyright: © the author(s), publisher and licensee Medip Academy. This is an open-access article distributed under the terms of the Creative Commons Attribution Non-Commercial License, which permits unrestricted non-commercial use, distribution, and reproduction in any medium, provided the original work is properly cited.

ABSTRACT

Background: Occult central lymph node metastasis (OCLNM) in papillary thyroid cancer is a suggested prognostic factor for locoregional recurrence. We investigated the incidence and possible predictive indicators of OCLNM in patients with Bethesda V (BV) thyroid nodules.
Methods: This study included 50 consecutive patients with BV nodules with negative neck nodes. All patients received total thyroidectomy and prophylactic ipsilateral central neck dissection (pCND). The final histopathological results were analysed in relation to the patients' various demographic, preoperative and intraoperative data.
Results: Forty-three patients met the inclusion criteria. Malignancy was detected in 35 (81.4%) of the 43 Bethesda V patients. OCLNM was detected in 19 patients (44.2%). All male patients (n=5) had OCLNM. Univariate analysis showed that OCLNM was significantly related to the presence of a neck swelling (p=0.032), preoperative compression manifestations (p=0.003), TIRADS 5 score (p=0.013), intraoperative LNs >1cm (p=0.003), and the number of retrieved LNs (p=0.035). Multivariate regression analysis showed that intraoperative LN enlargement >1cm (p=0.03) independently predicted OCLNM.
Conclusion: The incidence of ipsilateral OCLNM in BV patients is independently related to the presence of intraoperative LN enlargement >1cm in the central compartment. We recommend opening the paratracheal fascia to explore the central compartment for LN enlargement in BV patients. Ipsilateral pCND should be considered in such cases after assessment of the patient's individual risk-benefit profile.

Keywords: Bethesda V, Central lymph nodes, Papillary thyroid carcinoma, Prophylactic neck dissection

INTRODUCTION

Papillary thyroid carcinoma (PTC) is by far the most common pathological type of thyroid cancer.[1,2] Despite being mostly not aggressive with an excellent prognosis, avoiding local recurrence is of outmost importance to maintain a disease-free period and maintain good quality of life.

Preoperative histopathological evaluation of suspicious thyroid nodules using fine needle aspiration cytology (FNAC) and reporting using the Bethesda system is the standard practice in many institutions and is recommended by the American thyroid association (ATA).[3] The Bethesda category V (BV) represents a high suspicion for malignancy up to 83%.[4]

One of the suggested risk factors for local recurrence is the presence of occult central lymph node metastasis (OCLNM). This was reported in up to 61% of clinically and radiologically node negative patients (cN0 PTC).[5] Performing an ipsilateral prophylactic central neck dissection (pCND) with total thyroidectomy is widely accepted in high risk and selected cN0 PTC patients with added benefits regarding decreasing local recurrence, helping precise staging, directing adjuvant therapy and early decreasing thyroglobulin levels.[6–10] Plenty of studies investigated the predictors of OCLNM in cN0 PTC patients and the benefit of performing a prophylactic CND.[11] However, the literature lacks strong evidence regarding OCLNM in patients with a preoperative diagnosis of BV thyroid nodules and the probable benefit of performing prophylactic CND in this group of patients. We present a prospective study aiming to detect the probable predictors of OCLNM in patients with BV thyroid nodules.

METHODS

Study design

This prospective study included 50 consecutive patients with a preoperative diagnosis of BV nodules [4] via ultrasound-guided FNAC from the dominant suspicious nodule according to TIRADS classification.[12] Exclusion criteria included the presence of clinical or radiological evidence of metastatic lymph nodes or the presence of a concomitant parathyroid pathology. All procedures were performed in compliance with relevant laws and institutional guidelines and have been approved by the appropriate institutional committees. The work described has been carried out in accordance with the code of ethics of the World Medical Association (Declaration of Helsinki) for experiments involving humans and was approved by the institutional ethical committee (No. 0108934/2025). The study is registered in the Pan African Clinical Trials Registry (PACTR202604584570832).

Preoperative assessment

A detailed history taking and clinical examination were performed including an indirect laryngoscopy for the assessment of vocal cord mobility. All patients received a sonographic examination via an experienced neck radiologist using high-resolution US equipment and a high-frequency linear transducer (10–15 MHz).

Surgery and postoperative care

All included patients received a total thyroidectomy by an experienced head and neck surgeon (> 100 thyroidectomies/year) under general anaesthesia. After excision of the thyroid gland, an ipsilateral central lymph node dissection was performed by the same surgeon including prelaryngeal, pretracheal and paratracheal LNs (levels VI and VII) in all patients (Figure 1). An intraoperative clinical assessment of the lymph node status was done by the operating surgeon before performing the central neck dissection. This was documented intraoperatively as ‘’CLN enlargement’’ in case of the presence of at least one enlarged LN >1cm. The thyroid gland and CLN specimens were sent for standard postoperative histopathological evaluation. The patients received the standard postoperative care and were discharged on the 2nd postoperative day. All patients were followed up for at least 1 year regarding the occurrence of recurrent laryngeal nerve (RLN) injury or hypoparathyroidism. Patients with histopathologically documented PTC in the thyroid gland received adjuvant radioactive iodine (RAI) therapy if indicated according to NCCN guidelines.[13] All patients with positive CLN involvement received a dose of 100mCi adjuvant RAI therapy. Following RAI ablation, L-thyroxine suppressive therapy was initiated to maintain thyroid-stimulating hormone (TSH) levels below 0.1 mIU/l.

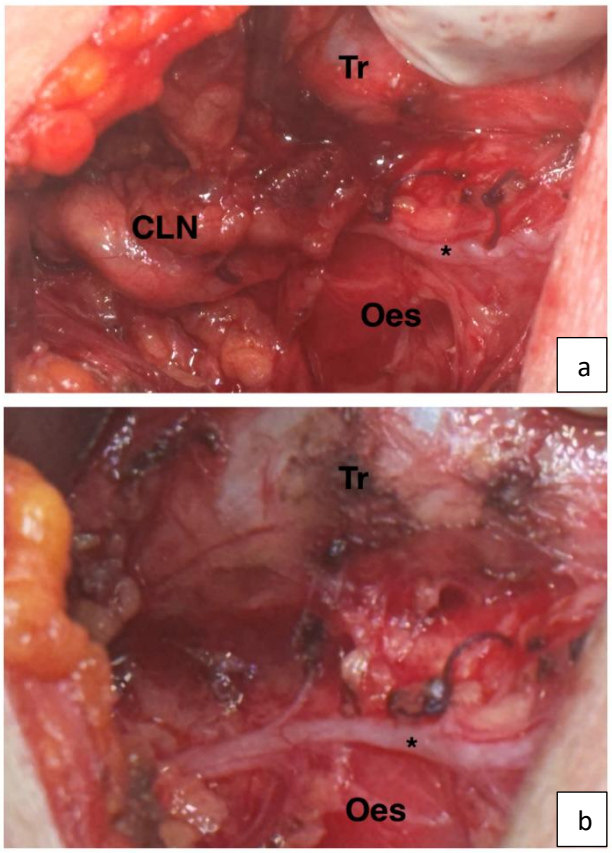

Figure 1 (a and b): Intraoperative photo for left central LN dissection showing the surgical access to the LNs medial to the RLN.

Above: during LN dissection. below: after removal of LNs. Asterisk: left RLN, Tr: trachea, Oes: oesophagus, CLN: central lymph nodes

Statistics

According the histopathological involvement of the CLN by tumour cells, the patients were classified into two groups; either CLN positive or CLN negative. The two

groups were compared according to various criteria including: age, sex, presenting complaints, size and TIRADS degree of the dominant nodule, intraoperative CLN enlargement, number of involved/excised LNs and histopathological tumour characteristics. In order to specifically address the aim of this study, the statistical analysis was intentionally performed using all Bethesda V patients as the main pool (denominator) and not only the documented PTC cases in the final pathology.

Data was analysed using IBM SPSS software (version 20.0., Armonk, NY: IBM Corp, released 2011). Qualitative data were described using number and percent. The Shapiro-Wilk test was used to verify the normality of distribution. Quantitative data were described using range (minimum and maximum), mean, standard deviation, median and interquartile range (IQR). Significance of the obtained results was judged at the 5% level. Chi-square test was performed for comparison between categorical variables. Student *t*-test was used to compare normally distributed quantitative variables and Mann Whitney test for non-normally distributed quantitative variables. Univariant and multivariant regression analyses were performed to detect independent predictors of CLN involvement in all patients with BV nodules.

RESULTS

Forty-three Patients met the inclusion criteria and received total thyroidectomy and prophylactic ipsilateral central lymph node dissection. The final histopathological results revealed malignancy in 35 (81.4%) of the 43 BV patients. Thirty-one patients had a conventional PTC (Figure 2a), three patients had a follicular variant of PTC and one patient had a cribriform morular thyroid carcinoma. OCLNM was detected in 19 patients (44.2%) of the 43 BV patients (Figure 2b). Average number of removed LNs was 5.81±4.46 (ranging from 0-19 LNs). In the CLN positive group, the average ratio of involved/removed LNs was 0.57±0.3.

All male patients in the study (n=5) had OCLNM. No, statistically significant age difference was detected between both groups. Regarding the preoperative presentation, univariate analysis showed that OCLNM was significantly related to the presence of preoperative compression manifestations (p=0.003) and the presence of a preoperative complaint of a neck swelling (p=0.032). Negative lymph nodes were significantly related to an accidental discovery of thyroid nodules during ultrasound examination. OCLNM was also related to the size of the dominant thyroid nodule (p=0.042) and to a high TIRADS score (p=0.04), especially to TIRADS 5 score (p=0.01).

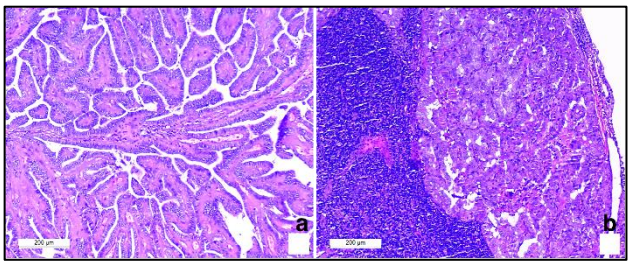

Figure 2: a) Hematoxylin and Eosin (HE) section of conventional PTC showing branching papillary structures lined by columnar cells showing oval optically clear nuclei with nuclear overlapping and grooving; b) HE Section in a central LN showing metastatic deposits of conventional PTC.

Table 1: Incidence of OCLNM in relation to different parameters including univariate and multivariate regression analysis

Parameter	Central lymph node involvement			Univariate regression			Multivariate regression	
	Total (n=43)	+ve (n=19)	-ve (n=24)	P	P	OR (95%CI)	P	OR (95%CI)
Age (years)	38.74±11.03	37.05±10.46	40.08±11.50	0.377	N/A	N/A	N/A	N/A
Sex								
Male	5	5	0	0.012*	N/A	N/A	N/A	N/A
Female	38	14	24					
Patient's complaint								
Swelling	26	15	11	0.032*	0.032*	4.432 (1.133 – 17.341)	0.306	4.950 (0.231 – 106.092)
Compression	16	12	4	0.003*	0.003*	8.571 (2.068 – 35.523)	0.065	0.043 (0.001 – 1.220)
Voice changes	3	2	1	0.432	N/A	N/A	N/A	N/A
Hyperthyroidism	2	1	1	0.866	N/A	N/A	N/A	N/A
Accidental	13	2	11	0.021*	0.021*	0.139	Neglected	

Continued.

Parameter	Central lymph node involvement			Univariate regression			Multivariate regression	
	Total (n=43)	+ve (n=19)	-ve (n=24)	P	P	OR (95%CI)	P	OR (95%CI)
						(0.026 – 0.739)	due to multi-collinearity with Swelling (r >0.7)	
Imaging								
Size of dominant nodule (mm)	22.69±12.19	26.95±12.58	19.31±10.98	0.042*	0.052	1.059 (0.999 – 1.122)	N/A	N/A
TIRADS (grade 5)	20	13	7	0.01*	0.013*	5.262 (1.423 – 19.460)	0.168	3.282 (0.606 – 17.789)
Intraoperative CLN enlargement >1cm								
Yes	18	13	5	0.003*	0.003*	8.233 (2.070 – 32.748)	0.030*	32.735 (1.392 – 769.831)
No	25	6	19					
Pathology thyroid extra-nodular involvement								
Yes	8	8	0	0.004*	N/A	N/A	N/A	N/A
No	27	11	16					
Number of retrieved lymph node	5.81±4.46	7.53±4.53	4.46±3.99	0.018*	0.035*	1.193 (1.012 – 1.405)	0.350	0.871 (0.651 – 1.164)

*Statistically significant

All male patients in the study (n=5) had OCLNM. No, statistically significant age difference was detected between both groups. Regarding the preoperative presentation, univariate analysis showed that OCLNM was significantly related to the presence of preoperative compression manifestations (p=0.003) and the presence of a preoperative complaint of a neck swelling (p=0.032). Negative lymph nodes were significantly related to an accidental discovery of thyroid nodules during ultrasound examination. OCLNM was also related to the size of the dominant thyroid nodule (p=0.042) and to a high TIRADS score (p=0.04), especially to TIRADS 5 score (p=0.01).

Intraoperatively, the presence of CLN enlargement >1cm as clinically judged by the operating surgeon was significantly related to the OCLNM (p=0.003).

Regarding the final pathological assessment, the presence of OCLNM was significantly related to the number of retrieved LNs (p=0.018) and to the presence of extra-nodular extension of the tumour within the thyroid gland (p=0.004). All patients with OCLNM were associated with the conventional type of PTC.

The multivariate regression analysis showed that the presence of intraoperative LN enlargement >1cm was the only independent factor predicting OCLNM (p=0.03). (Table 1).

The postoperative follow-up of the patients revealed one case of upper-airway oedema which was treated conservatively via anti-inflammatory and short-term steroid therapy. Transient RLN injury occurred in two patients, transient subclinical hypocalcaemia occurred in four patients. No permanent RLN injury or permanent hypoparathyroidism were documented after 6 months of follow up. No recurrence occurred within a minimal follow up period of 1 year.

DISCUSSION

Despite its excellent prognosis, the main risk of papillary thyroid cancer is that of local recurrence, which sometimes necessitates repeated surgical interventions or repeated RAI- therapy. One of the main causes of local recurrence is the presence of occult metastases in the central group of LNs during total thyroidectomy especially if those patients do not receive adjuvant RAI ablation.

Preoperative sonographic detection of CLNM has obvious limitations due to anatomical and radiological factors related to the central area, with a sensitivity of as low as 33%.[14–16] That is why, it is not uncommon to have an undiagnosed OCLNM in a plenty of patients with BV nodules scheduled for total thyroidectomy.

The presence of OCLNM in PTC was reported to be about 41% [17] reaching up to 61% with larger tumours.[5]

Nevertheless, the actual benefit of performing an ipsilateral prophylactic CND (pCND) in patients with PTC, cN0 is still controversial. In a meta-analysis including 18,376 patients comparing total thyroidectomy versus total thyroidectomy with pCND; patients who underwent pCND had a significantly lower locoregional recurrence.[9] Another meta-analysis including 1740 patients showed a lower recurrence rate in the total thyroidectomy plus pCND arm, however this did not reach statistical significance.[18] Another multicentre study including 211 consecutive patients concluded that a ratio of the number of malignant lymph nodes to the total number of excised lymph nodes (malignant/retrieved) that equals or exceeds 0.26, is an independent predictor of regional lymph node recurrence.[17] Based on other RCTs,[19–21] the recent NCCN guidelines do not recommend a prophylactic CND in most cases of cN0 PTC as the detected OCLNM will probably not impact the outcome of the disease.[13] The most recent ATA guidelines,[3] however, recommend considering pCND in cN0 PTC patients who have T3 or T4 tumours or for whom the OCLNM will be used to plan further steps in therapy. In many institutes following the NCCN guidelines, OCLNM will lead to considering an adjuvant RAI ablation and thus will have an impact on further steps in therapy. A larger prospective randomized study is currently ongoing to detect the effect of pCND on the outcome of BVI and BV patients proven to be malignant intraoperatively by frozen section.[22]

Up till now there are no clear guidelines or recommendations to perform pCND in cases of BV nodules. Several studies analysed the predictors of OCLNM in PTC especially preoperatively, such as extremes of age, male gender, large primary tumours, or the presence of bilateral disease. Regarding patients with BV nodules, there are no enough studies about the incidence or predictors of OCLNM in such cases. With up to 83% of such cases turning to be PTC in the final pathology, it is worth to look for any pre- or intraoperative predictors of OCLNM in such cases to be able to perform a pCND during the total thyroidectomy and thus decrease the possible risk of local recurrence.

To the best of our knowledge, the current study represents the largest prospective study on pCND in patients with BV nodules. Hargitai et al performed pCND in patients with BIV & V nodules and found that 15 out of 21 patients with BV nodules (71.4%) were finally diagnosed as PTC, of whom seven (33.3%) patients had OCLNM.[23] In our series, the final histopathological results revealed malignancy in 35 patients (81.4%) and OCLNM was detected in 44.2% of all BV patients (54.3% of the malignant cases). This relatively high incidence together with a high malignant/retrieved LN ratio of 0.57 highlight the importance of considering an ipsilateral prophylactic CND in selected BV patients.

In order to predict OCLNM in BV patients, we studied various preoperative and intraoperative factors. The initial statistical analysis showed that OCLNM was significantly related to the patients' complaint of a neck swelling or neck compression. Also, larger nodules were significantly related to OCLNM. These findings match the results of other studies on PTC suggesting that the size of the malignant nodule could be a risk for OCLNM. [5] Similarly, the recent ATA consensus recommended performing an ipsilateral prophylactic CND in selected patients with PTC cN0 who have larger primary tumours (T3 or T4).[3]

Regarding preoperative imaging, our results showed that a high TIRADS score, especially TIRADS 5 was significantly associated with OCLNM in BV patients. Several retrospective studies showed a strong association between the presence of OCLNM in PTC and a high TIRADS score or suspicious sonographic features of nodules such as microcalcification.[24]

An increase in lymph node size is a well-known criterion for suspecting metastasis, with 1 cm as a traditional cut off size.[25] This study showed that the presence of LN enlargement >1cm during an intraoperative assessment of the central compartment after performing total thyroidectomy is significantly associated with OCLNM. Also, a larger yield of LNs in the final pathology was associated with OCLNM. The multivariate regression analysis showed that the presence of intraoperative LN enlargement, as assessed by the operating surgeon after performing total thyroidectomy, was the only independent factor associated with positive OCLNM in BV patients. Sun et al previously investigated the intraoperative clinicopathological evaluation of LNs done by the operating surgeon in 1271 PTC patients and similarly found that larger central LNs (>0.9 cm), extracapsular infiltration, adhesion and fusion were independent prognostic factors for OCLNM.[26] For an adequate intraoperative assessment of the LNs in the central compartment, the ipsilateral paratracheal fascia should be intentionally opened by the operating surgeon. Accordingly, we recommend the exploration of the central LN compartment via opening the paratracheal fascia in BV patients to perform a routine intraoperative assessment of the central group. If this intraoperative assessment reveals enlarged LNs not previously detected by US, a unilateral pCND should be considered.

Another approach to detect OCLNM is the intraoperative assessment of sentinel LNs using a frozen section. Many studies showed the feasibility of the technique either using methylene blue or other radioactive isotopes or nanoparticles. The limitation of this technique remains a low sensitivity with relatively high false negative rates.[27–29]

Other recently studied factors were suggested to predict tumour aggressiveness and consequently the need for pCND. Schumm et al. studied the molecular alterations in

BV and BVI nodules in 105 consecutive patients using ThyroSeq Cancer Risk Classifier. Their results showed that high-risk molecular profiles were more likely to experience cancer persistence or recurrence and distance metastases.[30] Unfortunately, molecular testing is highly expensive and could not be routinely applied in low-income countries.

It is well known that CND is associated with increased surgical morbidity related to RLN injury and hypoparathyroidism. However, meta-analytic studies showed that these effects are mostly temporary and neither significant increase in permanent RLN injury nor permanent hypoparathyroidism was associated with CND. Transient RLN injury and transient hypoparathyroidism in the current study are comparable to their incidence after total thyroidectomy in our institutional records. None of our patients experienced permanent RLN injury or permanent hypoparathyroidism. This is probably attributed to a conservative technique adopted in dissecting only the ipsilateral central compartment. Our technique includes the dissection of prelaryngeal, pretracheal and paratracheal LNs. However, during dissection of the paratracheal group, the paratracheal fascia is opened only medial to the RLN along its course from the larynx to the upper mediastinum (Figure 1). Through this medial access, we can deliver most of the paratracheal lymph nodes without the need to skeletonize the nerve circumferentially. The technique of skeletonising the RLN circumferentially, especially from its lateral side may increase the risk of injury of the RLN and jeopardizes the blood supply of the parathyroid glands, and that's why it is not classically adopted in our institution.[31]

Detecting OCLNM after a prophylactic CND may change the decision towards an adjuvant RAI therapy. According to recent NCCN guidelines, the presence of millimetric central node metastasis could be the sole criterion to consider an adjuvant RAI therapy.[13] In the 8th edition of American Joint Committee on Cancer (AJCC) in patients older than 55 years, positive nodal status upstages small intrathyroidal tumours (<4 cm) from I to II.[32] In our presented series of patients, the decision of receiving RAI ablation was based on the criteria of the primary thyroid tumour in all cases except one patient, who received RAI ablation based on the presence of OCLNM.

In spite of being a single centre study, this prospective study highlights the role of intraoperative assessment of the ipsilateral central compartment as a predictor for OCLNM in patients with BV nodules. We recommend considering at least an intraoperative assessment of the ipsilateral central compartment via opening the paratracheal fascia in every case of BV nodules to search for enlarged LNs. Detected OCLNM after pCND in selected patients could prevent under-staging and may help adequate management including radioactive iodine therapy and/ or long term TSH suppression.

CONCLUSIONS

The incidence of ipsilateral OCLNM in BV patients is independently related to the presence of intraoperative LN enlargement >1cm in the central compartment. We recommend an ipsilateral exploration of the central compartment via opening the ipsilateral paratracheal fascia in all patients with BV nodules to search for enlarged LNs. Ipsilateral pCND should be considered in case of intraoperative LN enlargement >1cm after assessment of the patient's individual risk-benefit profile

Funding: No funding sources
Conflict of interest: None declared
Ethical approval: Ethical approval by the institutional ethical committee (No. 0108934/2025). The study is registered in the Pan African Clinical Trials Registry (PACTR202604584570832).

REFERENCES

1. Miranda-Filho A, Lortet-Tieulent J, Bray F, Cao B, Franceschi S, Vaccarella S, et al. Thyroid cancer incidence trends by histology in 25 countries: a population-based study. Lancet Diabetes Endocrinol. 2021;9(4):225-34.
2. Bray F, Laversanne M, Sung H, Ferlay J, Siegel RL, Soerjomataram I, et al. Global cancer statistics 2022: GLOBOCAN estimates of incidence and mortality worldwide for 36 cancers in 185 countries. CA Cancer J Clin. 2024;74(3):229-63.
3. Ringel MD, Sosa JA, Baloch Z, Bischoff L, Bloom G, Brent GA, et al. 2025 American Thyroid Association management guidelines for adult patients with differentiated thyroid cancer. Thyroid. 2025;35(8):841-985.
4. Ali SZ, Baloch ZW, Cochand-Priollet B, Schmitt FC, Vielh P, VanderLaan PA. The 2023 Bethesda System for Reporting Thyroid Cytopathology. Thyroid. 2023.
5. Tang L, Qu RW, Park J, Simental AA, Inman JC. Prevalence of occult central lymph node metastasis by tumor size in papillary thyroid carcinoma: a systematic review and meta-analysis. Curr Oncol. 2023;30(8):7335-50.
6. White ML, Gauger PG, Doherty GM. Central lymph node dissection in differentiated thyroid cancer. World J Surg. 2007;31(5):895-904.
7. Pereira JA, Jimeno J, Miquel J, Iglesias M, Munné A, Sancho JJ, et al. Nodal yield, morbidity, and recurrence after central neck dissection for papillary thyroid carcinoma. Surgery. 2005;138(6):1095-101.
8. Hartl DM, Mamelle E, Borget I, Leboulleux S, Mirghani H, Schlumberger M. Influence of prophylactic neck dissection on rate of retreatment for papillary thyroid carcinoma. World J Surg. 2013;37(8):1951-8.
9. Chen L, Wu Y, Lee C, Chen H, Loh E, Tam K. Prophylactic central neck dissection for papillary thyroid carcinoma with clinically uninvolved central neck lymph nodes: a systematic review and meta-analysis. World J Surg. 2018;42(9):2846-57.

10. Lang BH-H, Wong KP, Wan KY, Lo CY. Impact of routine unilateral central neck dissection on preablative and postablative stimulated thyroglobulin levels after total thyroidectomy in papillary thyroid carcinoma. Ann Surg Oncol. 2012;19(1):60-7.
11. Shirley LA, Jones NB, Phay JE. The role of central neck lymph node dissection in the management of papillary thyroid cancer. Front Oncol. 2017;7:122.
12. Tessler FN, Middleton WD, Grant EG, Hoang JK, Berland LL, Teefey SA, et al. ACR thyroid imaging, reporting and data system (TI-RADS): white paper of the ACR TI-RADS Committee. J Am Coll Radiol. 2017;14(5):587-95.
13. Haddad RI, Bischoff L, Applewhite M, Bernet V, Blomain E, Brito M, et al. NCCN Guidelines Insights: thyroid carcinoma, version 1.2025: featured updates to the NCCN Guidelines. J Natl Compr Canc Netw. 2025;23(7):e250033.
14. Hwang HS, Orloff LA. Efficacy of preoperative neck ultrasound in the detection of cervical lymph node metastasis from thyroid cancer. Laryngoscope. 2011;121(3):487-91. doi:10.1002/lary.21227.
15. Peng X, Zhang J, Lin Y, Li R. Predicting central lymph node metastasis in papillary thyroid microcarcinoma: a study of ultrasound and clinical features. Front Endocrinol (Lausanne). 2026;17:1752405.
16. Zhao H, Li H. Meta-analysis of ultrasound for cervical lymph nodes in papillary thyroid cancer: diagnosis of central and lateral compartment nodal metastases. Eur J Radiol. 2019;112:14-21.
17. Lee YC, Na SY, Park GC, Han JH, Kim SW, Eun YG. Occult lymph node metastasis and risk of regional recurrence in papillary thyroid cancer after bilateral prophylactic central neck dissection: a multi-institutional study. Surgery. 2017;161(2):465-71.
18. Wang TS, Cheung K, Farrokhyar F, Roman SA, Sosa JA. A meta-analysis of the effect of prophylactic central compartment neck dissection on locoregional recurrence rates in patients with papillary thyroid cancer. Ann Surg Oncol. 2013;20(11):3477-83.
19. Viola D, Materazzi G, Valerio L, Molinaro E, Agate L, Faviana P, et al. Prophylactic central compartment lymph node dissection in papillary thyroid carcinoma: clinical implications derived from the first prospective randomized controlled single institution study. J Clin Endocrinol Metab. 2015;100(4):1316-24.
20. Sippel RS, Robbins SE, Poehls JL, Pitt SC, Chen H, Leverson G, et al. A randomized controlled clinical trial: no clear benefit to prophylactic central neck dissection in patients with clinically node negative papillary thyroid cancer. Ann Surg. 2020;272(3):496-503.
21. Ahn JH, Kwak JH, Yoon SG, Yi JW, Yu HW, Kwon H, et al. A prospective randomized controlled trial to assess the efficacy and safety of prophylactic central compartment lymph node dissection in papillary thyroid carcinoma. Surgery. 2022;171(1):182-9.
22. Hartl D, Godbert Y, Carrat X, Bardet S, Lasne-Cardon A, Vera P, et al. ESTIMation of the ABiLity of Prophylactic Central Compartment Neck Dissection to Modify Outcomes in Low-Risk Differentiated Thyroid Cancer: a prospective randomized trial. Trials. 2023;24(1):298.
23. Hargitai L, Strobl S, Koperek O, Urach S, Raber W, Staudenherz A, et al. Positive central lymph-nodes are underdiagnosed in patients with Bethesda V cytology in an endemic goiter region. Gland Surg. 2020;9(2):252-60.
24. Al-Essa M. Tumor size, TIRADS, and lymph node status as predictors of central neck dissection in thyroid cancer. Pan Afr Med J. 2025;52:39.
25. Castelijns JA, van den Brekel MWM. Detection of lymph node metastases in the neck: radiologic criteria. AJNR Am J Neuroradiol. 2001;22(1):3-4.
26. Sun RH, Li C, Zhou YQ, Cai YC, Shui CY, Liu W, et al. Predictive role of intraoperative clinicopathological features of the central compartment in estimating lymph nodes metastasis status. Ann Transl Med. 2019;7(18):471.
27. Yan X, Zeng R, Ma Z, Chen C, Chen E, Zhang X, et al. The utility of sentinel lymph node biopsy in papillary thyroid carcinoma with occult lymph nodes. PLoS One. 2015;10(6):e0129304.
28. Roh J, Park CI. Sentinel lymph node biopsy as guidance for central neck dissection in patients with papillary thyroid carcinoma. Cancer. 2008;113(7):1527-31.
29. Boschin IM, Bertazza L, Scaroni C, Mian C, Pelizzo MR. Sentinel lymph node mapping: current applications and future perspectives in thyroid carcinoma. Front Med (Lausanne). 2023;10:1231566.
30. Schumm MA, Shu ML, Hughes EG, Nikiforov YE, Nikiforova MN, Wald AI, et al. Prognostic value of preoperative molecular testing and implications for initial surgical management in thyroid nodules harboring suspected (Bethesda V) or known (Bethesda VI) papillary thyroid cancer. JAMA Otolaryngol Head Neck Surg. 2023;149(8):735.
31. Ferlito A, Rinaldo A, Silver CE, Shaha AR, Fliss DM, Rodrigo JP, et al. Paratracheal node dissection for well-differentiated cancer of the thyroid: indications, technique and results. Auris Nasus Larynx. 2008;35(4):463-8.
32. Amin MB, Edge SB, Greene FL, Byrd DR, Brook RK, Washington MK, et al. AJCC Cancer Staging Manual. 8th ed. New York: Springer International Publishing; 2017.

Cite this article as: Eweida A, Ellboudy M, Elsherif A, Abd ElAziz M, Saleh A, Nabawi A, et al. Intraoperative exploration of central lymph node compartment predicts occult metastasis in patients with Bethesda V thyroid nodules. Int Surg J 2026;13:2467-73.