International Surgery Journal
Kumar R et al. Int Surg J. 2026 Dec;13(12):2647-2651
https://www.ijsurgery.com
pISSN 2349-3305 | eISSN 2349-2902

DOI: https://dx.doi.org/10.18203/2349-2902.isj20264380

Case Report

A diagnostic chameleon in the visceral mediastinum: a case report of cystic schwannoma resembling an esophageal/bronchogenic duplication cyst

Rahul Kumar*, Shadan Ali, Sahil Thakur, Shatakshi Dutt, Anirudh Tanwar

Department of General Surgery, Lady Hardinge Medical College, New Delhi, India

Received: 21 October 2026
Accepted: 16 November 2026

***Correspondence:**
Dr. Rahul Kumar,
E-mail: rahulkaloyia12@gmail.com

Copyright: © the author(s), publisher and licensee Medip Academy. This is an open-access article distributed under the terms of the Creative Commons Attribution Non-Commercial License, which permits unrestricted non-commercial use, distribution, and reproduction in any medium, provided the original work is properly cited.

ABSTRACT

Mediastinal schwannomas are benign nerve sheath tumors that usually arise in the posterior mediastinum, and cystic degeneration can make them radiologically indistinguishable from congenital foregut cysts. We report a 40-year-old woman who presented with gradually progressive chest fullness and occasional episodes of anterior chest pain. Chest radiography showed right paratracheal widening, and a barium swallow demonstrated smooth extrinsic narrowing of the mid-thoracic esophagus. Contrast-enhanced computed tomography (CECT) of the neck and chest revealed a well-defined hypodense lesion of approximately 5.3×5.5×6.3 cm in the visceral mediastinum, displacing the trachea and esophagus and stretching the azygos vein. Magnetic resonance imaging (MRI) showed a lobulated, multiloculated, peripherally enhancing cystic lesion of approximately 5.4×5.1×7.6 cm with internal septations, hyperintense on T2-weighted and hypointense on T1-weighted images. The differential diagnoses were cystic schwannoma, foregut duplication cyst and hydatid cyst. The patient underwent video-assisted thoracoscopic surgery (VATS), and the lesion, closely related to the azygos vein, superior vena cava, esophagus and trachea, was excised completely without vascular injury or air leak. Histopathology confirmed a cystic schwannoma with Antoni A and Antoni B areas, and immunohistochemistry showed SOX10 and S100 positivity with a Ki-67 index of approximately 5%, supporting a benign tumor. The postoperative course was uneventful, and the intercostal drain was removed on the third postoperative day. Cystic schwannoma should be included in the differential diagnosis of mediastinal cystic lesions, and definitive diagnosis rests on histopathology and immunohistochemistry.

Keywords: Neurilemmoma, Mediastinal neoplasms, Bronchogenic cyst, Video-assisted thoracic surgery, Immunohistochemistry

INTRODUCTION

Neurogenic tumors account for about 12% to 39% of all mediastinal tumors, and schwannomas form the large majority of these.[1,2] Most mediastinal schwannomas arise from the intercostal nerves or spinal nerve roots in the posterior mediastinum; less commonly, they arise from the vagus or phrenic nerve in the middle (visceral) mediastinum.[3] Although schwannomas are usually solid, they may undergo degenerative changes such as cystic necrosis, hemorrhage and hyalinization, resulting in a cystic schwannoma.[1] These lesions can closely mimic congenital cysts, such as bronchogenic or esophageal duplication cysts, on cross-sectional imaging.[1,3] We report a cystic schwannoma of the visceral mediastinum that resembled a foregut duplication cyst on imaging and was excised by video-assisted thoracoscopic surgery (VATS).

CASE REPORT

History

A 40-year-old woman presented to the surgery outpatient department with fullness and pressure in the chest of 3 months' duration. The symptoms were insidious in onset, gradually progressive and aggravated by activity. She also had occasional episodes of anterior chest pain lasting 2 to 3 minutes, without radiation, sweating or palpitations. She reported occasional dyspnea but no dysphagia.

Examination

The patient was conscious and oriented. Her blood pressure was 120/82 mmHg, pulse rate 82 beats/min, respiratory rate 18 breaths/min and oxygen saturation 99% on room air. Systemic examination, including the cardiovascular and respiratory systems, was unremarkable.

Investigations

Chest radiography showed right paratracheal widening with a soft-tissue opacity in the superior mediastinum (Figure 1). A barium swallow revealed smooth extrinsic narrowing along the right lateral aspect of the mid-thoracic esophagus at the level of the paratracheal opacity, with mild contrast hold-up, consistent with extrinsic compression by a mediastinal mass.

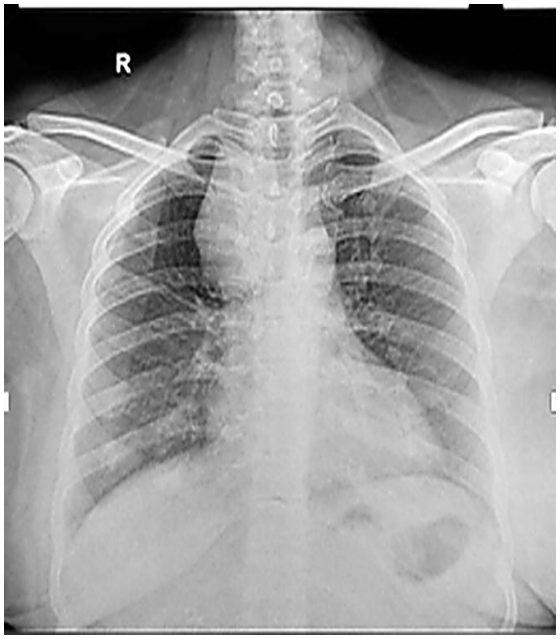

Figure 1: Chest radiograph showing right paratracheal widening with a soft-tissue opacity in the superior mediastinum.

CECT of the neck and chest revealed a well-defined hypodense lesion with no internal enhancement, measuring approximately 5.3×5.5×6.3 cm, in the visceral compartment of the mediastinum. It caused mass effect with displacement of the trachea and esophagus to the left, stretching of the azygos vein and anterior displacement of the superior vena cava (Figure 2).

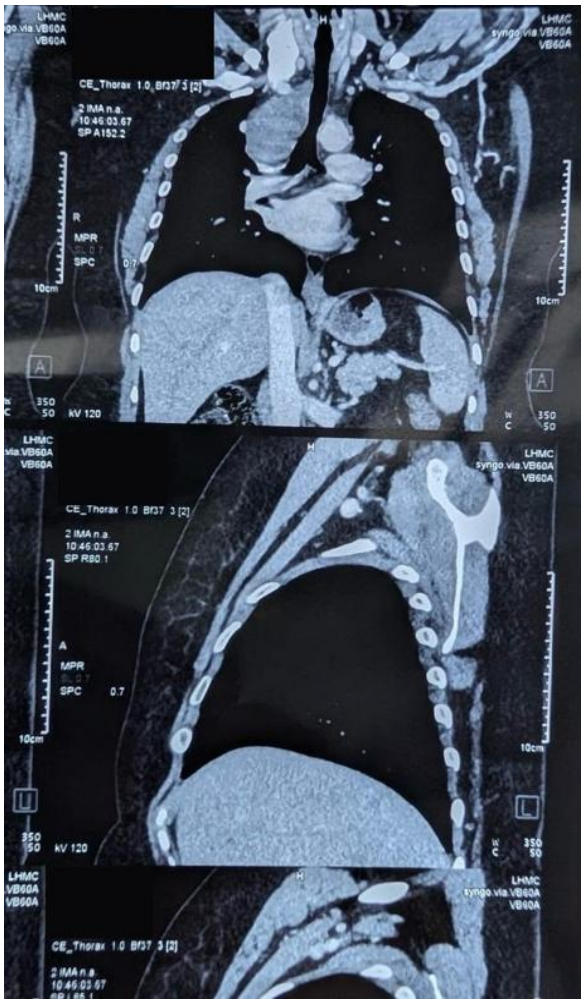

Figure 2: Contrast-enhanced computed tomography of the chest (coronal and sagittal reformatted images) showing a well-defined hypodense lesion in the visceral mediastinum.

Contrast-enhanced MRI of the thorax showed a well-defined, lobulated, multiloculated, peripherally enhancing cystic lesion of approximately 5.4×5.1×7.6 cm centered in the visceral mediastinum. The lesion was hyperintense on T2-weighted and short tau inversion recovery (STIR) images and hypointense on fat-suppressed T1-weighted images, with internal septations (Figure 3). The differential diagnoses considered were cystic schwannoma, foregut duplication cyst and mediastinal hydatid cyst. Echocardiography showed normal cardiac chambers with good biventricular function (left ventricular ejection fraction 55%) and no structural or hemodynamic compromise. As a definitive preoperative diagnosis could not be established, surgical excision was planned.



Figure 3: Magnetic resonance imaging of the thorax (coronal T2-weighted images) showing a lobulated, multiloculated hyperintense cystic lesion with internal septations.

Surgical management

On 25 September 2025, the patient underwent right-sided VATS in the left lateral decubitus position (Figure 4) using four ports (Figure 5). Intraoperatively, a cystic lesion was identified in the visceral mediastinum. It was closely related to the azygos vein and superior vena cava anteriorly and to the esophagus and trachea posterolaterally. Complete in toto excision was achieved without air leak or vascular injury (Figure 6) and an intercostal drainage (ICD) tube was placed (Figure 7).

Histopathological and immunohistochemical findings

Grossly, the excised cystic lesion measured 7×5×3 cm. Microscopic examination showed features of cystic schwannoma, with Antoni A areas (compact, highly cellular spindle cells with nuclear palisading) and Antoni B areas (loosely arranged hypocellular zones with myxoid stroma) and prominent cystic degeneration. The cyst wall was fibrous and lined by degenerated schwannoma tissue, with no respiratory or gastric epithelium.

On immunohistochemistry, SOX10 was strongly positive and S100 was positive, confirming Schwann cell origin. The Ki-67 proliferation index was approximately 5%, indicating low proliferative activity.



Figure 4: Patient positioning for video-assisted thoracoscopic surgery.

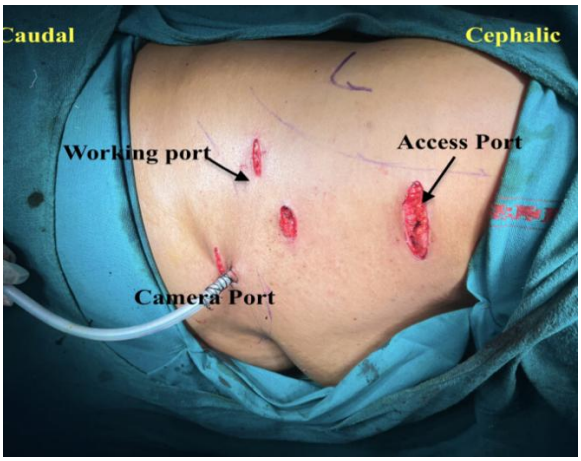

Figure 5: Port placement for right-sided VATS, showing the camera, working and access ports.



Figure 6: Gross specimen of the excised cystic lesion with a measuring scale.



Figure 7: Intercostal drainage tube in situ after closure of the port sites.

Postoperative course

The postoperative course was uneventful. Pain was well controlled, and incentive spirometry was started early to prevent atelectasis. The ICD output decreased progressively, with no air leak, chylothorax or hemorrhage. The ICD was removed on postoperative day (POD) 3 after a chest radiograph confirmed full lung expansion. She tolerated oral feeds, was fully mobilized and was discharged in stable condition on POD 4 (29 September 2025). She was followed up every 6 months for 1 year and remained asymptomatic with no evidence of recurrence.

DISCUSSION

Neurogenic tumors form a notable proportion of primary mediastinal neoplasms, and schwannomas are the most frequent subtype in adults.[1,2] Schwannomas are typically encapsulated, heterogeneous tumors that may show cystic degeneration, but extensive cystic change producing a predominantly cystic lesion is uncommon.[1,4] Cystic change is thought to result from tumor growth outstripping its blood supply, leading to central ischemia, necrosis and hemorrhage. Small neurogenic tumors are often found incidentally, whereas larger lesions cause compressive symptoms such as chest discomfort, dyspnea or dysphagia due to pressure on the trachea, esophagus and great vessels.[2,5] In our patient, the chest fullness, occasional dyspnea and the extrinsic esophageal narrowing on barium swallow reflected this mass effect.

On computed tomography, schwannomas usually appear as well-circumscribed hypodense masses that may contain cystic areas and on MRI they are typically hypointense to isointense on T1-weighted images and hyperintense on T2-weighted images.[1,3] Because cystic schwannomas share these features with foregut duplication cysts, bronchogenic cysts and cystic teratomas, preoperative differentiation remains difficult.[1,3,5] In our case, the multiloculated cystic appearance and visceral mediastinal location favored a foregut duplication cyst and a hydatid cyst was also considered.

Histologically, schwannomas show alternating hypercellular Antoni A and hypocellular Antoni B areas.[1,6] Diffuse expression of SOX10 and S100 confirms Schwann cell lineage, and a low Ki-67 index supports benign behavior.[1,6] In our patient, the absence of respiratory or gastric epithelium excluded a foregut duplication cyst, while the Antoni A and B areas, SOX10 and S100 positivity and a Ki-67 index of approximately 5% confirmed a benign cystic schwannoma.

Complete surgical excision is the treatment of choice.[5,6] Posterolateral thoracotomy was traditionally used for large mediastinal masses, but VATS is now widely used for well-defined benign tumors, with less postoperative pain, shorter chest tube duration, faster recovery and low recurrence rates.[2,5,6] In our patient, complete thoracoscopic excision was achieved despite the lesion's size and its close relation to the azygos vein and superior vena cava, and the chest drain was removed on POD 3.

CONCLUSION

Cystic schwannoma is a rare, benign neurogenic tumor that can closely mimic congenital foregut cysts on imaging, including in the visceral mediastinum. It should be considered in the differential diagnosis of mediastinal cystic lesions. VATS allows safe and complete excision, and definitive diagnosis depends on histopathological and immunohistochemical correlation.

ACKNOWLEDGEMENTS

The authors would like to thank the patient for her consent and cooperation in the publication of this case report. The authors also acknowledge the surgical team, nursing staff and other healthcare professionals involved in the patient care and the institution for providing the facilities for the patient diagnosis and treatment.

Funding: No funding sources
Conflict of interest: None declared
Ethical approval: Not required

REFERENCES

1. Quartey B, Lenert J, Deb SJ, Henry LR. Giant posterior mediastinal ancient schwannoma requiring thoracoabdominal resection: a case report and literature review. World J Oncol. 2011;2:191-4.
2. Szewczyk JB, Hachey K, Rey J, Nguyen DM, Villamizar NR. Large mediastinal schwannoma with great vessel encroachment requiring vascular reconstruction: a case report. Mediastinum. 2021;5:37.

3. Gueldich M, Hentati A, Chakroun A, Abid H, Kammoun S, M'saad S, et al. Giant cystic schwannoma of the middle mediastinum with cervical extension. Libyan J Med. 2015;10:27409.
4. Tripathi SK, Mishra AK, Verma AK, Prakash V. Posterior mediastinal mass diagnosed as schwanomma with concomittant tuberculosis. BMJ Case Rep. 2014;2014:bcr2014205799.
5. Demiroz SM, Sayan M, Celik A. Giant tumors of the posterior mediastinum: a narrative review of surgical treatment. Mediastinum. 2022;6:36.
6. Husodo S, Wati FF. Mediastinal schwannoma: a case report. Int J Surg Case Rep. 2023;109:108564.

Cite this article as: Kumar R, Ali S, Thakur S, Dutt S, Tanwar A. A diagnostic chameleon in the visceral mediastinum: a case report of cystic schwannoma resembling an esophageal/bronchogenic duplication cyst. Int Surg J 2026;13:2647-51.