International Surgery Journal
Tanwar AK et al. Int Surg J. 2026 Dec;13(12):2642-2646
https://www.ijsurgery.com
pISSN 2349-3305 | eISSN 2349-2902

DOI: https://dx.doi.org/10.18203/2349-2902.isj20264379

Case Report

Appendicular perforation presenting as a delayed scrotal abscess in a person living with HIV: a case report

Anirudh Kumar Tanwar*, Prakhar Agrawal, Rahul Kumar, Shatakshi Dutt, Shubham Choudhary, Sahil Thakur, Azaz Akhtar Siddiqui

Department of General Surgery, Lady Hardinge Medical College, New Delhi, India

Received: 18 October 2026
Revised: 14 November 2026
Accepted: 18 November 2026

***Correspondence:**
Dr. Anirudh Kumar Tanwar,
E-mail: anirudhkumar19071998@gmail.com

Copyright: © the author(s), publisher and licensee Medip Academy. This is an open-access article distributed under the terms of the Creative Commons Attribution Non-Commercial License, which permits unrestricted non-commercial use, distribution, and reproduction in any medium, provided the original work is properly cited.

ABSTRACT

Perforated appendicitis commonly results in a localised periappendicular abscess or peritonitis. Extension of appendicular infection beyond the abdominal cavity into the inguinoscrotal region is rare and may mimic a primary genitourinary infection. A 55-year-old man, a known person living with HIV, presented with worsening right lower abdominal pain associated with vomiting. At presentation, examination revealed mild tenderness localised to the right lower abdomen. The patient was initially managed with intravenous analgesics and antibiotics. Imaging revealed a collapsed appendix with non-visualisation of its tip and multiple intercommunicating collections tracking along the right anterolateral abdominal wall, suggestive of appendicular perforation. As patient was stable with no signs of toxicity, was managed conservatively with antibiotics. On the seventh day of hospitalisation, patient developed a new onset right sided scrotal swelling with local rise of temperature, erythema and tenderness. The testis remained palpable. Incision and drainage were done yielding approximately 200 ml of pus. The patient was continued on antibiotics with wound dressing and showed progressive clinical improvement. Anterior abdominal wall abscesses as a complication of perforated appendicitis are rare but significant. Recognition of this unusual presentation is important to avoid overlooking an intra-abdominal source of a seemingly primary scrotal infection.

Keywords: Appendicitis, Perforated appendix, PL-HIV, Scrotal abscess, Immunocompromised

INTRODUCTION

Acute appendicitis is one of the common surgical cases that are encountered in surgical practice with lifetime incidences of 8.6 % of men and 6.4 % of women.[1] Acute appendicitis in immunocompromised individuals have high tendency to complicate. Complicated appendicitis is defined as a perforation of the appendix that develops into a phlegmon (an ill-defined mass of inflammatory tissue) or abscess if contained.[2]

Complicated appendicitis has various presentations including phlegmon, intra-abdominal abscess, generalized peritonitis, appendicocutaneous fistula, and sepsis.[3] Complicated appendicitis with perforation can result in localised abscess formation, peritonitis and extension of infection into adjacent anatomical spaces. Although periappendicular and pelvic collections are well recognised, extension of appendicular infection into the inguinoscrotal region is an unusual occurrence. Abscess formation is a well-known complication of perforated appendicitis.

In rare cases, scrotal abscess can follow perforated appendicitis. A number of cases have been identified where a PPV was present which allowed for the gravitational flow of intraperitoneal pus into the scrotum via the inguinal canal. Although the processus vaginalis

obliterates in most individuals, 15–37% may persist into adulthood.[4]

Inguinoscrotal abscesses are generally associated with local genitourinary or perineal pathology, including epididymoorchitis, pyocele, infected hydrocele, soft-tissue infection and Fournier's gangrene. A secondary scrotal abscess originating from an intra-abdominal source can therefore pose a significant diagnostic challenge.

CASE REPORT

A 55-year-old, unmarried man, presented to the surgery emergency with worsening right lower abdominal pain for 3 days. No complaints of fever or vomiting or anorexia. No complaints of noon passage of stool or flatus. The patient was a known person living with HIV, diagnosed in 2012. He had been receiving antiretroviral therapy since 2013 with a TLD regimen consisting of tenofovir, lamivudine and dolutegravir. He reported good compliance with treatment. His most recent CD4 count was 250 cells/µL. There was no history of previous opportunistic infections or tuberculosis. No surgical history.

On admission, the patient's symptoms were predominantly abdominal. Clinical examination revealed tenderness localised to the right lower abdomen but no lump. The scrotum was normal on admission, with no swelling, erythema, local rise of temperature or tenderness. On day 7 of admission, patient started complaining of inguinoscrotal pain.

Examination

On examination, patient was conscious, oriented. Patient was afebrile. General examination was normal.

Vitals

On presentation vitals were: BP 132/76mmHg; PR: 86/min; Spo2: 98% on Room air; and Respiratory rate: 18/min.

Systemic examination

On examination abdomen was non distended with no visible scars or distended veins or cough impulse. On palpation, abdomen was soft with mild tenderness in right lower abdomen. On auscultation bowel sounds were present.

Inguinoscrotal examination revealed enlarged right scrotum with redness and erythema on inspection with overlying skin normal. On palpation, swelling was tender with local rise of temperature. Testis was palpable separately. No inguinal lymph nodes were papable.

Investigations

Initial blood investigations demonstrated significant leukocytosis, with a total leukocyte count of approximately 24,900/µl with low hemoglobin (9.0g/dl), which subsequently decreased during the course of treatment.

Table 1: Hematological investigations.

Date	Hb (g/dl)	TLC (/µl)	Platelet count	ESR
09/08	9.0	24,900	1.2lac	78
11/08	9.0	20,920	1.4lac	68
13/08	7.9	22,740	1.2lac	60
14/08	7.7	14,150	1.4lac	40

Radiological investigations

Ultrasonography revealed Right testis normal in size shape and echogenicity. Right epididymis and spermatic cord bulky and heterogenous with moderate to gross free fluid in right scrotal sac with internal echoes. Marked scrotal wall edema with thickening.

CECT demonstrated a collapsed appendix with non-visualisation of its tip. The appendicular region was associated with multiple intercommunicating collections tracking along the right anterolateral abdominal wall, with extension towards the lower aspect of the abdominal wall suggestive of appendicular perforation.

Progression

In view of the CT findings and the patient's clinical condition, the patient was managed conservatively with intravenous antibiotics, analgesics and supportive care. Piperacillin-tazobactam was continued during the hospital stay.

Operative management

The development of a new scrotal collection in a patient with established perforated appendicitis raised suspicion of inferior extension of the appendicular infection towards the inguinoscrotal region.

The patient underwent incision and drainage of the scrotal abscess under local anesthesia. The surgical field was thoroughly disinfected with iodine-based antiseptic solution. A linear skin incision of approximately 5.0 cm was made at the upper aspect of the right scrotal abscess. Upon incision, approximately 50 ml of thick purulent exudate observed and evacuated. Further, approximately 200 ml of pus was evacuated. Later sent for culture and sensitivity which showed no growth of organisms.

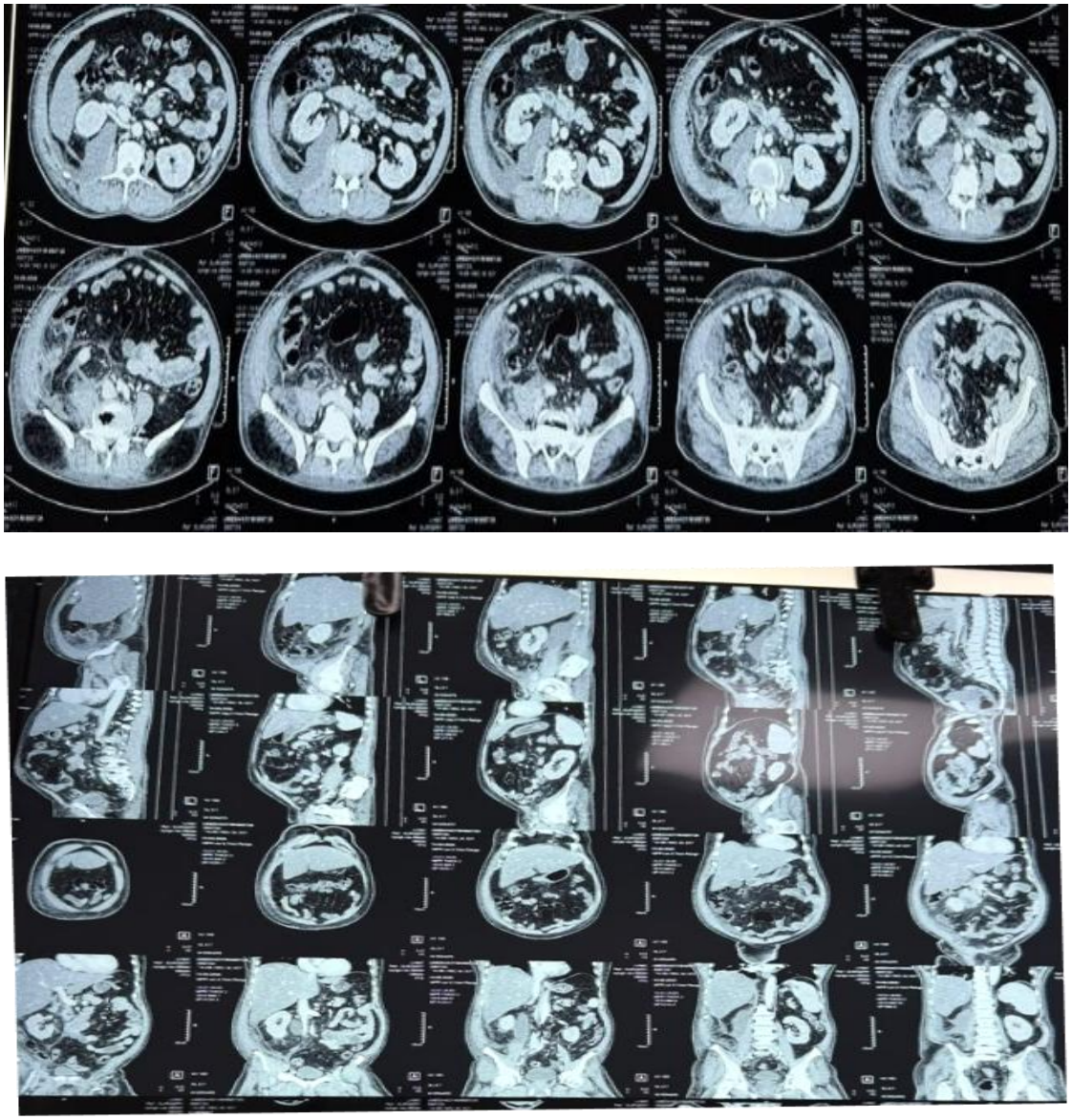

Figure 1: (A) Axial CT image demonstrating the right iliac fossa/appendicular collection (B) Coronal CT image demonstrating the longitudinal right-sided collection and its extension along the abdominal wall.



Figure 2: Intraoperative photograph following paramedian scrotal incision and drainage demonstrating the exposed testis and opened scrotal abscess cavity.



Figure 3: Purulent material obtained during drainage.

Post operative management

A sample of the pus was sent for culture and sensitivity, which subsequently showed no bacterial growth. The patient had already received antimicrobial therapy before drainage, which may have contributed to the sterile culture. Following drainage, the patient was continued on piperacillin-tazobactam. The scrotal wound was managed with twice-daily dressing and progressively improved without documented recurrence during the hospital stay. He was subsequently discharged in a clinically improved condition with advice regarding wound care and follow-up. Patient is on regular follow up in OPD, planned for Colonoscopy to rule out an underlying cause.

DISCUSSION

Acute appendicitis is a common surgical emergency, and delayed diagnosis or treatment can lead to perforation, periappendicular abscess, and peritonitis.[5] Although abscesses usually develop in the pelvis or periappendicular region, extension into the scrotum is rare. A proposed route is a patent processus vaginalis, which permits infected peritoneal fluid to track through the inguinal canal; other routes may include contiguous spread through tissue planes.[6] The presence of both a patent processus vaginalis (PPV) and a perforated appendix should alert physicians to the potential for scrotal abscess formation. However, it's not unprecedented for scrotal abscesses to develop without a PPV.[7–9] Consequently, new-onset scrotal swelling in a patient with an intra-abdominal infection should prompt evaluation for a secondary source rather than assuming primary genitourinary disease.

In this patient, CT demonstrated appendicular perforation with intercommunicating collections along the right anterolateral abdominal wall, followed by delayed development of a scrotal abscess. This sequence supports a possible relationship between the abdominal and scrotal infections. Rare extension of appendicular infection into the inguinal region has previously been reported. Such reports illustrate how unusual anatomical extension can make diagnosis difficult and how imaging and operative findings can establish the relationship between the primary appendicular pathology and the distant abscess.

The present case differs in that the patient did not initially present with an inguinal or scrotal swelling. Instead, the scrotal abscess developed seven days after presentation. In our case it is an adult presenting with scrotal abscess, whereas previous studies have shown pediatric population with Patent processus vaginalis presenting with the same. Limited cases have been documented in elder populations. Incision and drainage provided source control, while continued antibiotics and wound care were followed by clinical improvement. The absence of bacterial growth may reflect prior antimicrobial treatment and does not exclude infection.

HIV infection may complicate surgical decision-making, particularly when immune suppression is advanced. However, these findings should not be generalised to every patient receiving antiretroviral therapy. A propensity score-matched Japanese study found no significant difference in major postoperative complications between HIV-positive and HIV-negative patients undergoing appendectomy.[10] In our case, a CD4 count of 250 cells/μL is clinically relevant, but HIV cannot be assumed to have caused the unusual extension.

This case highlights the importance of reassessing new symptoms, identifying remote sources of infection, and ensuring adequate drainage and follow-up.

CONCLUSION

A scrotal abscess developing during the treatment of perforated appendicitis is an unusual clinical event. In this patient, the initial CT demonstrated appendicular perforation with collections tracking along the right anterolateral abdominal wall, followed by development of a right scrotal abscess seven days later. The case suggests progressive tracking of appendicular infection towards the inguinoscrotal region, resulting in a delayed scrotal abscess. Although HIV may influence the clinical course of infection, its role in this unusual extension cannot be established from a single case. Clinicians should maintain a high index of suspicion for an intra-abdominal source when an apparently primary scrotal abscess develops in a patient with known complicated intra-abdominal infection. This report emphasizes the need to recognize atypical routes of spread and to reassess patients promptly when new clinical findings emerge.

ACKNOWLEDGEMENTS

The authors would like to express their sincere gratitude to the patient and their family for providing consent and cooperation for the publication of this case report. The authors also acknowledge the support and guidance provided by the surgical team, nursing staff and other healthcare professionals involved in the patient's care. The authors are grateful to their institution for providing the necessary facilities and support for the diagnosis, treatment and documentation of this case.

Funding: No funding sources
Conflict of interest: None declared
Ethical approval: Not required

REFERENCES

1. Addiss DG, Shaffer N, Fowler BS, Tauxe RV. The epidemiology of appendicitis and appendectomy in the United States. Am J Epidemiol. 1990;132:910-25.
2. Maxfield MW, Schuster KM, Bokhari J, McGillicuddy EA, Davis KA. Predictive factors for

failure of nonoperative management in perforated appendicitis. J Trauma Acute Care Surg. 2014;76(4):976-81.
3. Perez KS, Allen SR. Complicated appendicitis and considerations for interval appendectomy. JAAPA. 2018;31:35-41.
4. Zarei E, Mounesi Sohi AS, Ghadipasha A, Jahangiri F, Ranjbar E. Perforated appendicitis masquerading as a left-sided scrotal abscess: a case report and literature review. Radiol Case Rep. 2024;19(12):6460-4.
5. Di Saverio S, Podda M, De Simone B, Ceresoli M, Augustin G, Gori A, et al. Diagnosis and treatment of acute appendicitis: 2020 update of the WSES Jerusalem guidelines. World J Emerg Surg. 2020;15:27.
6. Saleem MM. Scrotal abscess as a complication of perforated appendicitis: a case report and review of the literature. Cases J. 2008;1:165.
7. Yasumoto R, Kawano M, Kawanishi H, Shindow K, Hiura A, Kim E, et al. Left acute scrotum associated with appendicitis. Int J Urol. 1998;5(1):108-10.
8. McKerrow WS, Thomson HJ. Unusual complication of perforated appendix. Br Med J (Clin Res Ed). 1982;284:1442.
9. Gan BS, Sweeney JP. An unusual complication of appendectomy. J Pediatr Surg. 1994;29:1622.
10. Norimatsu Y, Ito K, Takemura N, Inagaki F, Mihara F, Tsukada K, et al. Surgical management of appendicitis in patients with human immunodeficiency virus (HIV) positivity: a propensity score-matched analysis in a base hospital for HIV treatment in Japan. Surg Today. 2023;53(9):1013-8.

Cite this article as: Anirudh Kumar Tanwar AK, Agrawal P, Kumar R, Dutt S, Choudhary S, Thakur S, et al. Appendicular perforation presenting as a delayed scrotal abscess in a person living with HIV: a case report. Int Surg J 2026;13:2642-6.