International Surgery Journal
Purushothaman S et al. Int Surg J. 2026 Dec;13(12):2574-2578
https://www.ijsurgery.com
pISSN 2349-3305 | eISSN 2349-2902
DOI: https://dx.doi.org/10.18203/2349-2902.isj20264366

Case Series

Delayed gastric necrosis following corrosive acid ingestion: a case series

S. Purushothaman*, S. M. Sathish Devakumar, C. Selvaganesh, P. Senthil Kumar, L. Anand

Institute of Surgical Gastroenterology and Liver Transplantation, Government Stanley Medical College and Hospital, Chennai, Tamil Nadu, India

Received: 14 October 2026
Accepted: 14 November 2026

***Correspondence:**
Dr. S. Purushothaman,
E-mail: purushothamans844@gmail.com

Copyright: © the author(s), publisher and licensee Medip Academy. This is an open-access article distributed under the terms of the Creative Commons Attribution Non-Commercial License, which permits unrestricted non-commercial use, distribution, and reproduction in any medium, provided the original work is properly cited.

ABSTRACT

Corrosive acid ingestion can cause severe gastric injury, with progression to necrosis and perforation despite initially reassuring clinical and radiological findings. Assessing the extent of gastric damage and determining the appropriate timing of surgical intervention remain challenging. We report four cases of hydrochloric acid ingestion complicated by severe gastric necrosis requiring total gastrectomy. Initial assessment revealed hemodynamic stability and an absence of peritonitis in all four patients. Early contrast-enhanced computed tomography (CECT) demonstrated preserved gastric wall enhancement in three patients. In one patient, CECT was not performed in view of acute kidney injury. All four patients subsequently developed significant clinical deterioration between days 15 and 20 after ingestion, presenting with hematemesis or features suggestive of evolving gastric necrosis and perforation, warranting exploration. Intraoperatively, the external gastric appearance was grossly normal in two patients, in whom intraoperative gastroscopy demonstrated extensive mucosal necrosis. The other two had extensive transmural gastric necrosis. All four patients underwent total gastrectomy with feeding jejunostomy and cervical esophagostomy. Histopathology revealed varying depths of injury, ranging from mucosal and submucosal necrosis to transmural necrosis. Two patients died in the postoperative period due to acute respiratory distress syndrome and sepsis, while the other two survived and remained under follow-up. Corrosive gastric injury may progress despite initially reassuring clinical findings and preserved gastric wall enhancement on CECT. Careful clinical surveillance, timely reassessment, and integration of clinical, radiological, endoscopic, and operative findings are essential. Intraoperative gastroscopy may help identify severe mucosal injury when serosal inspection alone is insufficient.

Keywords: Corrosive acid ingestion, Gastric necrosis, Hydrochloric acid, Total gastrectomy, Contrast-enhanced computed tomography, Intraoperative gastroscopy

INTRODUCTION

Corrosive acid ingestion is associated with significant morbidity and mortality due to chemical injury to the upper gastrointestinal tract. The stomach is particularly vulnerable to acid-induced injury, which may range from mucosal inflammation and ulceration to extensive necrosis, hemorrhage, and perforation. The severity of gastric injury depends on several factors, including the nature and concentration of the corrosive agent, the volume ingested, and the duration of tissue exposure.[1,2]

The assessment of gastric injury following corrosive ingestion remains challenging because the clinical presentation and radiological findings may not accurately reflect the extent of tissue damage. Contrast-enhanced computed tomography (CECT) is an important investigation for evaluating gastric wall enhancement,

identifying suspected transmural necrosis, and detecting complications such as perforation. However, preserved gastric wall enhancement does not necessarily exclude significant mucosal injury.[3] Upper gastrointestinal endoscopy provides direct visualization of the mucosa and may complement radiological assessment, although incomplete examination and clinical instability may limit its utility in selected patients.[4]

Another important consideration is the potential for progression of corrosive injury after the initial presentation. Patients who are initially hemodynamically stable and have no signs of peritonitis may subsequently develop gastrointestinal bleeding, progressive gastric necrosis, or perforation. The timing of surgical intervention is therefore a critical component of management. Delayed recognition of progressive necrosis may contribute to sepsis, physiological deterioration, and adverse outcomes, whereas emergency gastrectomy carries substantial operative and postoperative risks.

In this report, we describe four patients with hydrochloric acid ingestion who developed severe gastric necrosis requiring total gastrectomy. The cases demonstrate the varied presentation and histopathological severity of corrosive gastric injury, the limitations of relying on individual diagnostic modalities, and the potential role of intraoperative gastroscopy in assessing gastric mucosal viability.

CASE SERIES

Case 1

A 40-year-old woman who had ingested approximately 100 ml of hydrochloric acid in a suicidal attempt was referred to our institution on day 5 after ingestion. At presentation, she was hemodynamically stable, with a soft abdomen and no signs of peritonitis. CECT abdomen showed preserved gastric wall enhancement without evidence of perforation. Upper gastrointestinal endoscopy was not performed during the acute phase. On day 15 after ingestion, she developed hematemesis with hemodynamic instability, prompting emergency exploration. The external gastric wall appeared grossly normal. Intraoperative gastroscopy revealed complete gastric mucosal necrosis. (Figure 1) Total gastrectomy with feeding jejunostomy and cervical esophagostomy was performed. Histopathology demonstrated necrosis involving the mucosa and submucosa, without transmural necrosis. The patient was discharged on postoperative day 15 and remains under follow-up at eight months, with coloplasty being planned.

Case 2

A 58-year-old man who had accidentally ingested approximately 50 ml of hydrochloric acid was referred to our institution 72 hours after ingestion. At presentation, he was hemodynamically stable, with a soft abdomen and no signs of peritonitis. CECT abdomen showed circumferential gastric wall thickening and submucosal edema involving the fundus and proximal body with preserved gastric wall enhancement. Upper gastrointestinal endoscopy was not performed. On day 15 after ingestion, he developed hematemesis with a fall in hemoglobin and hemodynamic instability, prompting emergency exploration. The external gastric wall appeared grossly normal. Intraoperative gastroscopy revealed blood clots and mucosal necrosis involving the fundus and body. (Figure 2)

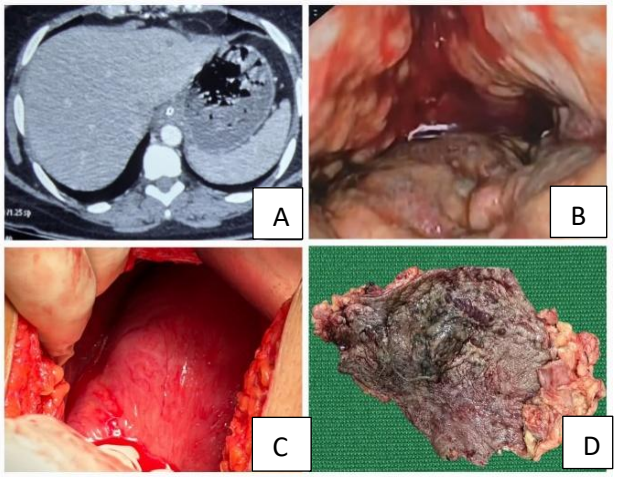

Figure 1: (A) CECT abdomen showing preserved gastric wall enhancement; (B) Intraoperative gastroscopy demonstrating extensive gastric mucosal necrosis; (C) External serosal appearance of the stomach, appearing grossly normal; (D) Resected gastrectomy specimen showing extensive mucosal sloughing.

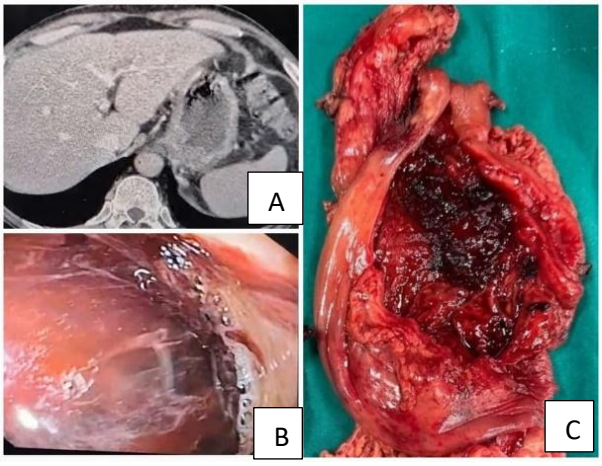

Figure 2: (A) CECT abdomen showing gastric wall thickening and submucosal edema involving the fundus and proximal body; (B) Intraoperative gastroscopy demonstrating gastric mucosal necrosis with blood clots; (C) Resected gastrectomy specimen showing extensive ulceration and necrosis of the gastric mucosa.

Total gastrectomy with feeding jejunostomy and cervical esophagostomy was performed. Histopathology demonstrated necrosis extending into the muscularis propria, without transmural necrosis. The postoperative course was complicated by prolonged ventilatory support, acute respiratory distress syndrome, and sepsis. The patient died on postoperative day 8.

Case 3

A 33-year-old man who had accidentally ingested approximately 150 ml of hydrochloric acid was referred to our institution 10 hours after ingestion. At presentation, he was hemodynamically stable, with a soft abdomen and no signs of peritonitis. Upper gastrointestinal endoscopy demonstrated severe edema at the esophagogastric junction, and the scope could not be advanced further. The patient subsequently developed acute kidney injury requiring dialysis, with renal function recovering by day 16 after ingestion. In view of persistent sepsis, CECT abdomen was performed and demonstrated extensive gastric necrosis. Emergency laparotomy revealed necrosis involving the proximal fundus, distal body, and antrum. (Figure 3) Total gastrectomy with feeding jejunostomy and cervical esophagostomy was performed. Histopathology confirmed transmural necrosis of the involved regions with diffuse gastric inflammation. The patient died on postoperative day 5 due to acute respiratory distress syndrome and sepsis.

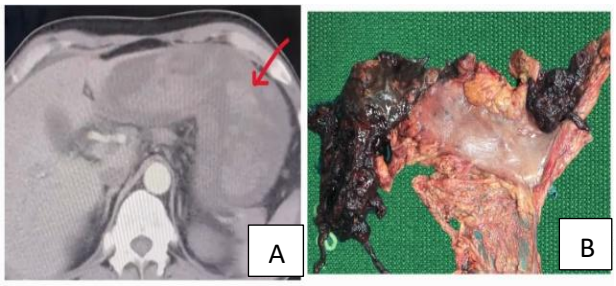

Figure 3: (A) CECT abdomen showing extensive gastric wall abnormalities suggestive of gastric necrosis (arrow); (B) Resected gastrectomy specimen showing extensive transmural necrosis involving the fundus, distal body, and antropyloric region.

Case 4

A 32-year-old woman who had ingested approximately 100 ml of hydrochloric acid in a suicidal attempt was referred to our institution 72 hours after ingestion. At presentation, she was hemodynamically stable, with a soft abdomen and no signs of peritonitis. Initial CECT abdomen demonstrated diffuse esophageal and gastric wall edema with preserved gastric wall enhancement and no pneumoperitoneum. On day 20 after ingestion, she developed abdominal distension and pain. Repeat CECT demonstrated focal thinning, bulging, and hypoenhancement along the greater curvature of the stomach, suggestive of evolving gastric necrosis with impending perforation. (Figure 4) Emergency laparotomy revealed necrosis involving the distal body and antrum, with an additional necrotic patch and perforation in the fundus. Total gastrectomy with feeding jejunostomy and cervical esophagostomy was performed. Histopathology demonstrated transmural necrosis at the perforation site, with mucosal inflammation in the remaining gastric areas. The patient was discharged on postoperative day 8 and remains under follow-up at one month, with reported improvement in nutritional status.

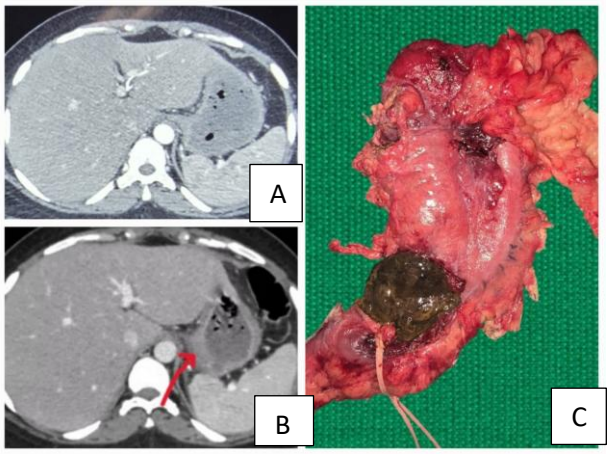

Figure 4: (A) Initial CECT abdomen showing gastric wall edema with preserved enhancement; (B) Repeat CECT demonstrating focal gastric wall thinning and hypoenhancement (arrow), suggestive of evolving gastric necrosis; (C) Resected gastrectomy specimen showing perforation at the fundus, with necrosis involving the distal body and antropyloric region.

DISCUSSION

The management of severe corrosive gastric injury remains challenging because the extent of tissue damage may not be apparent from a single clinical or radiological assessment. Although contrast-enhanced computed tomography (CECT) is valuable for identifying features suggestive of transmural necrosis, its ability to characterize mucosal injury is limited.[5] Preserved gastric wall enhancement should therefore not be interpreted as definitive evidence of an intact gastric mucosa. Conversely, endoscopy provides direct visualization of mucosal damage and can help identify severe corrosive injury, including Zargar grade III lesions, which warrant close clinical surveillance. Upper gastrointestinal endoscopy is generally best performed within the first 12–48 hours, with careful consideration of the risks and benefits of later procedures because tissue friability increases during the subsequent period.

A critical feature of corrosive acid ingestion is the potential for delayed progression of tissue injury. Initial investigations may underestimate the eventual severity,

and the absence of perforation or obvious necrosis on early imaging does not exclude subsequent complications. Serial assessment of abdominal findings, hemodynamic status, gastrointestinal bleeding, hemoglobin trends, and other evidence of deterioration is essential. Repeat imaging is appropriate when the clinical condition changes and when the findings are likely to influence management.[6] However, investigations may be limited by organ dysfunction, incomplete endoscopic visualization, or the patient's instability. In such circumstances, the decision to operate must be guided by the overall clinical picture rather than delayed until definitive radiological confirmation is obtained.

The discrepancy between the external appearance of the stomach and the underlying mucosal injury is another important consideration. Serosal inspection during laparotomy may not adequately reflect the extent of intraluminal damage.[7] Intraoperative gastroscopy can be particularly helpful in this setting, providing additional information regarding the extent of mucosal injury. It should be considered when indicated rather than assuming that the stomach is normal based solely on its gross serosal appearance.

The timing of surgery presents a further challenge. Delaying intervention in the presence of progressive necrosis may permit deterioration, perforation, sepsis, and physiological instability, whereas major surgery itself carries substantial morbidity. Accordingly, the decision for exploration should be based on the combined clinical, endoscopic, radiological, and operative evidence, with particular importance given to worsening clinical parameters.[8] The two postoperative deaths in this series illustrate the seriousness of advanced corrosive injury but cannot establish that earlier surgery would necessarily have prevented mortality.

Limitations

This study has several limitations. First, it is a retrospective descriptive case series involving only four patients, which limits the generalizability of the findings. Second, the initial diagnostic evaluation was not uniform across all patients: upper gastrointestinal endoscopy was not performed in three patients, while in one patient the examination was limited by severe edema at the esophagogastric junction. Initial CECT findings and the timing of subsequent imaging also varied between cases, limiting direct comparisons of disease progression.

Third, the absence of standardized serial imaging and endoscopic assessments prevents a detailed characterization of the temporal progression of gastric injury. Fourth, the heterogeneous depth and distribution of necrosis, ranging from mucosal injury to transmural necrosis, preclude meaningful comparisons between diagnostic findings and histopathological severity. Finally, the small sample size and absence of a comparison group do not permit conclusions regarding the superiority of any particular diagnostic modality, the optimal timing of surgical intervention, or the effect of earlier surgery on patient outcomes.

CONCLUSION

Corrosive gastric injury following hydrochloric acid ingestion may progress to extensive necrosis, hemorrhage, and perforation despite initially reassuring clinical findings. Preserved gastric wall enhancement on CECT does not exclude significant mucosal injury, and a grossly normal serosal appearance at laparotomy may underestimate the extent of intraluminal damage. Intraoperative gastroscopy can provide additional information regarding mucosal injury when indicated. These cases emphasize the importance of close clinical surveillance, timely reassessment, and integration of clinical, radiological, endoscopic, and operative findings when determining the need for surgical intervention.

Funding: No funding sources
Conflict of interest: None declared
Ethical approval: Not required

REFERENCES

1. Contini S, Scarpignato C. Caustic injury of the upper gastrointestinal tract: a comprehensive review. World J Gastroenterol. 2013;19(25):3918-30.
2. Chirica M, Bonavina L, Kelly MD, Sarfati E, Cattan P. Caustic ingestion. Lancet. 2017;389(10083):2041-52.
3. Kaewlai R, Noppakunsomboon N, Tongsai S, Tamrakar B, Kumthong N, Teerasamit W, et al. Performance of computed tomography and its reliability for the diagnosis of transmural gastrointestinal necrosis in a setting of acute ingestion of predominantly strong acid substances in adults. Clin Toxicol (Phila). 2023;61(5):346-54.
4. Zargar SA, Kochhar R, Mehta S, Mehta SK. The role of fiberoptic endoscopy in the management of corrosive ingestion and modified endoscopic classification of burns. Gastrointest Endosc. 1991;37(2):165-9.
5. Chirica M, Resche-Rigon M, Zagdanski AM, Bruzzi M, Bouda D, Roland E, et al. Computed tomography evaluation of esophagogastric necrosis after caustic ingestion. Ann Surg. 2016;264(1):107-13.
6. Bonnici KS, Wood DM, Dargan PI. Should computerised tomography replace endoscopy in the evaluation of symptomatic ingestion of corrosive substances? Clin Toxicol (Phila). 2014;52(9):911-25.
7. Chirica M, Kelly MD, Siboni S, Aiolfi A, Riva CG, Asti E, et al. Esophageal emergencies: WSES guidelines. World J Emerg Surg. 2019;14:26.

8. Kluger Y, Ben Ishay O, Sartelli M, Katz A, Ansaloni L, Gomez CA, et al. Caustic ingestion management: World Society of Emergency Surgery preliminary survey of expert opinion. World J Emerg Surg. 2015;10:48.

Cite this article as: Purushothaman S, Devakumar SMS, Selvaganesh C, Senthil Kumar P, Anand L. Delayed gastric necrosis following corrosive acid ingestion: a case series. Int Surg J 2026;13:2574-8.