International Surgery Journal
Haque MS et al. Int Surg J. 2026 Dec;13(12):2443-2449
https://www.ijsurgery.com
pISSN 2349-3305 | eISSN 2349-2902

DOI: https://dx.doi.org/10.18203/2349-2902.isj20264349

Original Research Article

Patterns of presentation and risk factors in bile duct injury following laparoscopic cholecystectomy

M. Shamsul Haque[1]*, M. Tahir Hossain[2], M. Anisul Islam[3], A. K. M. Touhidul Islam[4], M. Nafiz Ahmed Khan[5], H. M. Arab[6], M. Soud Khan[7]

[1]Department of Surgery, Enam Medical College and Hospital, Savar, Dhaka, Bangladesh
[2]Department of Surgical Oncology, Enam Medical College and Hospital, Savar, Dhaka, Bangladesh
[3]Department of Surgery, BIHS General Hospital, Dhaka, Bangladesh
[4]Department of Surgery, Bangladesh Medical College Hospital, Dhaka, Bangladesh
[5]Department of Hepatobiliary, Pancreatic Surgery and Liver Transplant, United Health Care (UMCH), Dhaka, Bangladesh
[6]Department of Educational and Counselling Psychology, University of Dhaka, Dhaka, Bangladesh
[7]Department of Surgery, BIRDEM General Hospital, Dhaka, Bangladesh

Received: 13 October 2026
Revised: 13 November 2026
Accepted: 14 November 2026

***Correspondence:**
Dr. M. Shamsul Haque,
Email: dr.shaque28@gmail.com

Copyright: © the author(s), publisher and licensee Medip Academy. This is an open-access article distributed under the terms of the Creative Commons Attribution Non-Commercial License, which permits unrestricted non-commercial use, distribution, and reproduction in any medium, provided the original work is properly cited.

ABSTRACT

Background: Bile duct injury remains a serious complication of laparoscopic cholecystectomy, with variable clinical presentations and several associated patient- and operative-related factors. Therefore, this study was conducted to evaluate the patterns of presentation and factors associated with bile duct injury following laparoscopic cholecystectomy.
Methods: This cross-sectional observational study included 30 patients with bile duct injury following laparoscopic cholecystectomy, conducted from January to December 2013 in the Department of Surgery of Bangabandhu Sheikh Mujib Medical University (BSMMU) and BIRDEM General Hospital, with samples also collected from Dhaka Medical College Hospital, Shaheed Suhrawardy Medical College Hospital, and Sir Salimullah Medical College Mitford Hospital. Demographic, clinical, diagnostic, Bismuth classification, and operative findings were assessed using descriptive statistics.
Results: Among 30 BDI patients, females predominated (80.0%), with most aged 30–39 years (40.0%). Abdominal pain (96.7%) and intra-abdominal collection (90.0%) were the commonest presentations. Acute cholecystitis/acute biliary pancreatitis surgery (40.0%) was the main observed factor. Most presented within 1 month (56.7%), MRCP was performed in 80.0%, Bismuth Grade 2 predominated (36.7%), and sub-hepatic collection was the commonest operative finding (76.7%).
Conclusion: Bile duct injury after laparoscopic cholecystectomy commonly presents with abdominal pain and collections and is associated with difficult inflammatory and anatomical conditions, highlighting the importance of early recognition and accurate imaging.

Keywords: Bile duct injury, Laparoscopic cholecystectomy, Risk factors, Clinical presentation, Biliary anatomy

INTRODUCTION

Cholecystectomy is among the most commonly performed gastrointestinal surgical procedures, with the laparoscopic approach established as the gold standard for symptomatic cholecystolithiasis and both chronic and acute cholecystitis.[1] Compared with open cholecystectomy, laparoscopic cholecystectomy provides several recognized benefits, including less postoperative pain, a shorter hospital stay, and more rapid recovery, making it the preferred approach for symptomatic gallstone disease.[2] Despite these advantages, bile duct injury remains a major concern following laparoscopic cholecystectomy because of its potential to cause long-term morbidity, necessitate repeated interventions, and adversely affect quality of life.[3] The incidence of bile duct injury associated with laparoscopic cholecystectomy has been reported to range from 0.3% to 0.8%, compared with 0.1–0.2% following open cholecystectomy.[4,5] Iatrogenic bile duct injury (IBDI) may result in considerable perioperative morbidity and mortality and can adversely affect long-term survival and quality of life.[6]

Misidentification of biliary anatomy, rather than technical failure alone, represents the principal mechanism underlying bile duct injury. Factors that may contribute to this misidentification include inflammatory changes within Calot's triangle, aberrant biliary anatomy, excessive traction on the gallbladder, bleeding, and inadequate visualization.[7] The presence of acute cholecystitis, dense adhesions, obesity, and distorted anatomy may further increase the likelihood of injury.[8] Both patient-related and operative factors have been associated with bile duct injury, including advanced age, male sex, acute or chronic cholecystitis, prolonged operative time, and difficult dissection.[9] Anatomical variations of the biliary system, such as cystic duct anomalies and variations in hepatic duct branching, can also contribute to incorrect identification of important anatomical structures. Furthermore, acute inflammatory conditions such as acute cholecystitis may obscure the normal anatomical landmarks and make dissection within Calot's triangle more difficult. Several factors have therefore been implicated in the occurrence of bile duct injury during cholecystectomy. Previous studies have suggested that intraoperative cholangiography may reduce both the incidence and severity of bile duct injury, while patient age, sex, disease severity, and hospital- and surgeon-related factors may also influence its occurrence.[10]

The clinical manifestations of bile duct injury are variable and may depend on the type and location of the injury as well as the time at which it is detected. Bile duct injuries may range from bile leak to stenosis or complete transection of the biliary duct. Early consequences may include biliary peritonitis, sepsis, and multiple organ failure, whereas delayed complications may include recurrent biliary stricture, cholangitis, secondary biliary cirrhosis, and substantial impairment of quality of life. The spectrum of injury may also extend from minor leakage involving aberrant ducts or the cystic stump to complete occlusion of the main bile duct or one of its branches, including an aberrant right duct. Bile duct strictures and biliary leakages are important long-term complications following laparoscopic cholecystectomy and may be associated with substantial morbidity, mortality, and prolonged hospitalization.[11] Management of postoperative IBDI frequently involves endoscopic procedures, including biliary stent placement, biliary sphincterotomy, and nasobiliary drainage.[12] However, major IBDI, such as complete dissection of the common bile duct (CBD), may require surgical management.[13]

Because bile duct injury can result in serious clinical consequences, recognition of factors associated with its occurrence remains important in routine clinical practice. Preventive measures, particularly achievement of the critical view of safety (CVS), have been shown to reduce the incidence of major bile duct injuries and are widely recommended.[5,14] In difficult cases, early conversion to open surgery and selective use of intraoperative cholangiography may also be considered as preventive measures [6,9]. When major bile duct injury (MBDI) occurs, timely consultation with an experienced hepatobiliary surgeon is recommended.[8] Management of these injuries may also require a multidisciplinary approach involving skilled hepatobiliary surgeons, interventional radiologists, and gastroenterologists at a tertiary referral center to minimize further complications and injuries within the hepatoduodenal ligament.[15] Therefore, this study was conducted to evaluate the patterns of presentation and factors associated with bile duct injury following laparoscopic cholecystectomy.

The objective of this study was to evaluate the patterns of presentation and factors associated with bile duct injury following laparoscopic cholecystectomy.

METHODS

This cross-sectional observational study was conducted in the Department of Surgery, Bangabandhu Sheikh Mujib Medical University (BSMMU) and BIRDEM General Hospital, Dhaka, Bangladesh, with samples also collected from Dhaka Medical College Hospital, Shaheed Suhrawardy Medical College Hospital, and Sir Salimullah Medical College Mitford Hospital between January 2013 and December 2013. A total of 30 patients with bile duct injury following laparoscopic cholecystectomy were enrolled according to predefined inclusion and exclusion criteria. The study evaluated demographic characteristics, clinical presentation, observed risk factors, previous attempts and timing of presentation, diagnostic investigations, Bismuth classification, and operative findings.

Inclusion criteria

Inclusion criteria included patients having a history of laparoscopic cholecystectomy with bile duct injury recognized either intraoperatively or within 6 months after surgery. Patients who were diagnosed with bile duct injury following laparoscopic cholecystectomy. and those who were referred to or admitted to the participating hospitals for evaluation of bile duct injury.

Exclusion criteria

Exclusion criteria included those patients who had any bile duct injury associated with choledocholithiasis, bile duct injury following hepaticojejunostomy, bile duct injury associated with cholangiocarcinoma, bile duct injury associated with gastrectomy, bile duct injury following T-tube extraction or had laparoscopic cholecystectomy performed more than 6 months previously.

Study variables and data collection

The study variables included age, gender, clinical presentation, observed risk factors, previous attempts before referral, timing of presentation, diagnostic investigations, Bismuth classification, and operative findings. Clinical presentation included abdominal pain, intra-abdominal collection, cholangitis, biliary peritonitis, obstructive jaundice, biliary fistula, liver cirrhosis, and hepatic failure. Observed factors included surgical intervention during acute cholecystitis or acute biliary pancreatitis, bleeding in Calot's triangle with unclear anatomy, large impacted stone in Hartmann's pouch, Mirizzi's syndrome, severely scarred or shrunken gallbladder, and abnormal biliary anatomy. Previous attempts before referral and timing of recognition or presentation were recorded. Patients were recruited from referred cases and inpatients with bile duct injury following laparoscopic cholecystectomy who fulfilled the eligibility criteria. Clinical examination, laboratory investigations, imaging findings, and operative findings were recorded using a pre-designed structured data collection sheet and verified from relevant medical records.

Diagnostic and operative assessment

Liver function tests and abdominal ultrasonography were performed as part of the diagnostic evaluation. CT scan was used to assess fluid collections and proximal biliary duct dilatation. ERCP and MRCP were performed to demonstrate bile leakage and determine the level of bile duct injury. The level of injury was classified according to the Bismuth classification. Operative findings included sub-hepatic collection, high-level stricture, dense adhesion and fibrosis, gross hepatomegaly, associated vascular injury, and associated bowel injury.

Statistical analysis

All collected data were compiled in a master data sheet and analyzed using SPSS for Windows. Descriptive statistics were used to summarize the findings, with categorical variables presented as frequencies and percentages. Results were presented using tables and graphical representations.

RESULTS

The majority of patients were aged 30–39 years (12 patients, 40.0%), followed by those aged 40–49 years (8 patients, 26.7%) and 20–29 years (5 patients, 16.7%). Patients aged 50–59 years accounted for 3 cases (10.0%), while those aged 60–69 years and ≥70 years comprised 1 patient (3.3%) each. Female patients predominated, accounting for 24 patients (80.0%), while 6 patients (20.0%) were male, with a male-to-female ratio of 1:4.

Abdominal pain was the most common clinical presentation, occurring in 29 patients (96.7%), followed by intra-abdominal collection in 27 patients (90.0%). Cholangitis and biliary peritonitis were each observed in 18 patients (60.0%), while obstructive jaundice and biliary fistula were each present in 12 patients (40.0%). Liver cirrhosis and hepatic failure were observed in 2 patients (6.7%) each.

Table 1: Demographic characteristics of the study subjects with bile duct injury (n=30).

Category	Variable	Frequency (N)	Percentage (%)
Age group (years)	20–29	5	16.7
	30–39	12	40.0
	40–49	8	26.7
	50–59	3	10.0
	60–69	1	3.3
	≥70	1	3.3
Gender	Male	6	20.0
	Female	24	80.0

Surgical intervention during acute cholecystitis and acute biliary pancreatitis was the most frequently observed risk factor, occurring in 12 patients (40.0%), followed by bleeding in Calot's triangle with unclear anatomy in 9 patients (30.0%). Large impacted stones in Hartmann's pouch were observed in 5 patients (16.7%), while Mirizzi's syndrome was identified in 2 patients (6.7%). Severely scarred or shrunken gallbladder and abnormal biliary anatomy were each observed in 1 patient (3.3%).

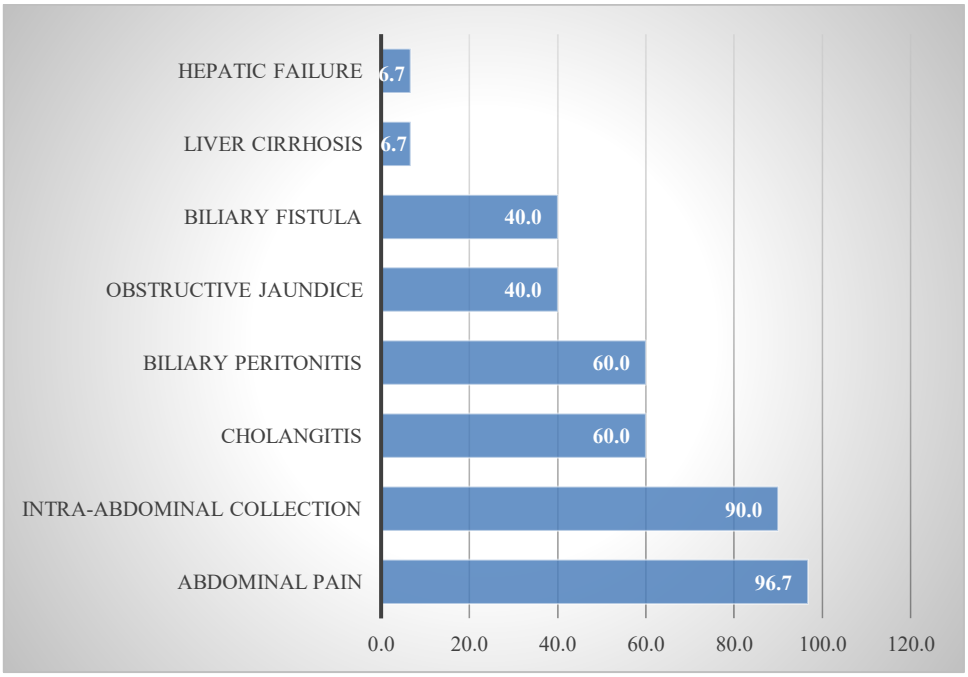

Figure 1: Clinical presentation of patients with bile duct injury (n=30).

Table 2: Risk factors identified among patients with bile duct injury (n=30).

Variable	Frequency (N)	Percentage (%)
Surgical intervention during acute cholecystitis and acute biliary pancreatitis	12	40.0
Bleeding in Calot's triangle/unclear anatomy	9	30.0
Large impacted stone in Hartmann's pouch	5	16.7
Mirizzi's syndrome	2	6.7
Severely scarred/shrunken gallbladder	1	3.3
Abnormal biliary anatomy	1	3.3

Table 3: Previous attempts and time of presentation of bile duct injury (n=30).

Category	Variable	Frequency (N)	Percentage (%)
Previous attempts before referral	No attempt	12	40.0
	One attempt	15	50.0
	Two attempts	3	10.0
	>2 attempts	0	0.0
Time of presentation	Peroperative	6	20.0
	1st month	17	56.7
	2nd–6th months	7	23.3

Regarding previous attempts before referral, 15 patients (50.0%) had undergone one attempt, while 12 patients (40.0%) had no previous attempt and 3 patients (10.0%) had undergone two attempts. In terms of timing of presentation, 17 patients (56.7%) presented within the first month following laparoscopic cholecystectomy, while 7 patients (23.3%) presented during the second to sixth months and 6 patients (20.0%) were recognized peroperatively.

Table 4: Diagnostic investigations and bismuth classification of bile duct injury (n=30).

Category	Variable	Frequency (N)	Percentage (%)
Diagnostic investigation	Liver function test	30	100.0
	Ultrasonogram	30	100.0
	MRCP	24	80.0
	ERCP	11	36.7
	CT scan	3	10.0
	Tubogram	3	10.0
	Fistulogram	2	6.7
Bismuth classification	Grade 1	6	20.0
	Grade 2	11	36.7
	Grade 3	9	30.0
	Grade 4	3	10.0
	Grade 5	1	3.3

Liver function tests and ultrasonography were performed in all 30 patients (100.0%). MRCP was performed in 24 patients (80.0%), followed by ERCP in 11 patients (36.7%), CT scan and tubogram in 3 patients (10.0%) each, and fistulogram in 2 patients (6.7%). According to the Bismuth classification, Grade 2 injury was the most frequently observed, occurring in 11 patients (36.7%), followed by Grade 3 in 9 patients (30.0%) and Grade 1 in 6 patients (20.0%). Grade 4 and Grade 5 injuries were observed in 3 patients (10.0%) and 1 patient (3.3%), respectively.

Table 5: Operative findings and difficulties encountered in patients with bile duct injury (n=30).

Operative findings/difficulties	Frequency (N)	Percentage (%)
Sub-hepatic collection	23	76.7
High-level stricture	12	40.0
Dense adhesion and fibrosis	8	26.7
Gross hepatomegaly	3	10.0
Associated vascular injury	2	6.7
Associated bowel injury	2	6.7

Sub-hepatic collection was the most common operative finding, observed in 23 patients (76.7%), followed by high-level stricture in 12 patients (40.0%). Dense adhesion and fibrosis were encountered in 8 patients (26.7%), while gross hepatomegaly was present in 3 patients (10.0%). Associated vascular injury and bowel injury were each identified in 2 patients (6.7%).

DISCUSSION

In this study, bile duct injury following laparoscopic cholecystectomy was more frequently observed among female patients, with abdominal pain and intra-abdominal collection being the predominant clinical presentations. Acute cholecystitis or acute biliary pancreatitis, bleeding in Calot's triangle with unclear anatomy, and impacted stones in Hartmann's pouch were the most frequently observed associated factors, while sub-hepatic collection and high-level stricture were the predominant operative findings.

The present study demonstrated a predominance of female patients with bile duct injury, with women comprising 24 (80.0%) cases and men 6 (20.0%), giving a female-to-male ratio of 4:1. This finding is comparable with the observations of Moldovan et al who reported a female-to-male ratio of 2.7:1 among patients with bile duct injury, and Sicklick et al who found that women accounted for 150 (75%) cases.[16,17] Regarding age, the largest proportion of patients in the present study belonged to the 30–39-year age group (40.0%), followed by the 40–49-year age group (26.7%), indicating that BDI occurred predominantly among patients in middle adulthood. This pattern was broadly consistent with Moldovan et al., who reported a mean age of 47 years (range, 20–85 years), and Sicklick et al who reported a mean age of 45.5 years and a median age of 44 years.[16,17] Overall, the demographic profile of the present study was similar to these previous reports, particularly with respect to the predominance of female patients and the occurrence of BDI predominantly during middle adulthood.

Among the factors observed in patients with BDI in the present study, surgical intervention during acute cholecystitis and acute biliary pancreatitis was the most

frequently identified, occurring in 12 (40.0%) cases, followed by bleeding in Calot's triangle with unclear anatomy in 9 (30.0%) cases. These findings are broadly comparable with Nuzzo et al., who reported inflammatory changes of the gallbladder in 23.3% of recognized BDI cases and problems controlling intraoperative hemorrhage in 4.9% of cases.18 Nuzzo et al. further observed that BDI was more frequent when laparoscopic cholecystectomy was performed for cholecystitis than for simple cholelithiasis.[18] Similarly, Kholdebarin et al identified emergency operation as an independent risk factor for BDI, with an adjusted OR of 5.0, while failure to identify the cystic duct was strongly associated with injury, with an adjusted OR of 13.7.[10] These findings support the relevance of acute inflammatory conditions and difficult or unclear operative anatomy in the setting of BDI. In the present study, large impacted stones in Hartmann's pouch were identified in 5 (16.7%) cases, while Mirizzi's syndrome, severely scarred or shrunken gallbladder, and abnormal biliary anatomy were observed in 2 (6.7%), 1 (3.3%), and 1 (3.3%) cases, respectively. Overall, the findings indicate that inflammatory disease, difficult dissection, intraoperative bleeding, and distorted or unclear biliary anatomy were frequently observed among patients presenting with BDI. However, as the present study included patients with BDI without a non-BDI comparison group, these findings should be interpreted as factors observed among affected patients rather than independently established causal risk factors.

The present study demonstrated that abdominal pain was the most common clinical presentation of bile duct injury, occurring in 29 (96.7%) patients, followed by intra-abdominal collection in 27 (90.0%), while cholangitis and biliary peritonitis were each observed in 18 (60.0%) patients. These findings are consistent with Wu et al who reported abdominal pain in 83.0% of 210 patients with BDI, although the frequency was higher in the present study. They also reported biliary fistula in 44.3% and peritonitis in 39.6% of patients, which were comparable to the corresponding frequencies of 40.0% and 60.0%, respectively, observed in the present study.[19] Similarly, Vu et al found abdominal pain in 68.0% of postoperative BDI patients, together with jaundice in 48.0% and bile leakage in 40.0%, while peritonitis and intra-abdominal fluid collection were specifically reported among patients with bile leakage.[20] In the present study, obstructive jaundice and biliary fistula were each present in 12 (40.0%) patients, while the high frequency of intra-abdominal collection (90.0%) and peritonitis (60.0%) may reflect the substantial proportion of patients presenting with postoperative bile leakage and associated intra-abdominal inflammatory complications. Overall, the clinical presentation in the present study was broadly comparable with previous reports, with abdominal pain, bile leakage-related manifestations, intra-abdominal collection, and peritoneal or biliary infection representing prominent clinical features among patients with BDI.

In the present study, 15 (50.0%) patients had undergone one previous attempt before referral, while 3 (10.0%) had undergone two attempts and 12 (40.0%) had received no previous intervention. This pattern is comparable with Sicklick et al who reported that 81 patients underwent 90 procedures attempting repair before referral, with the number of procedures ranging from one to three and a median of one.[17] In the present study, BDI was recognized perioperatively in 6 (20.0%) patients, while 17 (56.7%) patients presented within the first month and 7 (23.3%) presented during the second to sixth months. Similarly, Sicklick et al reported that 61 (32.4%) patients had their BDI recognized during the original laparoscopic cholecystectomy, with 36 (19.1%) undergoing an immediate repair attempt, and that 58% of patients were referred within one month because of acute complications such as bile leak, biloma, or jaundice.[17] The predominance of early presentation in the present study therefore follows the pattern described by Sicklick et al. Furthermore, the finding that 60.0% of patients in the present study underwent at least one intervention before referral is relevant to the observations of de Reuver et al who found that secondary referral after primary therapeutic interventions was an independent negative predictor of outcome among patients referred to a tertiary center.[21] Overall, these findings indicate that a substantial proportion of patients with BDI undergo an initial intervention before referral and that recognition or presentation within the first month represents an important pattern in the clinical course of BDI.

In the present study, liver function tests and ultrasonography were performed in all 30 (100.0%) patients, while MRCP was used in 24 (80.0%), ERCP in 11 (36.7%), CT scan and tubogram in 3 (10.0%) patients each, and fistulogram in 2 (6.7%) patients. This demonstrates the use of multiple complementary diagnostic modalities for the evaluation and characterization of BDI. The findings are comparable with Wu et al who reported the use of biliary ultrasonography, CT, ERCP, MRC/MRCP, T-tube cholangiography, and fistula cholangiography in a 16-year series of 210 bile duct injuries.[19] In their study, BUS, CT, ERCP, and MRC/MRCP provided diagnostic information in 84.6%, 83.1%, 67.9%, and 100% of evaluated patients, respectively.[19] Similarly, Sahajpal et al. reported the use of ERCP in 41%, ultrasonography in 23%, CT in 12%, MRI in 9%, and percutaneous transhepatic cholangiography in 32% of patients undergoing repair for LC-associated BDI.[22] The frequency of ERCP and CT in the present study was relatively close to that reported by Sahajpal et al (36.7% vs 41% and 10.0% vs 12%, respectively).[22] Regarding injury classification, the present study showed Bismuth Grade 2 as the most frequent injury, occurring in 11 (36.7%) patients, followed by Grade 3 in 9 (30.0%), Grade 1 in 6 (20.0%), Grade 4 in 3 (10.0%), and Grade 5 in 1 (3.3%) patient. This distribution was broadly comparable with the E1–E5 distribution reported by Sahajpal et al particularly for Grade 3/E3 (30.0% vs

32.0%) and Grade 5/E5 (3.3% vs 3.0%).[22] The proportions of Grade 1/E1, Grade 2/E2, and Grade 4/E4 showed some variation between the studies. Overall, the present findings demonstrate a diagnostic pattern involving multiple imaging and cholangiographic modalities and an injury distribution broadly consistent with previously reported series of LC-associated BDI.

In the present study, sub-hepatic collection was the most frequent operative finding, occurring in 23 (76.7%) patients, followed by high-level stricture in 12 (40.0%) and dense adhesion and fibrosis in 8 (26.7%) patients. These findings are comparable with Mathisen et al., who reported infectious complications in 21 of 32 (70%) patients with serious bile duct injuries following laparoscopic cholecystectomy, reflecting the substantial burden of postoperative intra-abdominal inflammatory and infectious complications observed in the present study.[23] Mathisen et al also reported complete bile duct transection in 23 (72%) patients and occlusion of the right hepatic artery in 8 (25%), demonstrating that serious BDI may be accompanied by major biliary and vascular disruption.[23] In the present study, associated vascular injury was identified in 2 (6.7%) patients, while associated bowel injury was also observed in 2 (6.7%) cases. Similarly, Stewart et al described bile collections, abscesses, peritonitis, and strictures as important complications associated with BDI, with many patients requiring drainage or reconstructive procedures before definitive repair.[24] Their observation that more proximal BDI levels were associated with greater reconstructive complexity is consistent with the present finding of high-level stricture in 12 (40.0%) patients.[24] Overall, the operative findings in the present study demonstrate the frequent presence of intra-abdominal collections, fibrosis, and high-level biliary strictures, together with occasional vascular and bowel injuries, among patients presenting with BDI.

Limitations

The study limitations included relatively small sample size in comparison with the large population from which the study subjects were drawn, although the sample size was statistically calculated. Also, as the study was conducted over a period of only one year, a larger number of patients could not be included.

CONCLUSION

Bile duct injury remains a serious complication of laparoscopic cholecystectomy, often associated with difficult operative conditions and delayed clinical manifestations. In this study, injuries predominantly occurred in females and commonly presented with abdominal pain and intra-abdominal collections. Acute inflammatory conditions, difficult Calot's triangle anatomy, and impacted Hartmann's pouch stones were frequently observed, with most cases recognized within the first month. MRCP played an important role in diagnosis and injury classification, while sub-hepatic collections and high-level strictures were common operative findings.

Funding: No funding sources
Conflict of interest: None declared
Ethical approval: The study was approved by the Institutional Ethics Committee

REFERENCES

1. DeVita, Vincent T. Lawrence, Theodore S. Preface. In: DeVita, Vincent T. Lawrence, Theodore S, eds. Principles and Practice of Oncology. 8th Ed. US: CBSPD; 2008.
2. Mohandas KM. Colorectal cancer in India: controversies, enigmas and primary prevention. Indian J Gastroenterol. 2011 Jan-Feb;30(1):3-6. Ferlay J, Shin HR, Bray F, Forman D, Mathers C, Parkin DM. Estimates of worldwide burden of cancer in 2008: GLOBOCAN 2008. Int J Cancer. 2010;127:2893-917.
3. Bruce G. Wolff, James W. Fleshman. Colorectal cancer: epidemiology, etiology and molecular basis. In: Bruce G. Wolff, James W. Fleshman, eds. The ASCRS Textbook of Colon and Rectal Surgery. 2nd Ed. New York, NY: Springer; 2007.
4. DeVita, Vincent T. Lawrence, Theodore S. Preface. In: DeVita, Vincent T. Lawrence, Theodore S, eds. Principles and Practice of Oncology. 8th Ed. US: CBSPD; 2008.
5. Tjandra JJ, Clunie GJA, Kaye AH, Smith JA. Colorectal cancer. In: Joe J. Tjandra, Gordon J.A. Clunie, Andrew H. Kaye, Julian A. Smith, eds. 3rd Ed. US: Textbook of Surgery. US: Wiley-Blackwell; 2006:191.

Cite this article as: Haque MS, Hossain MT, Islam MA, Islam AKMT, Khan MNA, Arab HM, Khan MS. Patterns of presentation and risk factors in bile duct injury following laparoscopic cholecystectomy. Int Surg J 2026;13:2443-9.