International Surgery Journal
Alaiban HA et al. Int Surg J. 2026 Dec;13(12):2607-2610
https://www.ijsurgery.com
pISSN 2349-3305 | eISSN 2349-2902

DOI: https://dx.doi.org/10.18203/2349-2902.isj20264371

Case Report

An unusual presentation of perforated appendicitis: necrotizing fasciitis and enterocutaneous fistula in a child - a case report

Hissah Abdulaziz Alaiban*, Matthias Igoche Idoko, Abeer Seadan Alrashedi, Mohammed Hussein Abdelsalam Ibrahim Abdallah, Moataz Belleh Koathal, Muhammad Azhar

Department of Pediatric Surgery, King Saud Medical City, Riyadh, Saudi Arabia

Received: 13 October 2026
Accepted: 14 November 2026

***Correspondence:**
Dr. Matthias Igoche Idoko,
E-mail: igochemi@gmail.com

Copyright: © the author(s), publisher and licensee Medip Academy. This is an open-access article distributed under the terms of the Creative Commons Attribution Non-Commercial License, which permits unrestricted non-commercial use, distribution, and reproduction in any medium, provided the original work is properly cited.

ABSTRACT

Necrotizing fasciitis (NF) is a rare but life-threatening complication of perforated appendicitis in pediatric patients. The current report demonstrates a case of a 13-year-old boy presenting with severe sepsis and extensive abdominal wall necrotizing infection. Initial urgent surgical debridement and broad-spectrum antibiotic therapy were performed. On postoperative day 4, feculent discharge developed from the wound bed, confirming an enterocutaneous fistula (ECF). Exploratory laparotomy revealed a retroperitoneal/extraperitoneal perforated appendix as the primary etiology. Surgical source control via appendectomy, continued antimicrobial therapy, meticulous wound management, and subsequent split-thickness skin grafting resulted in complete recovery. This report emphasizes the need for high clinical suspicion of underlying intra-abdominal pathology in pediatric abdominal wall necrotizing infections.

Keywords: Perforated appendicitis, Necrotizing fasciitis, Enterocutaneous fistula, Pediatric surgery

INTRODUCTION

Acute appendicitis is one of the most common surgical emergencies in pediatric emergency departments. While complications such as localized abscess, phlegmon, or generalized peritonitis are well-described, extension of the inflammatory process into the retroperitoneum and anterior abdominal wall leading to necrotizing fasciitis (NF) and enterocutaneous fistula (ECF) formation is extraordinarily rare in children.[1,2]

Necrotizing fasciitis is a fulminant, life-threatening soft-tissue infection characterized by rapidly progressive necrosis of the subcutaneous tissues and fascia. When secondary to perforated appendicitis, the clinical presentation can be atypical and insidious, as extraperitoneal air and fluid tracking may mask classic intra-abdominal peritoneal signs. Prompt recognition, immediate broad-spectrum antibiotic therapy, aggressive surgical debridement, and identification of the underlying enteric source are vital to prevent mortality.

CASE REPORT

A 13-year-old previously healthy boy presented to the emergency department with a 10-day history of progressive abdominal pain and fever. Three days prior to admission, a painful, expanding wound with necrotic skin changes developed over his right lower abdomen. Medical evaluation was delayed due to social circumstances.

On initial physical examination, the patient appeared acutely ill, toxic, and severely dehydrated. Vital signs demonstrated marked tachycardia (heart rate 139 beats/min), high fever (body temperature 40°C), blood pressure of 120/30 mmHg, and an initial urine output of 1 mL/kg/h. Local examination revealed a large,

approximately 4×5 cm necrotic wound in the right iliac fossa involving skin and subcutaneous tissues, with copious foul-smelling purulent discharge tracking posterolaterally toward the paraspinal area and anteriorly to the suprapubic region (Figure 1). Bowel contents were not initially visible. Abdominal palpation revealed a soft, non-tender abdomen without signs of generalized peritonitis.



Figure 1: Initial clinical presentation showing extensive right iliac fossa necrotizing soft-tissue infection with severe tissue necrosis and foul-smelling purulent exudate.

Laboratory evaluations confirmed marked systemic inflammatory response and infection: leukocytosis with a white blood cell count (WBC) of $31\times10^3/\mu l$, Hemoglobin 10.0 g/dl, Platelet count $851\times10^3/\mu l$, and C-reactive protein (CRP) elevated at 131 mg/l.

Following intravenous fluid resuscitation and commencement of broad-spectrum empiric parenteral antibiotics, the patient underwent urgent surgical wound exploration and radical soft-tissue debridement. Intraoperatively, a large purulent cavity was identified, tracking extensive subcutaneous tissues posteriorly toward the lumbar zone and anteriorly toward the suprapubic area. The underlying abdominal musculature was markedly inflamed and friable, oozing with minor manipulation, though no gross full-thickness abdominal wall defect was observed. Aggressive debridement of devitalized skin, fat, and fascia was executed.

Postoperatively, daily wound dressings were initiated alongside IV antibiotics. The patient showed initial hemodynamic stabilization, fever resolution, and declining inflammatory markers while tolerating enteral diet and passing normal bowel movements per rectum. However, on postoperative day 4, active feculent discharge was noted originating from a small central defect in the right iliac fossa wound, confirming the formation of an enterocutaneous fistula.

Given his systemic stability and soft abdomen, conservative non-operative management for a controlled fistula was initiated with total parenteral nutrition (TPN), IV antibiotics, and meticulous wound care. Computed tomography (CT) of the abdomen and pelvis (Figure 2) demonstrated extensive abdominal wall inflammatory changes, subcutaneous skin defect/gas tracking, and fecal loading in the right colon. Vacuum-assisted closure (VAC) therapy was considered but deferred due to proximity and risk of direct bowel exposure.

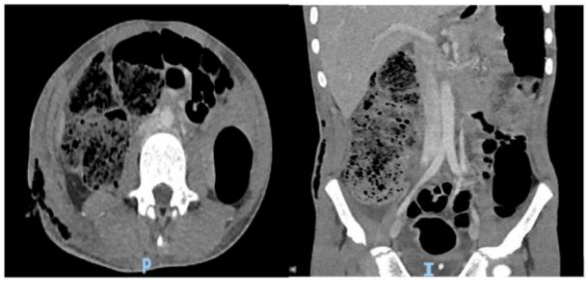

Figure 2: Computed tomography (CT) scan showing extensive inflammatory changes in the abdominal wall, subcutaneous skin defect with gas extension posteriorly and anteriorly, and heavy fecal loading in the right-sided colon.

Despite non-operative optimization, persistent fecal contamination hampered local wound granulation and closure. Therefore, exploratory laparotomy was performed. Intraoperatively, a perforated mid-body appendix was identified, surrounded by inflammatory exudate and dense granulation tissue predominantly localized to the extraperitoneal/preperitoneal space of the right iliac fossa, with a visible part of the base of the appendix associated with underlying abdominal wall involvement (Figure 3). The remainder of the peritoneal cavity and bowel loop structures were clean and uninvolved.



Figure 3: Intraoperative view showing abdominal wall involvement with visualization of the base of the perforated appendix (arrow).

Appendectomy with local preperitoneal debridement was performed. The fascial defect was closed in layers, leaving the superficial subcutaneous wound open for secondary healing. Following clinical stabilization, the plastic surgery service performed split-thickness skin grafting (STSG) over the remaining tissue defect.

The patient had an uncomplicated recovery following skin grafting and was discharged in stable condition. At follow-up examination, the skin graft demonstrated complete incorporation and excellent functional and cosmetic healing of the right lower abdominal wall (Figure 4). He successfully resumed all normal daily physical activities without restriction.



Figure 4: Postoperative clinical outcome showing complete graft incorporation, healthy scarring, and well-healed right iliac fossa abdominal wall following split-thickness skin graft (STSG) reconstruction.

DISCUSSION

Acute appendicitis presenting as abdominal wall necrotizing fasciitis (NF) and secondary enterocutaneous fistula (ECF) represents a formidable diagnostic and therapeutic challenge.[1,2] While untreated appendicitis usually manifests as localized perforation, abscess formation, or diffuse peritonitis, retrocaecal or extraperitoneal anatomical variations of the appendix allow inflammatory exudates to dissect along fascial planes into the anterior abdominal wall without violating the peritoneal cavity.[3-5]

Translocation of enteric flora through inflamed viscera into fascial planes leads to polymicrobial soft-tissue destruction characteristic of Type I NF.[6,7] The subtle initial cutaneous signs can mimic simple cellulitis or localized abscess, contributing to diagnostic delays, especially in previously healthy pediatric patients without classical comorbidities like diabetes mellitus or immunosuppression.[8]

In this patient, the absence of peritonitis on physical examination initially pointed toward a primary soft-tissue infection. The emergence of feculent drainage on postoperative day 4 served as the critical diagnostic clue for an underlying enteric communication. Management required a multi-phase surgical strategy: initial emergency debridement for infection control, followed by definitive exploratory laparotomy and appendectomy to remove the persistent source of enteric spillage, and lastly, plastic surgical reconstruction via split-thickness skin graft.[9,10]

CONCLUSION

Perforated appendicitis disguised as abdominal wall necrotizing fasciitis and enterocutaneous fistula is a life-threatening pediatric emergency. Clinicians must maintain a high index of suspicion for an underlying intra-abdominal source in cases of lower abdominal soft-tissue necrosis, even when classic peritoneal signs are absent. Early radical debridement, timely laparotomy for surgical source control, and multidisciplinary wound reconstruction are indispensable for optimal clinical recovery.

Funding: No funding sources
Conflict of interest: None declared
Ethical approval: Not required

REFERENCES

1. Chen CW, Hsiao CW, Wu CC, Jao SW, Lee TY, Kang JC. Necrotizing fasciitis due to acute perforated appendicitis: case report. J Emerg Med. 2010;39(2):178-80.
2. Iqbal RS, Gohar A, Azhar R, Tahir S, Afzal U, Ayyan A, et al. A rare case of necrotizing fasciitis secondary to a perforated appendix. Ann Med Surg (Lond). 2025;87(2):994-7.
3. AlRamahi RW, Woerner A, Rizvi H, Monroe EJ. Complicated appendicitis in the pediatric patient: interventional perspectives. Clin Imaging. 2025;118:110371.
4. Falconi S, Wilhelm C, Loewen J, Soliman B. Necrotizing fasciitis of the abdominal wall secondary to complicated appendicitis: a case report. Cureus. 2023;15(5):e39635.
5. Phutong N. Enterocutaneous fistula secondary to complicated appendicitis in children: case report. EC Paediatr. 2023;12(4):14-5.
6. Kewan T, Alwehaibi A, Albalawi A, et al. Bacterial translocation in complicated intra-abdominal infections and soft tissue extension. World J Clin Cases. 2022;10(15):4890-8.
7. Szilagyi J, Kuester V, Reznicek J. Pediatric necrotizing fasciitis. JPOSNA. 2023;5(4):728.
8. Mustafa AD, Varshney K, Rao T, Shet P, Rao L, Ghosh P, et al. Necrotising fasciitis in patients with diabetes: a systematic review of mortality-associated clinical factors. Int Wound J. 2026;23(2):e70844.
9. Guliyeva G, Huayllani MT, Sharma NT, Janis JE. Practical review of necrotizing fasciitis: principles

and evidence-based management. Plast Reconstr Surg Glob Open. 2024;12(1):e5533.
10. Kobayashi N, Toyama S, Yoshida H, Shiraso S. Necrotizing fasciitis wound after debridement could be successfully treated with negative-pressure wound therapy: a case report. Trauma Case Rep. 2023;48:100957.

Cite this article as: Alaiban HA, Idoko MI, Alrashedi AS, Abdallah MHAI, Koathal MB, Azhar M. An unusual presentation of perforated appendicitis: necrotizing fasciitis and enterocutaneous fistula in a child - a case report. Int Surg J 2026;13:2607-10.