International Surgery Journal
Sadhu MV et al. Int Surg J. 2026 Dec;13(12):2493-2499
https://www.ijsurgery.com
pISSN 2349-3305 | eISSN 2349-2902

DOI: https://dx.doi.org/10.18203/2349-2902.isj20264356

Original Research Article

Lichtenstein mesh hernioplasty without drain for uncomplicated inguinal hernia: a prospective observational study of 30 cases

Meetkumar V. Sadhu, Alimamad O. Noyda*

Department of General Surgery, Shri M. P. Shah Government Medical College and Guru Gobind Singh Government Hospital, Jamnagar, Gujarat, India

Received: 10 October 2026
Accepted: 07 November 2026

***Correspondence:**
Dr. Alimamad O. Noyda,
E-mail: draonoyda@gmail.com

Copyright: © the author(s), publisher and licensee Medip Academy. This is an open-access article distributed under the terms of the Creative Commons Attribution Non-Commercial License, which permits unrestricted non-commercial use, distribution, and reproduction in any medium, provided the original work is properly cited.

ABSTRACT

Background: Closed suction drains are still placed after open inguinal hernia repair in many Indian centers to prevent seroma and hematoma, although their benefit in uncomplicated hernias is uncertain. This study evaluated the outcome of Lichtenstein mesh hernioplasty performed without a drain.
Methods: This prospective observational study included 30 adults with uncomplicated primary inguinal hernia who underwent elective open Lichtenstein mesh hernioplasty without a drain at a tertiary care teaching hospital in Jamnagar, Gujarat, between August 2025 and March 2026. Clinical profile, sonographic findings, operative time, postoperative complications, hospital stay and recurrence were recorded and analyzed descriptively.
Results: All patients were men, with a mean age of 57.67±17.95 years; 63.33% were aged 60 years or older. The hernia was right-sided in 50.00%, left-sided in 36.67% and bilateral in 13.33%, and it was clinically indirect in 53.33% and direct in 46.67%. Mean defect size on ultrasonography was 2.10±0.46 cm. Mean operative time was 94.8±22.0 minutes. Twenty-three patients (76.67%) had an uneventful recovery. Seroma developed in four patients (13.33%), hematoma in two (6.67%) and surgical site infection in one (3.33%). There was no wound dehiscence, septicaemia, recurrence or death. Mean postoperative hospital stay was 3.77±1.14 days.
Conclusions: Lichtenstein mesh hernioplasty without a drain was safe for uncomplicated inguinal hernia, with mostly minor wound complications and no recurrence. Routine drain placement does not appear necessary; drains may be reserved for selected high-risk repairs.

Keywords: Inguinal hernia, Lichtenstein hernioplasty, Mesh repair, Surgical drain, Seroma, Surgical site infection

INTRODUCTION

Inguinal hernia is one of the most common conditions treated by general surgeons, and more than 20 million groin hernia repairs are performed worldwide each year.[1] The lifetime risk is about 27% in men and 3% in women, and the incidence rises with age.[2,3] Weakness of the abdominal wall combined with raised intra-abdominal pressure from chronic cough, constipation, straining at micturition and heavy work contributes to its development.[3,4]

Tension-free mesh repair has replaced tissue repair because it reduces recurrence, and the open Lichtenstein technique remains the recommended open approach for primary unilateral inguinal hernia.[1,5-7] Its common early complications are seroma, hematoma and surgical site infection.[8,9] Closed suction drains have traditionally been placed to evacuate blood and serous fluid from the dissected space and to prevent these complications.[10]

The value of routine drainage after open inguinal hernia repair has been questioned. Randomized trials and a large

meta-analysis of subcutaneous drainage found little benefit in uncomplicated wounds, and registry data show that drains are now used mainly in patients at higher risk of complications.[11-14] A drain may add discomfort and delay discharge, and Indian comparative studies report conflicting results.[15,16] Many surgical units in India, however, still use drains routinely. This study evaluated the clinical profile, operative details and postoperative outcome of patients with uncomplicated inguinal hernia who underwent Lichtenstein mesh hernioplasty without a drain.

METHODS

Study design and setting

This prospective observational study was conducted in the department of general surgery, Shri M. P. Shah Government Medical College and Guru Gobind Singh Government Hospital, Jamnagar, Gujarat, India, from August 2025 to March 2026.

Participants

Adults older than 18 years with uncomplicated primary inguinal hernia (direct, indirect or pantaloon) scheduled for elective open mesh hernioplasty were enrolled after written informed consent. Patients with irreducible, obstructed or strangulated hernia, recurrent hernia, or a second procedure planned with the hernia repair, and those who declined to participate, were excluded. All eligible patients operated during the study period were included, giving a sample of 30.

Preoperative evaluation

A structured case record form was used to record age, weight, occupation, duration of swelling, local pain, associated complaints (chronic cough, constipation, urinary complaints, nausea and vomiting), past surgery, comorbidities and personal habits. Local examination recorded the side, shape and extent of the swelling, reducibility and cough impulse. The hernia was classified clinically as indirect or direct by the deep ring occlusion test and the invagination test. Investigations included hemoglobin, total leukocyte count, blood sugar, renal function and coagulation profile. Ultrasonography of the inguinal region and abdomen was performed to measure the defect size, identify the content of the sac and exclude associated intra-abdominal pathology.

Surgical procedure

All patients underwent open Lichtenstein tension-free hernioplasty with polypropylene mesh under spinal or regional anesthesia, following the standard technique.5,6 No drain was placed in any patient. All patients received intravenous amoxicillin-clavulanic acid 1.2 g before surgery and oral amoxicillin-clavulanic acid 625 mg after surgery.

Outcomes

The primary outcomes were postoperative seroma, hematoma and surgical site infection. Secondary outcomes were operative time, septicemia, wound dehiscence, preoperative, postoperative and total hospital stay, recurrence during follow-up, and mortality. Hospital stay was calculated from the dates of admission, operation and discharge.

Statistical analysis

Data were entered in Microsoft Excel and analyzed descriptively. Continuous variables were expressed as mean±standard deviation with range, and categorical variables as frequency and percentage.

RESULTS

All 30 patients were men, with a mean age of 57.67±17.95 years (range 20 to 85 years); 19 (63.33%) were aged 60 years or older, and the largest group was 60 to 69 years (40.00%). Mean body weight was 67.17±9.09 kg. Retired persons formed the largest occupational group (30.00%). The swelling had been present for one month or less in 13 patients (43.33%) and for one year or more in 12 (40.00%), and 18 patients (60.00%) reported local pain. Constipation and urinary complaints were each present in 20.00% and chronic cough in 13.33%. Five patients (16.67%) had undergone hydrocele surgery and three (10.00%) appendectomy. Diabetes mellitus and hypertension were each present in 20.00%, and 16 patients (53.33%) smoked (Table 1).

The hernia was right-sided in 15 patients (50.00%), left-sided in 11 (36.67%) and bilateral in four (13.33%) (Figure 1). Every hernia was reducible with a cough impulse and normal overlying skin. The swelling extended into the scrotum in 18 patients (60.00%). On clinical testing, 16 hernias (53.33%) were indirect and 14 (46.67%) direct; the deep ring occlusion and invagination tests agreed in every patient. Ultrasonography showed omentum in the sac in 19 patients (63.33%) and bowel loops in 11 (36.67%), with a mean defect size of 2.10±0.46 cm (range 1.2 to 3.5 cm). No associated intra-abdominal pathology was detected. Mean hemoglobin was 13.49±1.28 g/dL and mean fasting blood sugar 111.13±19.73 mg/dL (Table 2).

All patients underwent open Lichtenstein mesh hernioplasty without a drain. The mean operative time was 94.8±22.0 minutes (range 54 to 120 minutes), and 19 procedures (63.33%) lasted 90 minutes or more. Twenty-three patients (76.67%) recovered without any complication. Seroma developed in four patients (13.33%), hematoma in two (6.67%) and surgical site infection in one (3.33%), giving an overall complication rate of 23.33% (Figure 2). Four of the seven complications occurred in patients whose hernial sac contained bowel loops. No patient developed septicemia

or wound dehiscence, and no recurrence or death was recorded (Table 3). The mean preoperative stay was 2.27±0.69 days, the mean postoperative stay 3.77±1.14 days (range 2 to 6 days) and the mean total hospital stay 6.03±1.30 days (range 4 to 10 days). Half of the patients (50.00%) were discharged on the fourth postoperative day, and 10 (33.33%) were discharged within three days (Table 3 and Figure 3).

Table 1: Demographic profile and clinical presentation of the study participants (n=30).

Variables	Number of patients (%)
Age group (years)	
20-29	3 (10.00%)
30-39	3 (10.00%)
40-49	2 (6.67%)
50-59	3 (10.00%)
60-69	12 (40.00%)
70-79	3 (10.00%)
80-89	4 (13.33%)
Mean±SD (range)	57.67±17.95 (20-85)
Sex	
Male	30 (100.00%)
Body weight, mean±SD (kg)	67.17±9.09
Occupation	
Retired	9 (30.00%)
Business or self-employed	6 (20.00%)
Farmer or agricultural worker	4 (13.33%)
Service or salaried job	4 (13.33%)
Laborer	4 (13.33%)
Student	3 (10.00%)
Duration of swelling	
1 month or less	13 (43.33%)
More than 1 month to less than 1 year	5 (16.67%)
1 to 3 years	12 (40.00%)
Symptoms	
Local pain	18 (60.00%)
Constipation	6 (20.00%)
Urinary complaints	6 (20.00%)
Chronic cough	4 (13.33%)
Nausea and vomiting	3 (10.00%)
Past surgical history	
Hydrocele surgery	5 (16.67%)
Appendectomy	3 (10.00%)
None	22 (73.33%)
Comorbidities	
Diabetes mellitus	6 (20.00%)
Hypertension	6 (20.00%)
Ischemic heart disease	1 (3.33%)
Past tuberculosis	1 (3.33%)
Habits*	
Smoking	16 (53.33%)
Tobacco chewing	11 (36.67%)
Alcohol	7 (23.33%)
None	6 (20.00%)

*Habits are not mutually exclusive. SD: standard deviation.

Table 2: Examination, investigation and sonographic findings (n=30).

Variables	Number of patients (%)
Side of hernia	
Right	15 (50.00%)
Left	11 (36.67%)
Bilateral	4 (13.33%)
Shape of swelling	
Oval	19 (63.33%)
Globular	11 (36.67%)
Extent of swelling	
Extending into the scrotum	18 (60.00%)
Confined to the inguinal region	12 (40.00%)
Clinical type*	
Indirect	16 (53.33%)
Direct	14 (46.67%)
Other findings	
Reducible with cough impulse	30 (100.00%)
Gurgling on auscultation	8 (26.67%)
Palpable peristalsis	4 (13.33%)
Content of sac on ultrasonography	
Omentum	19 (63.33%)
Bowel loops	11 (36.67%)
Defect size on ultrasonography (cm)	
Less than 2.0	10 (33.33%)
2.0-2.9	18 (60.00%)
3.0 or more	2 (6.67%)
Mean±SD (range)	2.10±0.46 (1.2-3.5)
Investigations, mean±SD	
Hemoglobin (g/dl)	13.49±1.28
Total leukocyte count (cells/µl)	8624±1239
Fasting blood sugar (mg/dl)	111.13±19.73
Postprandial blood sugar (mg/dl)	165.47±27.32

*Based on the deep ring occlusion and invagination tests, which agreed in all patients. SD: standard deviation.

Table 3: Operative details and postoperative outcome (n=30).

Variables	Number of patients (%)
Operation	
Open Lichtenstein mesh hernioplasty	30 (100.00%)
Drain placed	0 (0.00%)
Operative time (minutes)	
Less than 90	11 (36.67%)
90-120	19 (63.33%)
Mean±SD (range)	94.8±22.0 (54-120)
Postoperative complications	
None	23 (76.67%)
Seroma	4 (13.33%)
Hematoma	2 (6.67%)
Surgical site infection	1 (3.33%)
Septicemia	0 (0.00%)
Wound dehiscence	0 (0.00%)
Hospital stay (days), mean±SD (range)	
Preoperative	2.27±0.69 (1-4)
Postoperative	3.77±1.14 (2-6)
Total	6.03±1.30 (4-10)

Continued.

Variables	Number of patients (%)
Late outcome	
Recurrence	0 (0.00%)
Mortality	0 (0.00%)

SD: standard deviation.

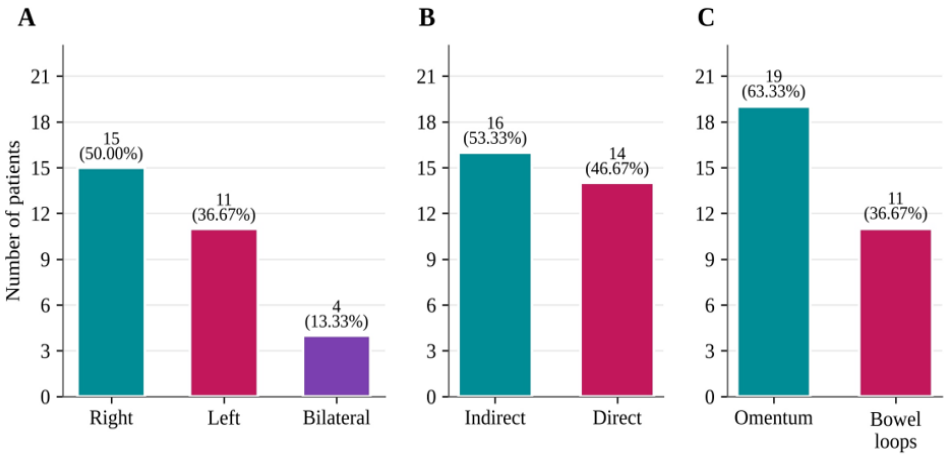

Figure 1: Distribution of the study participants by (A) side of hernia (B) clinical type and (C) content of the hernial sac on ultrasonography (n=30).

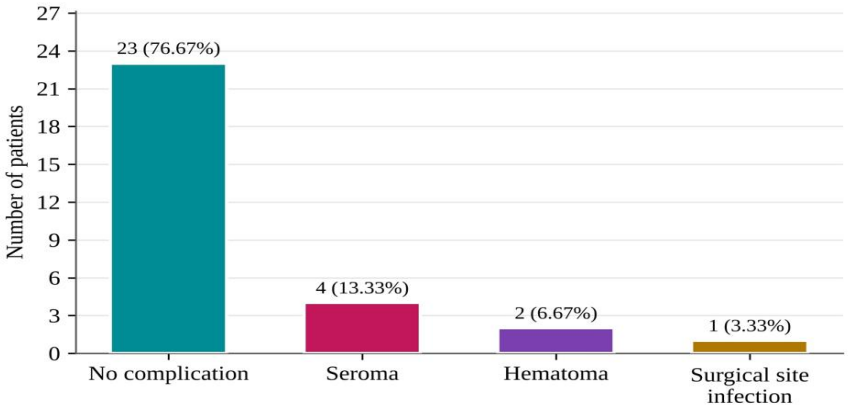

Figure 2: Postoperative complications after lichtenstein mesh hernioplasty without drain (n=30).

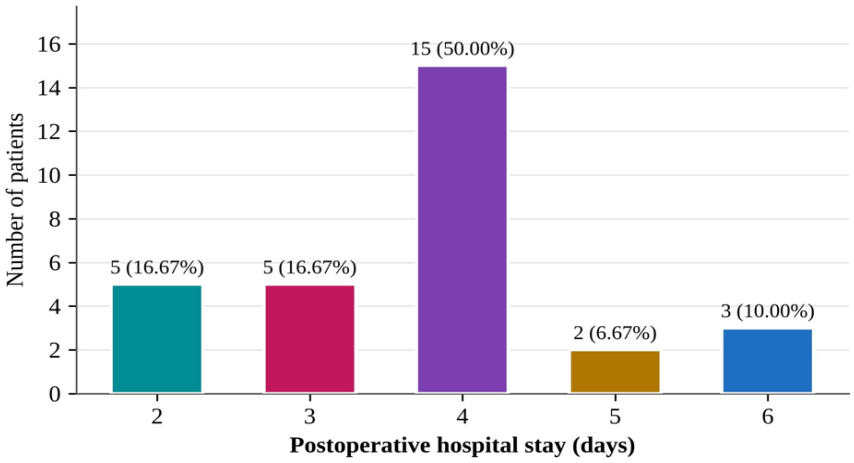

Figure 3: Distribution of postoperative hospital stay (n=30).

DISCUSSION

This prospective series describes 30 men with uncomplicated inguinal hernia treated by Lichtenstein mesh hernioplasty without a drain in a public teaching hospital in western India. Three in four patients recovered without any complication, the complications that did occur were wound-related and minor, and there was no septicemia, recurrence or death. The patients were older men, nearly two thirds of whom were 60 years or older. Inguinal hernia is predominantly a disease of men, and its incidence rises steadily with age.[2,3] Right-sided hernias were more common than left-sided ones, as in other series of Lichtenstein repair.[8] Indirect hernias were slightly more frequent than direct hernias, but the proportion of direct hernias (46.67%) was higher than the 30.0% to 38.4% reported in other series, which is consistent with the older age of our patients.[8,9] The type was assigned clinically, and clinical examination is known to be unreliable in distinguishing direct from indirect hernia.[17] Ultrasonography has high sensitivity for groin hernia and was useful here for measuring the defect and identifying the sac content.[18] Constipation, urinary complaints and chronic cough were common and reflect the contribution of raised intra-abdominal pressure.[3,4] More than half of the patients smoked, which matters because smoking is a risk factor for recurrence after groin hernia repair.[19]

The main argument for a drain is prevention of seroma and hematoma. Seroma developed in 13.33% and hematoma in 6.67% of our patients. These rates are higher than the 3.6% seroma and 1.8% hematoma reported by Khan et al and the small numbers of collections needing drainage in the series of Sakorafas et al.[8,9] Definitions differ between studies, however, and in our series every clinically detected collection was recorded as a complication, whereas several series count only collections that need aspiration or drainage. Scrotal extension was present in 60.00% of our patients, and drains have traditionally been favored after this more extensive dissection.[10,13] Postoperative hematoma has been associated mainly with anticoagulant use and cardiovascular disease rather than with the type of hernia or repair, and its reported frequency in large series is about 1%.[20,21]

The evidence on drainage after open repair does not support routine use. In a randomized trial of 301 men, Beacon et al found that suction drainage reduced wound complications only in complicated hernias, with no significant difference in simple hernias.[10] In a randomized trial after Shouldice repair, Peiper et al found no indication for a routine subcutaneous drain in primary inguinal hernia, and a meta-analysis of 52 randomized trials of prophylactic subcutaneous drainage showed no advantage outside breast biopsy and axillary dissection.[11,12] In the Herniamed registry of 98,321 men, drains were used in about a quarter of primary repairs, mostly in older, higher-risk patients and those with larger or scrotal hernias, and their use was associated with more complications.[13] Ergül et al similarly reported that drains were placed in 8.3% of open mesh repairs, mainly in patients receiving anticoagulants, with recurrent hernia or after longer operations.[14] Indian comparative studies are divided. Ramesh found similar rates of seroma, hematoma and wound infection with and without a suction drain, but a longer postoperative stay with a drain (9.7 versus 6.7 days), whereas Kalaskar et al reported fewer seromas and hematomas with a drain and no significant difference in wound infection.[15,16] Drains do reduce seroma after totally extraperitoneal repair, where the preperitoneal dead space is larger, but this finding cannot be extended to open onlay repair.[22] Surgical site infection occurred in only one patient (3.33%), which is within the rate of less than 5% expected for clean surgery.[23] All our patients received preoperative and postoperative antibiotics. A Cochrane review found that prophylaxis probably makes little or no difference to wound infection in low-risk settings, although it may benefit patients in high-risk environments, and international guidelines do not recommend prophylaxis for average-risk patients undergoing open repair in low-risk settings.[1,23] Restricting antibiotics to a single preoperative dose would be consistent with antimicrobial stewardship. The mean postoperative stay of 3.77 days reflects institutional practice in a public hospital that serves many patients from distant rural areas rather than a clinical need. Absence of a drain removes one reason for delaying discharge, and international guidelines support day-case surgery for most patients undergoing elective inguinal hernia repair.[1] No recurrence was recorded, which agrees with the very low recurrence after Lichtenstein repair, but recurrence and chronic postoperative pain develop over months to years and need longer follow-up.[9,24]

This study has limitations. It was a small single-center series without a control group of patients managed with a drain, so it cannot show that omission of the drain caused or prevented any complication. The hernia type was assigned clinically and was not confirmed and recorded at operation. Postoperative pain was not measured with a standardized scale, seromas were not graded or measured by ultrasonography, and follow-up was too short to assess recurrence and chronic pain.

CONCLUSION

Lichtenstein mesh hernioplasty without a drain was safe for uncomplicated primary inguinal hernia in this series. Most patients recovered without complication, the complications that occurred were minor wound collections and a single wound infection, and there was no septicemia, recurrence or death. Routine drain placement does not appear necessary in uncomplicated open mesh repair; drains may be reserved for selected patients, such as those with large inguinoscrotal hernias, extensive dissection or anticoagulant therapy.

Randomized studies with longer follow-up are needed to define these indications.

ACKNOWLEDGEMENTS

The authors thank the faculty and residents of the Department of General Surgery and the Department of Anesthesiology, the nursing staff of Guru Gobind Singh Government Hospital, Jamnagar, and the patients who participated in this study.

Funding: No funding sources
Conflict of interest: None declared
Ethical approval: The study was approved by the Institutional Ethics Committee

REFERENCES

1. HerniaSurge Group. International guidelines for groin hernia management. Hernia. 2018;22(1):1-165.
2. Kingsnorth A, LeBlanc K. Hernias: inguinal and incisional. Lancet. 2003;362(9395):1561-71.
3. Ruhl CE, Everhart JE. Risk factors for inguinal hernia among adults in the US population. Am J Epidemiol. 2007;165(10):1154-61.
4. Jenkins JT, O'Dwyer PJ. Inguinal hernias. BMJ. 2008;336(7638):269-72.
5. Lichtenstein IL, Shulman AG, Amid PK, Montllor MM. The tension-free hernioplasty. Am J Surg. 1989;157(2):188-93.
6. Amid PK. Lichtenstein tension-free hernioplasty: its inception, evolution, and principles. Hernia. 2004;8(1):1-7.
7. EU Hernia Trialists Collaboration. Mesh compared with non-mesh methods of open groin hernia repair: systematic review of randomized controlled trials. Br J Surg. 2000;87(7):854-9.
8. Khan N, Naeem M, Bangash A, ullah A, Sadiq M, Hamid H. Early outcome of Lichtenstein technique of tension-free open mesh repair for inguinal hernia. J Ayub Med Coll Abbottabad. 2008;20(4):29-33.
9. Sakorafas GH, Halikias I, Nissotakis C, Kotsifopoulos N, Stavrou A, Antonopoulos C, et al. Open tension-free repair of inguinal hernias: the Lichtenstein technique. BMC Surg. 2001;1:3.
10. Beacon J, Hoile RW, Ellis H. A trial of suction drainage in inguinal hernia repair. Br J Surg. 1980;67(8):554-5.
11. Peiper C, Conze J, Ponschek N, Schumpelick V. Value of subcutaneous drainage in repair of primary inguinal hernia: a prospective randomized study of 100 cases. Chirurg. 1997;68(1):63-7. German.
12. Kosins AM, Scholz T, Cetinkaya M, Evans GRD. Evidence-based value of subcutaneous surgical wound drainage: the largest systematic review and meta-analysis. Plast Reconstr Surg. 2013;132(2):443-50.
13. Köckerling F, Hantel E, Adolf D, Stechemesser B, Niebuhr H, Lorenz R, et al. Do drains have an impact on the outcome after primary elective unilateral inguinal hernia repair in men? Hernia. 2020;24(5):1083-91.
14. Ergül Z, Akinci M, Yilmaz KB, Sahin A, Seker G, Kulaçoğlu H. Why do we use drains in some inguinal hernia repairs? Chirurgia (Bucur). 2011;106(6):769-74.
15. Ramesh D. A comparative study of hernioplasty with suction drain and without suction drain in inguinal hernias at tertiary care hospital. Indian J Public Health Res Dev. 2022;13(4):91-5.
16. Kalaskar N, Patil BC, Vignesh M. A comparative study of minivac suction drain in Lichtenstein tension-free mesh inguinal hernioplasty at Basaweshwar teaching and general hospital, Kalaburagi, Karnataka. Asian J Med Sci. 2025;16(7):168-72.
17. Cameron AE. Accuracy of clinical diagnosis of direct and indirect inguinal hernia. Br J Surg. 1994;81(2):250.
18. Robinson A, Light D, Nice C. Meta-analysis of sonography in the diagnosis of inguinal hernias. J Ultrasound Med. 2013;32(2):339-46.
19. Sorensen LT, Friis E, Jorgensen T, Vennits B, Andersen BR, Rasmussen GI, et al. Smoking is a risk factor for recurrence of groin hernia. World J Surg. 2002;26(4):397-400.
20. Zeb MH, Pandian TK, El Khatib MM, Naik ND, Chandra A, Morris DS, et al. Risk factors for postoperative hematoma after inguinal hernia repair: an update. J Surg Res. 2016;205(1):33-7.
21. Smoot RL, Oderich GS, Taner CB, Greenlee SM, Larson DR, Cragun EB, et al. Postoperative hematoma following inguinal herniorrhaphy: patient characteristics leading to increased risk. Hernia. 2008;12(3):261-5.
22. Prassas D, Zaczek M, David SO, Knoefel WT, Vaghiri S. Routine closed-suction drainage reduces seromas following totally extraperitoneal (TEP) inguinal hernia repair: a meta-analysis. Medicine (Baltimore). 2024;103(11):e37412.
23. Orelio CC, van Hessen C, Sanchez-Manuel FJ, Aufenacker TJ, Scholten RJ. Antibiotic prophylaxis for prevention of postoperative wound infection in adults undergoing open elective inguinal or femoral hernia repair. Cochrane Database Syst Rev. 2020;4(4):CD003769.
24. Alfieri S, Amid PK, Campanelli G, Izard G, Kehlet H, Wijsmuller AR, et al. International guidelines for prevention and management of postoperative chronic pain following inguinal hernia surgery. Hernia. 2011;15(3):239-49.

Cite this article as: Sadhu MV, Noyda AO. Lichtenstein mesh hernioplasty without drain for uncomplicated inguinal hernia: a prospective observational study of 30 cases. Int Surg J 2026;13:2493-9.