International Surgery Journal
Ambalam S et al. Int Surg J. 2026 Dec;13(12):2504-2509
https://www.ijsurgery.com
pISSN 2349-3305 | eISSN 2349-2902

DOI: https://dx.doi.org/10.18203/2349-2902.isj20264358

Original Research Article

Successful management of isolated iliac artery aneurysms

Sakthinesh Ambalam[1]*, Sritharan Narayanan[1], K. Jayachander[1], Ilayakumar Paramasivam[1], Vaisagh Remin[1], M. Hariprakash[1], Essakiraja Kanagasabapathy[2]

[1]Institute of Vascular Surgery, Madras Medical College and RGGGH, Chennai, Tamil Nadu, India
[2]Institute of Community Medicine, Madurai Medical College , Madurai, Tamil Nadu, India

Received: 09 October 2026
Revised: 07 November 2026
Accepted: 17 November 2026

***Correspondence:**
Dr. Sakthinesh Ambalam,
E-mail: asakthinesh@gmail.com

Copyright: © the author(s), publisher and licensee Medip Academy. This is an open-access article distributed under the terms of the Creative Commons Attribution Non-Commercial License, which permits unrestricted non-commercial use, distribution, and reproduction in any medium, provided the original work is properly cited.

ABSTRACT

Background: Iliac arteries are defined as aneurysmal when their diameter is 1.5 times the normal or expected diameter. Isolated iliac artery aneurysms occur with an incidence of around 0.03% globally in the general population. This study aims to study the etiology, risk factors, location, clinical presentation, and management of isolated iliac artery aneurysms.
Methods: This was a retrospective study of 23 isolated iliac artery aneurysm patients admitted in Institute of Vascular Surgery, Madras Medical College, Chennai from May 2012 to May 2026. Details such as age, gender, etiology, risk factors, clinical features, location, size of aneurysm, management and complications after treatment were collected. Data was analysed using Statistical Package for Social Sciences (SPSS) Version 26.0.
Results: Among those with isolated iliac artery aneursyms, majority were males (86.9%) and majority were in the age group of 51-70 years of age (69.6%). Smoking (69.6%) was the most common risk factor followed by hypertension (52.1%). Most of the cases of aneursyms were due to degenerative etiology (82.7%). Common iliac artery (CIA) (78.2%) was solely involved in majority of cases of isolated iliac artery aneursyms. Aneursym patients more commonly presented with abdominal pain (73.9%) followed by pulsatile mass (26.1%). 20 patients were operated by open surgery and 3 patients were operated by endovascular procedure.
Conclusions: Isolated iliac artery aneurysms are uncommon with CIA being the most common segment involved. The most common risk factors are smoking and hypertension. Results of both open surgery and endovascular management seems to be good.

Keywords: Aneursym, Common iliac artery, External iliac artery, Internal iliac artery

INTRODUCTION

An iliac artery dilatation of 1.5 times the usual diameter is defined as an iliac artery aneurysm (IAA). Common iliac artery (CIA) is said to be ectatic when diameter is >18 mm in men and >15 mm in women. Common iliac artery is said to be aneurysmal when diameter is >25 mm in both men and women. Internal iliac artery (IIA) with diameter >8 mm in both men and women is said to be ectatic. Solitary iliac aneurysms include aneurysms of the CIA, IIA, external iliac artery (EIA), or combinations of those. The 10% of cases are linked to Aneurysms of the Abdominal Aorta (AAA). The sciatic artery system is the source of both the CIA and the IIA, while the EIA comes from ilio femoral system. Due to this different embryological genesis, a solitary aneurysm of the EIA is extremely uncommon.[1,2] In 10% to 20% of cases, iliac aneurysms and abdominal aortic aneurysms coexist, a

condition known as aorto-iliac aneurysm. However, solitary iliac artery aneurysms are uncommon, accounting for between 0.4% and 1.9% of all aneurysmal diseases. It is estimated that 0.03% of the general population has isolated iliac artery aneurysm thus making this a rare clinical condition.[3]

There is uncertainty regarding the pathophysiology of isolated IAAs. It seems that the multifactorial pathology involves mechanisms akin to those in aortic disease. Proteolytic degradation of aortic wall connective tissue, inflammation, biomechanical wall stress, and molecular genetics are some of the mechanisms associated with the development of abdominal aortic aneurysms that may be linked to iliac aneurysmal illness.

Infection, trauma, arteritis, collagen vascular disorders, and other are less frequent causes of IAAs. The degenerative mechanism that causes the artery wall to dilate as a result of the rupture of the extracellular matrix is triggered by combination of genetic, metabolic, anatomical, and environmental variables.

The nondegenerative causes include congenital conditions such as Marfan disease, infection-related aneurysm, mycotic aneurysm and pseudoaneurysm (which is more frequently an iatrogenic occurrence following prior endovascular treatment). IAA are more frequent in males (90%) with an incidence higher in the VII and VIII decades.[2,3] This study aims to study the clinical presentation, risk factors, etiology, location, management and post-operative complications of isolated iliac artery aneurysms.

METHODS

This was a retrospective study of isolated iliac artery aneurysm patients admitted in Institute of Vascular Surgery, Madras Medical College , Chennai from May 2012 to May 2026 during a time period of 14 years. Case sheets of patients admitted during that time period were retrieved and reviewed. Patients with true aneurysms and pseudoaneurysms involving CIA, IIA or EIA who were managed either by surgery or endovascular means were included in this study. Patients who had concomitant abdominal aortic or peripheral artery aneurysms and those who were managed conservatively were excluded from this study.

A total of 23 patients of isolated iliac artery aneurysm patients had undergone surgical or endovascular treatment for aneursym during that time period. All cases were included in the study. As it was a retrospective study, the details of the patients were obtained from the records available in the Institute of Vascular Surgery, Madras Medical College.

After obtaining approval from Institutional Ethics Committee, Madras Medical College, Chennai on 14.05.2026 with Approval Number: IEC – MMC/Approval/65052026 and from the Head of the Department, Institute of Vascular Surgery, Madras Medical College details such as age, gender, etiology, risk factors, clinical features, location, size of aneurysm, management and complications after treatment were collected from the records.

Informed consent were obtained from patients for utilizing those data. Data was analysed using Statistical Package for Social Sciences (SPSS) Version 26.0 after checking for any duplicate and missing data. Categorical data was expressed in frequency and percentage. Continuous data was expressed in Mean and Standard Deviation.

RESULTS

Among 23 study participants, majority of 86.9% (20) were males and 13.1% (3) were females. 69.6% of study participants were in the age group of 51-70 years. The mean age of study population was 59.1+12.4 years. The youngest case was a 3-year-old male child with bilateral common iliac artery aneurysm (Figure 1) whereas the oldest case was 84-year-old male with common iliac artery aneursym (Table 1).

Figure 1 shows Computed Tomography angiogram of a 3-year-old pediatric patient presenting with large, isolated bilateral common iliac artery aneurysms. The three-dimensional maximum intensity projection reconstruction visualizes two prominent, symmetrical aneurysmal sacs arising at the bifurcation of the abdominal aorta. Linear annotation calipers track the multi-planar maximum diameters of the abnormalities: the right common iliac artery aneurysm measures 42.0 mm by 32.6 mm, while the left common iliac artery aneurysm measures 39.3 mm by 22.8 mm. Both renal arteries and the distal femoral vasculature appear normal in caliber with standard contrast opacification.

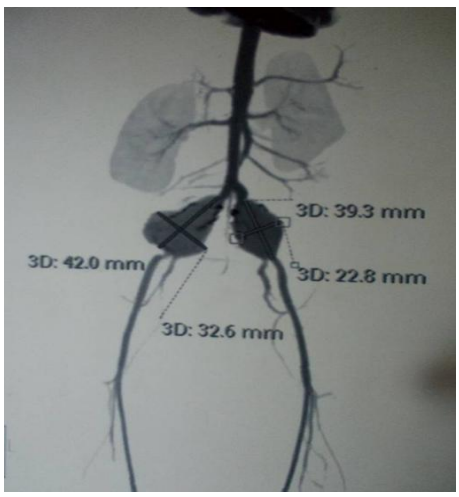

Figure 1: CT angiogram of 3-year-old child with bilateral common iliac artery aneurysm.

Majority of 82.7% (19) had degenerative etiology. Smoking was the most common risk factor in 69.6% (16) patients followed by hypertension in 52.1% (12) patients (Table 2). The 73.9% (17) patients presented with abdominal pain followed by pulsatile mass in 26.1% patients (6). Among 23 cases, 5 cases have ruptured. Average size of ruptured aneursym was 5.5 cm at the time of presentation. Average size of non- ruptured aneursym was 4.6 cm at the time of presentation. Common iliac artery was the most common involved artery in 78.4% (18) of cases of isolated iliac artery aneursym (Table 3).

Majority of 87.1% (n=20) participants were managed by open surgery. Among those managed by open surgery, 43.6% were managed by aorto-uni-ilaic bypass surgery. Overall, 5 patients developed complications after open surgery. There are 2 post-operative deaths after open surgery (1 patient operated by aorto-uni-iliac bypass and 1 patient operated by aorto-bi-iliac bypass). 1 patient operated by aorto-uni-iliac bypass developed post-operative hematoma. Two patients developed surgical site infection after open surgery (1 patient operated by aorto-uni-iliac bypass and 1 patient operated by iliac-to-iliac bypass) (Table 4). The 3-year-old child with bilateral common iliac artery aneursym underwent aneursym excision and reconstruction with reversed saphenous vein interposition grafts (Figure 2).

Figure 2 shows intraoperative view of the pelvic reconstruction in same 3-year-old child following bilateral common iliac artery aneurysm repair. The surgical field demonstrates successful excision of the aneurysmal segments and arterial restoration using bilateral autogenous reversed saphenous vein (RSV) interposition grafts, marked by open black arrows. Fine monofilament polypropylene sutures secure the proximal and distal end-to-end vascular anastomoses. The fully decompressed and open native right common iliac artery (CIA) aneurysm sac is visible laterally, noted by a solid black arrow. Surrounding structures, including the mobilized pelvic viscera, are retracted to expose the distal aortic bifurcation.

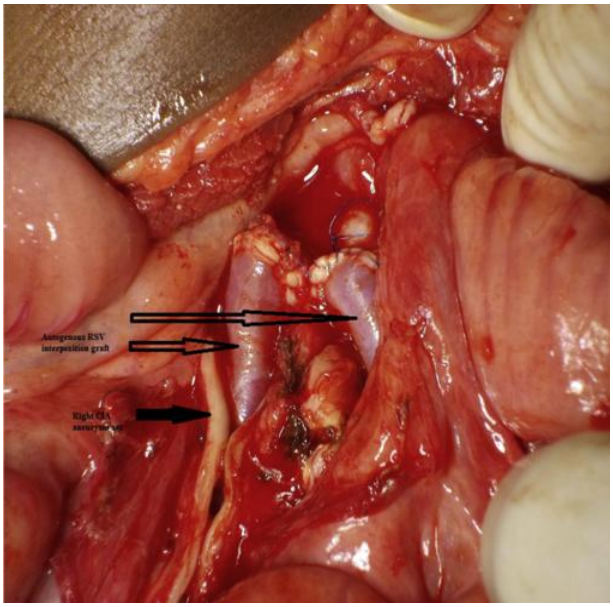

Figure 2: Intra- operative picture after reconstruction of the same 3-year-old child.

Table 1: Demographic profile of study population (n=23).

Demographic profile	Frequency	Percentage
Gender		
Male	20	86.9
Female	3	13.1
Age groups (in years)		
<20	2	8.7
21-30	1	4.3
41-50	2	8.7
51-60	8	34.8
61-70	8	34.8
71-80	1	4.3
>80	1	4.3

Table 2: Etiology and risk factors in study population (n=23).

Variables	Frequency	Percentage
Etiology		
Degenerative	19	82.7
Mycotic	2	8.7
Trauma	1	4.3
Anastomotic pseudoaneursym	1	4.3

Continued.

Variables	Frequency	Percentage
Risk factors		
Smoking	16	69.6
Hypertension	12	52.1
Diabetes mellitus	8	34.8
Chronic kidney disease	1	4.3
Rheumatic heart disease	1	4.3

Table 3: Clinical features and artery involvement in study population (n=23).

Variables	Frequency	Percentage
Clinical features		
Abdominal pain	17	73.9
Pulsatile mass	6	26.1
Lower limb Claudication pain	3	12.9
Fever	1	4.3
Deep vein thrombosis	1	4.3
Artery involved		
Common iliac artery	18	78.4
Internal iliac artery	2	8.7
External iliac artery	1	4.3
Common iliac artery and internal iliac artery	1	4.3
Common iliac artery, external iliac artery and internal iliac artery	1	4.3

Table 4: Management of isolated iliac artery aneursym in study population (n=23).

Open surgery (N=20)	Endovascular treatment (n=3)
Aorto-uni-iliac bypass - 10 (43.6%)	Covered stenting of common iliac artery - 1 (4.3%)
Aorto-bi-iliac bypass - 4 (17.4%)	Covered stenting of external iliac artery - 1 (4.3%)
Iliac to iliac bypass - 3 (13.1%)	Glue and coil embolisation of internal iliac artery - 1 (4.3%)
Aneursym ligation - 2 (8.7%)	
Aorto-bi-femoral bypass – 1 (4.3%)	

DISCUSSION

In a systematic review done by Nektarios Charisis et al involving 21 studies with 879 patients and 981 isolated cases of CIAA operated by endovascular approach, 90.8% were males.[4] The mean age of the patients was 71.7 years. In a study done by Steenberge SP et al among 244 isolated CIAAs found in 167 patients over a time period of 13 years from January 2008 to February 2020, 94% were males and average age of study participants was 68.1±8.8 years.[5] In a study done by Joana Ferreira et al among 11 patients with 16 aneurysms, 100% were men with a mean age of 69.2+6.0 years were treated.[6] In a review paper done by Dix FP et al, reporting 94 cases of IIIAA, the median age was 71.9 years and 95% were male.[7] In a study done by Richardson JW et al from 1972 to 1985, 55 patients with 72 aneurysms of the iliac vessels were evaluated retrospectively during a 12-year period (1972 to 1985).[8] There was marked male predominance (5:1) and advanced age (mean 74.6 years) in this study. In a study done by Minato N et al, 16 patients with 44 aneurysms of the iliac artery during a 12-year period (1981 to 1992), the mean age was 71.2 years with male/female ratio of 7:1.[9] In a study done by Weimann S et al, data were collected from 22 men with iliac artery aneurysms who were treated surgically over a period of 22 years, the mean age was 64.0 years.[10] A retrospective study done by Santilli SM et al, was conducted among 189 patients (187 men and two women) with 323 IAAs reported between June 1990 and March 1999.[11] Their mean age was 72.3+0.5 years. These studies support findings of male predominance (86.9%) and more involvement in age group greater than 60 years of age with mean age of 59.1+12.4 years in this study.

Mean aneurysm size in this study (5.05 cm) was lower than findings of Richardson JW et al (5.5 cm) and Dix FP et al (7.7 cm), and higher than findings of Nektarios Charisis et al (4.1 cm), Steenberge SP et al (2.3 cm), Santilli SM et al (2.34 cm) and Joana Ferreira et al (3.7 cm). In this study, mean diameter of ruptured aneurysm (5.5 cm) was lower than Nektarios Charisis et al (5.8 cm) and Joana Ferreira et al (5.7 cm on emergency repair possibly rupture).

In a study done by Joana Ferreira et al, while analysing the vascular risk factors, that hypertension was the most prevalent risk factor and the diagnosis of aneurysm was done 10 years sooner in the smoker patients compared to non-smokers thus making smoking also a risk factor.[6] In a study done by Richardson JW et al, atherosclerotic vascular disease, one of chronic degenerative disease was found in all 100% aneurysms.[8] These findings support this study findings in which 82.7% of aneursyms had degenerative etiology. Also, smoking (69.6%) and hypertension (52.1%) are common findings in this study similar to findings of Joana Ferreira et al.

In a review paper done by Dix FP et al, major symptoms include abdominal pain (31.7%) followed by urological symptoms (28.3%), neurological symptoms (18.3%) and groin pain (11.7%). In a study done by Richardson JW et al, 45% patients were either asymptomatic or had such nonspecific complaints in 11% population that diagnosis was often delayed or erroneous. A mass detected during abdominal, rectal, or vaginal examination was found in 70% of population. In a study done by Minato N et al, 37.5% patients presented urologic complications of ureteral stenosis, with hydronephrosis caused by perianeurysmal fibrosis in 31.25% patients.[9] In a study done by Weimann S et al 10 , 68.2% patients were symptomatic with rupture in 22.7%. In a retrospective study done by Santilli SM et al, symptoms were noted in six of 189 patients (3.1%).[11] These findings are in contrast to our study findings in which, 73.9% patients presented with abdominal pain followed by pulsatile mass in 26.1% patients.

In a study done by Joana Ferreira et al, majority of aneurysms were at the common iliac artery and 27.3% of them were multiple. In a study done by Richardson JW et al, isolated aneurysms were found primarily to involve the internal iliac artery in 12 of 18 patients of isolated aneursyms (66.7%). In a study done by Weimann S et al, 86.6% aneurysms were found in the common iliac artery. These findings support this study findings of involvement of common iliac artery in majority of cases (78.4%) similar to findings of Joana Ferreira et al and Weimann S et al (86.6%). However, this study findings is in contrast to findings of Richardson JW et al, in which internal iliac artery is involved in 66.7% of iliac artery aneursysm.

In this study, 86.9% patients were operated by open surgery higher than study by Steenberge SP et al in which 26.3% of aneursym repairs were performed via an open surgery, study by Joana Ferreira et al in which 63.6% repairs done by elective open surgeries, study by Minato N et al having 70.9% open surgery and 26.71% open surgeries in a study done by Rabih Antoine Chaer et al.[12]

Postoperative complications were present in 5 patients (21.7%) with post-operative mortality of 8.7% in this study. All postoperative complications developed in patients operated by open surgery. This postoperative mortality was higher than perioperative mortality rate of 0.7% in a study done by Nektarios Charisis et al and lower than Richardson JW et al study with an overall mortality rate of 11% and 33% mortality in emergency procedure, Minato N et al study with mortality rate of 50%, Weimann S et al study with a mortality rate of 9.1% and Rabih Antoine Chaer et al study with a mortality rate of 15.8% in open surgery group and 1.9% mortality in endovascular group.

The strength of this study was that it reviewed rare cases of isolated iliac artery aneursyms over a long period of 14 years. The limitations of this study were that it was done as a single centre study and the patients were not followed for a long duration post-surgery to look for any complications or mortality. So, we recommend to follow cases for a minimum period of 5 years post-surgery to look for any new complications.

CONCLUSION

Isolated iliac artery aneurysms are uncommon. The most common risk factors are cigarette smoking and hypertension which can be modified through appropriate health education and early preventive measures. Results of both open surgery and endovascular management are good though complications are seen in few cases after open surgery, thus making endovascular procedure as a safe procedure compared to open surgery

Funding: No funding sources
Conflict of interest: None declared
Ethical approval: The study was approved by the Institutional Ethics Committee

REFERENCES

1. Bashir O, Niknejad M. Iliac artery aneurysm. Radiopaedia.org; 2026. Available from: https://doi.org/10.53347/rID-17187
2. Elsevier. Iliac artery aneurysm. ScienceDirect Topics. Amsterdam: Elsevier. Available from: https://www.sciencedirect.com/topics/medicine-and-dentistry/iliac-artery-aneurysm. Accessed on 21 July 2026.
3. Lowenberg RI. Isolated common iliac artery aneurysm. Annals of Vascular Surgery. 2005 Sep;19(5):737-739. doi: 10.1007/s10016-005-0059-1
4. Newton DH, Levy MM, Rajendran B, Pfeifer JR, Amendola MF. Contemporary outcomes of isolated iliac artery aneurysm repair. J Vasc Surg. 2015;61(6 Suppl):61S.
5. Steenberge SP, Caputo FJ, Rowse JW, Lyden SP, Quatromoni JG, Kirksey L, et al. Natural history and growth rates of isolated common iliac artery aneurysms. J Vasc Surg. 2022;76(2):461-5.
6. Ferreira J, Canedo A, Brandão D, Maia M, Braga S, Chaparro M, et al. Isolated iliac artery aneurysms:

six-year experience. Interact Cardiovasc Thorac Surg. 2010;10(2):245-8.
7. Dix FP, Titi M, Al-Khaffaf H. The isolated internal iliac artery aneurysm—a review. Eur J Vasc Endovasc Surg. 2005;30(2):119-29.
8. Richardson JW, Greenfield LJ. Natural history and management of iliac aneurysms. J Vasc Surg. 1988;8(2):165-71.
9. Minato N, Itoh T, Natsuaki M, Nakayama Y, Yamamoto H. Isolated iliac artery aneurysm and its management. Cardiovasc Surg. 1994;2(4):489-94.
10. Sarcina A, Carati G, Bellosta R, Ferrero E, Ganimede MP, Malacrida G, et al. Solitary iliac artery aneurysms: a review of 71 cases. Ann Vasc Surg. 1993;7(2):165-71.
11. Santilli SM, Wernsing SE, Lee ES. Expansion rates and outcomes for iliac artery aneurysms. J Vasc Surg. 2000;31(1 Pt 1):114-21.
12. Chaer RA, Barbato JE, Lin SC, Zenati M, Kent KC, McKinsey JF. Isolated iliac artery aneurysms: a contemporary comparison of endovascular and open repair. J Vasc Surg. 2008;47(4):708-13.

Cite this article as: Ambalam S, Narayanan S, Jayachander K, Paramasivam I, Remin V, Hariprakash M. Successful management of isolated iliac artery aneurysms. Int Surg J 2026;13:2504-9.