International Surgery Journal
Munoz-Leija MA et al. Int Surg J. 2026 Dec;13(12):2615-2619
https://www.ijsurgery.com
pISSN 2349-3305 | eISSN 2349-2902

DOI: https://dx.doi.org/10.18203/2349-2902.isj20264373

Case Report

Laparoscopic conversion of endoscopic sleeve gastroplasty to Roux-en-Y gastric bypass: intraoperative findings and the role of intraoperative endoscopy — a case report

Milton A. Munoz-Leija*, Karina Sarmiento Sarmiento, Susana Delgadillo Gutierrez, Armando M. Joya-Munguia

Bariatric Surgery Division, Hospital Joya, Puerto Vallarta, Jalisco, Mexico

Received: 08 October 2026
Accepted: 05 November 2026

***Correspondence:**
Dr. Milton A. Munoz-Leija,
E-mail: milton.munoz@udem.edu

Copyright: © the author(s), publisher and licensee Medip Academy. This is an open-access article distributed under the terms of the Creative Commons Attribution Non-Commercial License, which permits unrestricted non-commercial use, distribution, and reproduction in any medium, provided the original work is properly cited.

ABSTRACT

Endoscopic sleeve gastroplasty (ESG) is increasingly used as a minimally invasive treatment for obesity, resulting in a growing number of patients who may require revisional metabolic and bariatric surgery. However, the anatomical and technical challenges encountered during surgical conversion after ESG remain incompletely described. We report a 50-year-old man with weight recurrence, gastroesophageal reflux disease, and postprandial abdominal pain two years after ESG. Preoperative endoscopy demonstrated persistent sutures at different gastric levels. During laparoscopic conversion to Roux-en-Y gastric bypass (RYGB), dense adhesions, fibrosis, altered tissue planes, and retained ESG sutures interfering with gastric pouch construction were encountered. Intraoperative endoscopy provided simultaneous intraluminal assessment during pouch creation. Because retained sutures interfered with gastric division, a gastrotomy was performed for their identification and removal. After construction of a 4 cm pouch, endoscopy confirmed adequate configuration, absence of obstruction, tissue injury, and residual sutures. Following gastrojejunostomy, endoscopic assessment confirmed anastomotic patency, absence of bleeding, and a negative pneumatic leak test. The postoperative course was uneventful. This case highlights the anatomical and technical challenges of revisional surgery after ESG and illustrates the complementary role of intraoperative endoscopy during conversion to RYGB.

Keywords: Endoscopic sleeve gastroplasty, Roux-en-Y gastric bypass, Revisional bariatric surgery, Intraoperative endoscopy, Metabolic and bariatric surgery

INTRODUCTION

Endoscopic sleeve gastroplasty (ESG) has emerged as a widely adopted endoscopic bariatric therapy for the treatment of obesity, offering a favorable safety profile and clinically meaningful weight loss.

Available evidence has demonstrated sustained total body weight loss, improvement in obesity-related comorbidities, and low rates of serious adverse events, supporting ESG as an effective minimally invasive option for appropriately selected patients.[1-3] As the use of ESG continues to expand, the need for subsequent metabolic and bariatric surgery (MBS) is also increasingly recognized.

Indications for surgical revision include inadequate weight loss, weight recurrence, gastroesophageal reflux disease (GERD), persistent obesity-related comorbidities, and, less commonly, procedure-related adverse events.[3,4]

Conversion to laparoscopic sleeve gastrectomy or Roux-en-Y gastric bypass (RYGB) has been reported as technically feasible; however, the available evidence remains limited and consists predominantly of case reports, small case series, and retrospective studies.[4-7]

Existing reports have focused primarily on the feasibility and postoperative outcomes of surgical conversion, whereas the intraoperative anatomy and technical challenges encountered after ESG have been less consistently characterized.[3-7]

Persistent transmural sutures, gastric fibrosis, adhesions, and remodeling of the gastric wall may alter conventional surgical planes and potentially increase the technical complexity of subsequent revisional procedures. Detailed characterization of these findings may therefore be relevant for operative planning and safe surgical dissection.

We report a patient who underwent laparoscopic conversion from ESG to RYGB for weight recurrence and symptomatic GERD. Particular attention is given to the intraoperative anatomical findings, persistent ESG-related suture material, altered surgical planes, and the complementary use of intraoperative upper endoscopy during revisional surgery. We also discuss these findings in the context of the currently available literature on surgical conversion after ESG.

CASE REPORT

A 50-year-old man with obesity and a height of 1.74 m underwent ESG in May 2024. At the time of the procedure, his weight was 124 kg, corresponding to a body mass index (BMI) of 41.0 kg/m². Following ESG, he achieved a nadir weight of 98 kg (BMI 32.4 kg/m²). Over the subsequent two years, he experienced progressive weight recurrence, reaching 118 kg (BMI 39.0 kg/m²) at the time of evaluation for revisional metabolic and bariatric surgery.

In addition to weight recurrence, the patient developed symptomatic GERD and postprandial abdominal pain that persisted for approximately four months. Preoperative upper gastrointestinal endoscopy demonstrated esophagitis and gastritis, as well as persistent intraluminal suture material from the previous ESG at different gastric levels (Figure 1). No hiatal hernia was identified.

Given the combination of weight recurrence and persistent upper gastrointestinal symptoms, laparoscopic conversion to RYGB was indicated. Initial laparoscopic exploration demonstrated adhesions involving the stomach, including dense adhesions between the greater curvature and the anterior abdominal wall, with distortion of the expected tissue planes (Figure 2). Careful adhesiolysis and gastric dissection were performed to restore the anatomy and permit safe exposure of the proximal stomach.

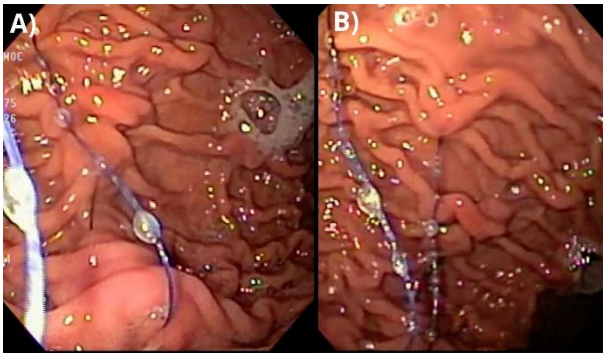

Figure 1: Preoperative endoscopic findings after endoscopic sleeve gastroplasty; (A) Proximal gastric view showing persistent transmural sutures from the previous ESG; (B) Distal gastric body showing additional retained sutures and associated mucosal remodeling.

The endoscopic examination demonstrated persistent suture material at different levels of the stomach before revisional surgery. ESG: endoscopic sleeve gastroplasty.

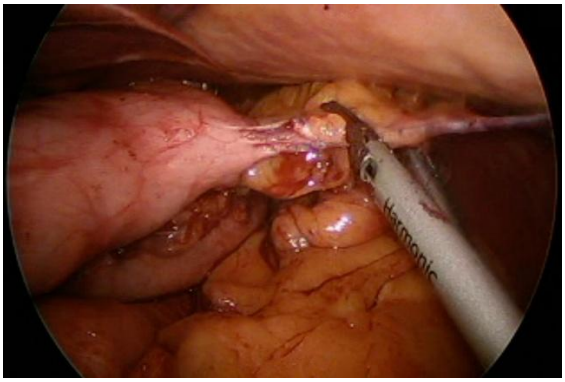

Figure 2: Intraoperative adhesions encountered during laparoscopic conversion to Roux-en-Y gastric bypass.

Laparoscopic view demonstrating adhesions involving the stomach and altered tissue planes encountered during gastric dissection.

During preparation of the gastric pouch, persistent transmural sutures from the previous ESG were encountered within the intended area of gastric division (Figure 3). Intraoperative upper gastrointestinal endoscopy was performed to correlate the intraluminal anatomy with the laparoscopic findings. Because the retained sutures interfered with safe pouch construction, the stomach was opened under endoscopic guidance to identify and remove the residual suture material.

The retained ESG sutures were carefully dissected and divided, allowing removal of the foreign material and management of the surrounding fibrotic tissue (Figure 4). After removal, gastric pouch construction was completed. Intraoperative endoscopy was then repeated to evaluate the newly created 4 cm pouch, confirming appropriate configuration, absence of obstruction or residual ESG sutures, and no evidence of tissue injury.

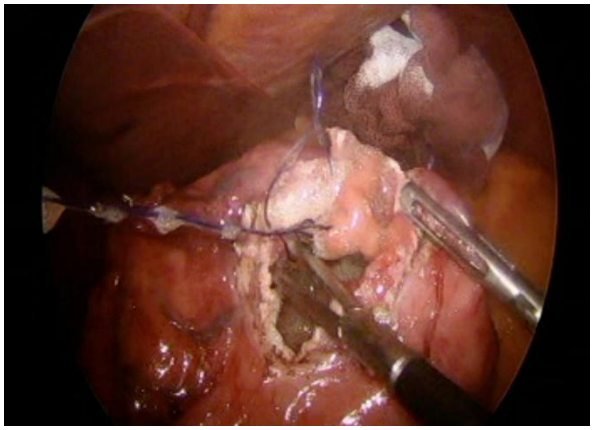

Figure 3: Intraoperative identification of persistent suture material from the previous endoscopic sleeve gastroplasty.
Laparoscopic exposure of residual transmural sutures during gastric dissection before pouch creation.

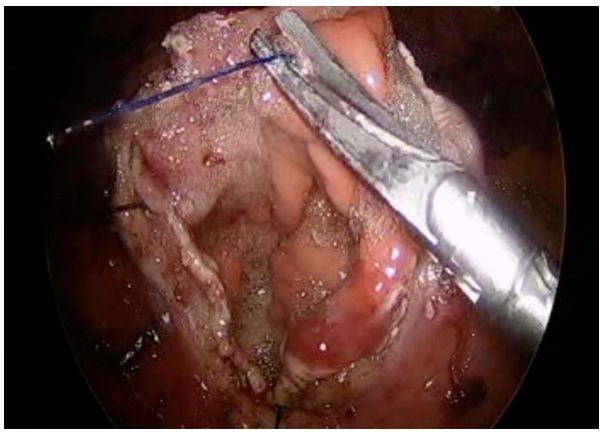

Figure 4: Surgical management of persistent endoscopic sleeve gastroplasty sutures.
Laparoscopic dissection and division of retained suture material to facilitate gastric mobilization and safe pouch creation.

An antecolic RYGB was subsequently completed with a 120 cm biliopancreatic limb and a 100 cm alimentary limb. Following creation of the gastrojejunostomy, a final intraoperative endoscopy was performed. Pneumatic leak testing under endoscopic insufflation showed no evidence of an anastomotic leak. The gastrojejunostomy was patent, with no intraluminal bleeding.

The total operative time was 180 minutes. The postoperative course was uneventful, and the patient was discharged on postoperative day 2. At one-month follow-up, he reported complete resolution of postprandial abdominal pain and significant improvement in GERD symptoms.

DISCUSSION

Although ESG does not involve gastric resection, full-thickness suturing and subsequent tissue remodeling may alter gastric anatomy and influence the technical approach to later surgical conversion. Published experience with revisional surgery after ESG remains limited, particularly regarding the intraoperative findings and technical modifications required during these procedures.[4-7]

The most comprehensive evaluation of the technical aspects of revisional surgery after ESG was recently reported by Nedelcu et al.[4] In their multicenter retrospective series of 58 patients, 37 underwent conversion to sleeve gastrectomy and 21 to RYGB. Preoperative endoscopy demonstrated heterogeneous anatomy, ranging from complete loss of the original plication to residual sutures and cinches or persistence of the ESG configuration. Additional intraoperative techniques were required in a substantial proportion of patients, including fluoroscopic guidance, intraoperative endoscopy, and surgical opening of the stomach.[4] These findings suggest that revisional surgery after ESG cannot be approached as a uniform procedure and may require individualized strategies according to the residual anatomy encountered.

Our case illustrates a technically challenging presentation within this spectrum. Dense adhesions between the greater curvature and the anterior abdominal wall, fibrosis, persistent ESG-related suture material, and distortion of the expected gastric tissue planes were encountered during laparoscopic exploration. Previous reports have demonstrated that conversion from ESG to either SG or RYGB is feasible; however, the degree of anatomical alteration and the technical consequences of residual sutures have been inconsistently described.[5-7] In the present case, the retained sutures were not merely an incidental finding but directly interfered with the planned gastric division during pouch construction. A gastrotomy was therefore required to identify and remove the retained suture material before the gastric transection could be safely completed. Notably, surgical opening of the stomach was also required in selected patients, supporting the need to anticipate modification of conventional surgical techniques when residual ESG material compromises the intended staple line.[4]

Preoperative endoscopy may provide valuable information regarding the persistence of the ESG configuration and residual intraluminal sutures. In our patient, preoperative endoscopy identified persistent suture material, whereas the extent of gastric fibrosis, adhesions to the anterior abdominal wall, and distortion of the surgical planes became apparent only during laparoscopic exploration. Thus, preoperative endoscopic and intraoperative laparoscopic findings should be considered complementary when planning revisional surgery after ESG.

The potential value of intraoperative endoscopy during RYGB extends beyond leak testing. Previous studies have described its use for immediate assessment of anastomotic integrity, luminal patency, bleeding and

other technical defects.[8-11] Endoscopic evaluation may be particularly useful during revisional bariatric surgery, in which previous interventions can distort conventional anatomical landmarks and surgical planes.[10] Our case adds a practical illustration of this approach by demonstrating three complementary applications during the same operation: anatomical guidance during pouch construction, verification of the completed pouch, and quality control of the gastrojejunostomy.

This report has several limitations. It describes a single patient and the anatomical findings encountered after ESG are also likely influenced by factors such as the original suturing pattern, number and location of sutures, time elapsed since the procedure, and individual tissue response. Larger studies using standardized reporting of intraoperative findings are needed to identify predictors of technically complex surgical conversion and to clarify the role of intraoperative endoscopy in this setting.

Despite these limitations, this case demonstrates that conversion from ESG to RYGB may involve substantially altered anatomy despite the absence of previous gastric resection. Persistent suture material, fibrosis, and extra gastric adhesions can interfere with conventional surgical planes and may require modification of the planned operative technique. In this setting, sequential intraoperative endoscopy provided complementary real-time intraluminal information during critical stages of the conversion and enabled immediate assessment of the final reconstruction.

As the use of ESG continues to expand, revisional procedures are likely to become increasingly relevant in bariatric practice. Bariatric surgeons and trainees should be familiar with potential post-ESG anatomical challenges, including persistent sutures, fibrosis, adhesions, and altered surgical planes. Anticipating these findings and becoming familiar with complementary tools such as intraoperative endoscopy may facilitate anatomical assessment and intraoperative decision-making during complex revisional surgery.

CONCLUSION

Conversion from endoscopic sleeve gastroplasty to Roux-en-Y gastric bypass may present technical challenges related to persistent suture material, fibrosis, adhesions, and distortion of conventional surgical planes. In this case, retained ESG sutures interfered with gastric pouch construction and required gastrotomy and suture removal before gastric division could be completed.

Sequential intraoperative endoscopy provided complementary real-time intraluminal assessment during critical stages of the conversion, assisting with suture localization, pouch verification, and evaluation of the gastrojejunostomy. As revisional procedures after ESG become more frequent, bariatric surgeons should anticipate these anatomical challenges and be familiar with complementary techniques that may facilitate intraoperative assessment and decision-making.

Funding: No funding sources
Conflict of interest: None declared
Ethical approval: Not required

REFERENCES

1. Barrichello S, Hourneaux de Moura DT, Hourneaux de Moura EG, Jirapinyo P, Hoff AC, Fittipaldi-Fernandez RJ, et al. Endoscopic sleeve gastroplasty in the management of overweight and obesity: an international multicenter study. Gastrointest Endosc. 2019;90(5):770-80.
2. Singh S, Hourneaux de Moura DT, Khan A, Bilal M, Ryan MB, Thompson CC. Safety and efficacy of endoscopic sleeve gastroplasty worldwide for treatment of obesity: a systematic review and meta-analysis. Surg Obes Relat Dis. 2020;16(2):340-51.
3. Espinet-Coll E, Nebreda-Durán J, Bautista-Altamirano C, Perretta S, Galvao-Neto M. Endoscopic sleeve gastroplasty (ESG): a semi-systematic review of current evidence, metabolic impact, special populations, and comparative strategies. Rev Esp Enferm Dig. 2025.
4. Nedelcu M, Marx L, Mercoli HA, Danan M, Vilallonga R, Nedelcu A. Technical aspects of revisional surgery following endoscopic sleeve gastroplasty. Surg Obes Relat Dis. 2026;22(4):440-5.
5. Ferrer-Márquez M, Ferrer-Ayza M, Rubio-Gil F, Torrente-Sánchez MJ, Martínez Amo-Gámez A. Revisión quirúrgica bariátrica tras gastroplastia vertical endoscópica [Revision bariatric surgery after endoscopic sleeve gastroplasty]. Cir Cir. 2017;85(5):428-31.
6. Cheng Q, Tree K, Edye M, Devadas M. Reversal of endoscopic sleeve gastroplasty and conversion to sleeve gastrectomy: two case reports. Int J Surg Case Rep. 2020;68:180-4.
7. Cimpean S, Marechal MT, Cadiere B, Cadiere GB. Endoscopic sleeve gastrectomy conversion to Roux-en-Y gastric bypass. Eur J Med Health Sci. 2020;2(3).
8. Al Hadad M, Dehni N, Elamin D, Ibrahim M, Ghabra S, Nimeri A. Intraoperative endoscopy decreases postoperative complications in laparoscopic Roux-en-Y gastric bypass. Obes Surg. 2015;25(9):1711-5.
9. Valenzuela-Salazar C, Rojano-Rodríguez ME, Romero-Loera S, Trejo-Ávila ME, Bañuelos-Mancilla J, Delano-Alonso R, et al. Intraoperative endoscopy prevents technical defect related leaks in laparoscopic Roux-en-Y gastric bypass: a randomized control trial. Int J Surg. 2018;50:17-21.
10. Morales MP, Wheeler AA, Ramaswamy A, Scott JS, de la Torre RA. Laparoscopic revisional surgery after Roux-en-Y gastric bypass and sleeve

gastrectomy. Surg Obes Relat Dis. 2010;6(5):485-90.
11. Alasfar F, Chand B. Intraoperative endoscopy for laparoscopic Roux-en-Y gastric bypass: leak test and beyond. Surg Laparosc Endosc Percutan Tech. 2010;20(6):424-7.

Cite this article as: Munoz-Leija MA, Sarmiento KS, Gutierrez SD, Joya-Munguia AM. Laparoscopic conversion of endoscopic sleeve gastroplasty to Roux-en-Y gastric bypass: intraoperative findings and the role of intraoperative endoscopy — a case report. Int Surg J 2026;13:2615-9.