International Surgery Journal
Mujawar ATN et al. Int Surg J. 2026 Dec;13(12):2635-2641
https://www.ijsurgery.com
pISSN 2349-3305 | eISSN 2349-2902

DOI: https://dx.doi.org/10.18203/2349-2902.isj20264378

Case Report

Acute necrotizing pancreatitis with retroperitoneal extension into the scrotum through a dilated inguinal ring: a case report

Abu Talha N. Mujawar[1]*, Siddhesh S. Chavan[1], Kedar Gorad[1], Sunil Magdum[1], Prasad D. Hake[3]

[1]Department of General Surgery, Prakash Institute of Medical Sciences and Research Centre, Islampur-Sangli Road, Islampur, Tal-Walwa, Sangli, Maharashtra 415409, India
[2]Department of Uro-Surgery, Prakash Institute of Medical Sciences and Research Centre, Islampur-Sangli Road, Islampur, Tal-Walwa, Sangli, Maharashtra, India
[3]Prakash Institute of Medical Sciences and Research Centre, Islampur-Sangli Road, Islampur, Tal-Walwa, Sangli, Maharashtra, India

Received: 08 October 2026
Accepted: 05 November 2026

***Correspondence:**
Dr. Abu Talha N. Mujawar,
E-mail: abutalha4786@gmail.com

Copyright: © the author(s), publisher and licensee Medip Academy. This is an open-access article distributed under the terms of the Creative Commons Attribution Non-Commercial License, which permits unrestricted non-commercial use, distribution, and reproduction in any medium, provided the original work is properly cited.

ABSTRACT

Acute pancreatitis can rarely extend into the inguinoscrotal region through retroperitoneal anatomical planes. We report a 35-year-old man with probable alcohol-associated acute necrotizing pancreatitis who presented with abdominal pain, fullness, and left inguinoscrotal swelling. Contrast-enhanced computed tomography demonstrated extensive peripancreatic and left retroperitoneal inflammatory collections extending along the paracolic gutter and iliopsoas region into the pelvis and through a dilated left inguinal ring toward the left scrotal sac. The modified CT severity index was 8/10. Initial renal dysfunction, with serum creatinine of 2.0 mg/dl, resolved within 48 hours, and persistent organ failure was not demonstrated; the clinical course was therefore consistent with moderately severe acute pancreatitis according to the revised Atlanta classification. The patient improved with conservative treatment without surgical, percutaneous, or urological intervention, and the inguinoscrotal swelling showed slight reduction by hospital day 10. Scrotal ultrasonography and Doppler examination were not performed, so the precise nature of the intrascrotal component could not be characterized. This case emphasizes that pancreatic and retroperitoneal inflammatory collections can track through the pelvis and inguinal canal and that cross-sectional imaging is valuable when acute pancreatitis is accompanied by new inguinoscrotal swelling.

Keywords: Acute necrotizing pancreatitis, Alcohol-associated pancreatitis, Computed tomography, Inguinal canal, Pancreatic necrosis, Retroperitoneal collection

INTRODUCTION

Acute pancreatitis is an inflammatory disorder with a broad clinical spectrum ranging from self-limited disease to necrotizing pancreatitis with local and systemic complications. The revised Atlanta classification defines the clinical severity of acute pancreatitis according to the presence and duration of organ failure, while local complications and radiological severity are assessed separately.[1] Pancreatic and peripancreatic inflammatory collections can extend beyond the immediate pancreatic region into the retroperitoneum and other anatomical compartments. In rare circumstances, these collections may track toward the pelvis, inguinal canal, and scrotum. Inguinoscrotal extension has been described in isolated case reports and small case series and may mimic incarcerated inguinal hernia, hydrocele, epididymo-orchitis, scrotal abscess, or other causes of acute scrotal swelling.[2-8] The proposed mechanism involves movement of pancreatic and retroperitoneal inflammatory fluid

along anatomical planes of relatively low resistance. The paracolic gutters, retroperitoneal spaces, iliopsoas region, and pelvic compartments may provide pathways for inferior extension. Fluid may subsequently enter the inguinal canal through a patent, widened, or dilated deep inguinal ring and reach the scrotum.[2,3]

We report a case of acute necrotizing pancreatitis with extensive left-sided retroperitoneal extension and clinically apparent left inguinoscrotal swelling. Contrast-enhanced CT demonstrated continuity of the inflammatory process from the pancreatic region through the retroperitoneum and pelvis to the left inguinal ring and scrotal sac. The patient improved with conservative management without surgical, percutaneous, or urological intervention.

CASE REPORT

A 35-year-old man presented to a tertiary care teaching hospital in Maharashtra, India, with abdominal pain and left inguinoscrotal swelling. He reported abdominal pain for approximately three days, which was gradual in onset and progressively increasing in severity, associated with decreased appetite and abdominal fullness. Left inguinoscrotal swelling had developed approximately two days before presentation and was non-reducible, tender, and associated with increased local warmth.

The patient reported chronic alcohol consumption of approximately 240 mL of whisky and locally distilled alcohol daily for approximately seven years. There was no documented history of previous episodes of pancreatitis, gallstone disease, abdominal trauma, or pancreatic surgery. Additional symptoms included black stools for approximately two days, burning micturition for three days, and an episode of vomiting on the morning of presentation. Bowel and bladder habits were otherwise reported to be maintained. There was no documented history of jaundice before admission.

On admission (hospital day 1), the patient was conscious and oriented with a Glasgow Coma Scale score of 15/15. His temperature was 101°F (38.3°C), pulse rate was 104 beats/minute, blood pressure was 140/84 mmHg, respiratory rate was 21 breaths/minute, and oxygen saturation was 98% on room air. Mild icterus was present. The abdomen was mildly distended with generalized tenderness. Examination of the left inguinoscrotal region revealed mild left hemiscrotal swelling with local tenderness and increased warmth. The swelling was non-reducible. No overlying skin changes or appreciable fluctuation were documented. A cough impulse was not elicited, and the left testis could not be separately palpated clinically because of the swelling. The right hemiscrotum was unremarkable.

Initial laboratory investigations showed serum amylase of 127 U/l, lipase of 334 U/l, blood urea of 96 mg/dl, and serum creatinine of 2.0 mg/dl. The white blood cell count was 7,500/µl with 88% neutrophils, and platelet count was 114×10³/µl. Serum sodium was 135 mEq/l, potassium was 4.9 mEq/l, and calcium was 8.6 mg/dl (Table 1). Urinalysis demonstrated 10-15 pus cells/high-power field and 5-10 red blood cells/high-power field. No urine culture result was available.

The patient was admitted under general surgical care and initially kept nil per oral. A Ryle's tube was inserted for gastric decompression and was maintained until oral liquid feeding was initiated. Intravenous fluid therapy included normal saline, Ringer's lactate, and dextrose-containing fluids. Additional documented treatment included thiamine, pantoprazole, ondansetron, paracetamol, tramadol, and supportive therapy. Ceftriaxone 1 g twice daily was administered for seven days, after which antimicrobial therapy was changed to meropenem and metronidazole. No amikacin administration was documented in the available treatment records. A Foley catheter was inserted for accurate urine output measurement, and blood glucose, fluid balance, and urine output were monitored.

The patient remained nil per oral during the initial phase of hospitalization. Liquid feeding was initiated on hospital day 6 and was subsequently advanced to a soft diet on hospital day 8 as tolerated. Documented fluid input and output were 4,950/1,700 ml on hospital day 3, 3,800/2,300 ml on hospital day 4, 4,000/1,300 ml on hospital day 5, 5,200/1,600 ml on hospital day 6, 5,700/1,600 ml on hospital day 7, and 4,200/3,600 ml on hospital day 8. Bowel movements were documented from hospital day 5 onward.

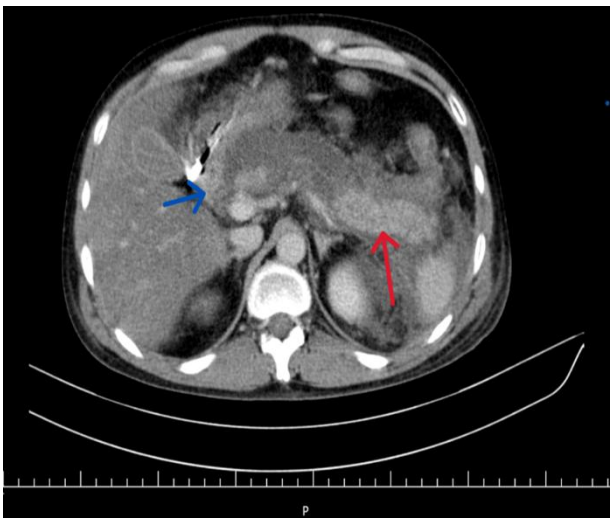

Figure 1: Axial contrast-enhanced computed tomography of the upper abdomen demonstrating a bulky, heterogeneous pancreas with diffuse peripancreatic fat stranding and fluid. The blue arrow indicates the hypoenhancing pancreatic head and proximal body, suspicious for pancreatic necrosis. The red arrow indicates the bulky distal pancreatic body and tail with surrounding inflammatory changes.

Contrast-enhanced CT of the abdomen and pelvis was performed on hospital day 4. It demonstrated a mildly bulky pancreas with diffuse peripancreatic fat stranding and fluid. Areas of hypoenhancement were present in the pancreatic head and proximal body, suspicious for pancreatic necrosis, while the distal body and tail were bulky with heterogeneous enhancement (Figure 1).

Multiple ill-defined non-enhancing inflammatory collections were present in the peripancreatic region, including along the anterolateral aspect of the pancreatic body, splenic hilum, subhepatic region, lesser sac, greater sac, and gastrosplenic ligament. The inflammatory process extended into the left anterior and posterior pararenal spaces and left lateral conal fascia, with inferior extension along the left paracolic gutter and iliopsoas region toward the pelvis (Figures 2 and 3).



Figure 2: Coronal contrast-enhanced computed tomography of the abdomen and pelvis demonstrating extensive left-sided retroperitoneal inflammatory collections extending inferiorly along the left paracolic gutter and iliopsoas region toward the pelvis.

Inferiorly, the inflammatory process extended through a dilated left inguinal ring, measuring approximately 2.1 cm, toward the left inguinal region and left scrotal sac (Figure 6). An inflammatory collection in the left inguinal region measured approximately 2.8 cm (Figure 4). At the level of the scrotum, heterogeneous contents were noted within the left hemiscrotum compared with the right hemiscrotum (Figure 5).

The main pancreatic duct was not dilated. Mild reactive wall thickening involved the stomach, duodenum, proximal jejunum, and adjacent colon, with increased attenuation of the mesenteric fat consistent with a misty mesentery. Mild ascites was present. There was a mild left pleural effusion with passive subsegmental atelectatic change and a minimal right pleural effusion. The liver was enlarged, measuring approximately 18 cm in the midclavicular line, with reduced attenuation consistent with hepatic steatosis. The gallbladder was partially distended without calculi or wall thickening. The common bile duct and cystic duct were not dilated, and there was no intrahepatic biliary dilatation. The portal vein was normal in caliber.



Figure 3: Sagittal contrast-enhanced computed tomography demonstrating peripancreatic and retroperitoneal inflammatory collections tracking inferiorly through the retroperitoneum and pelvis.

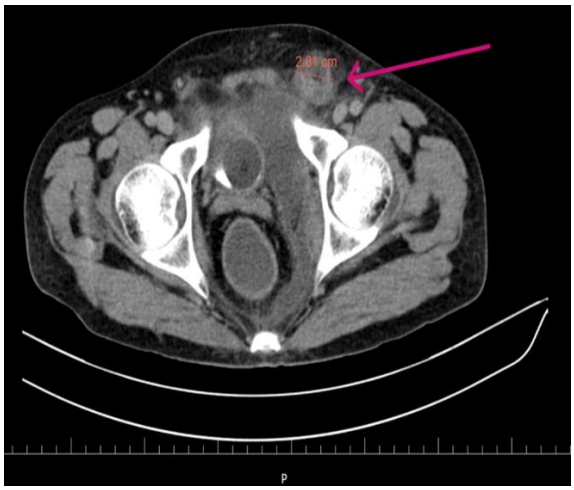

Figure 4: Axial computed tomography of the pelvis demonstrating a dilated left inguinal ring (arrow), through which the inflammatory process extends toward the left inguinoscrotal region.

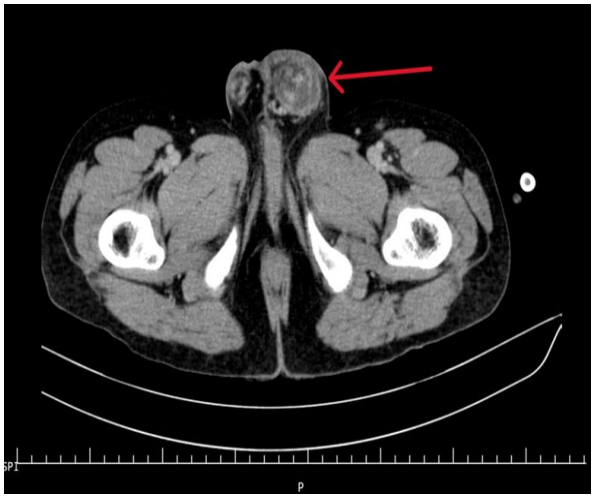

Figure 5: Axial computed tomography at the level of the scrotum demonstrating heterogeneous contents within the left hemiscrotum (arrow) compared with the relatively unremarkable right hemiscrotum.

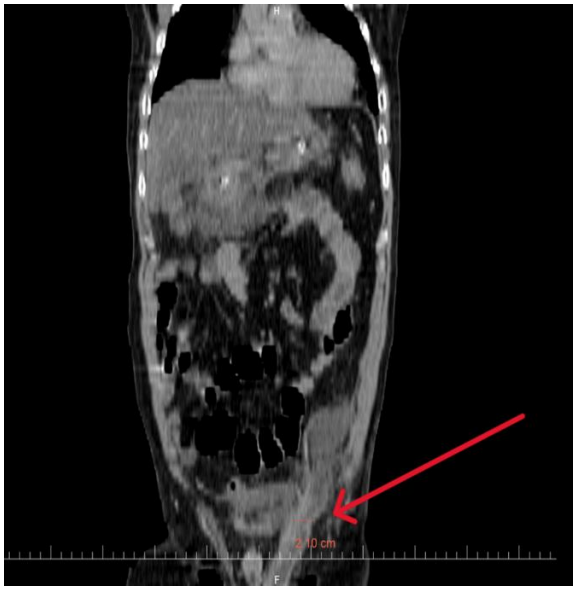

Figure 6: Coronal computed tomography of the abdomen and pelvis demonstrating inferior extension of the left-sided inflammatory collection through the dilated left inguinal ring (arrow), measuring approximately 2.1 cm.

An additional significant finding was an 8×6 mm hyperdense calculus in the proximal right ureter, approximately 5 cm distal to the right pelvi-ureteric junction, producing mild upstream hydroureteronephrosis. Few additional non-obstructive bilateral renal calyceal calculi were present. This urinary tract finding provided a potential structural explanation for the patient's dysuria and microscopic hematuria but was anatomically separate from the left-sided retroperitoneal and inguinoscrotal inflammatory process. A small hyperdense focus was also noted adjacent to the right psoas muscle (Figure 7).

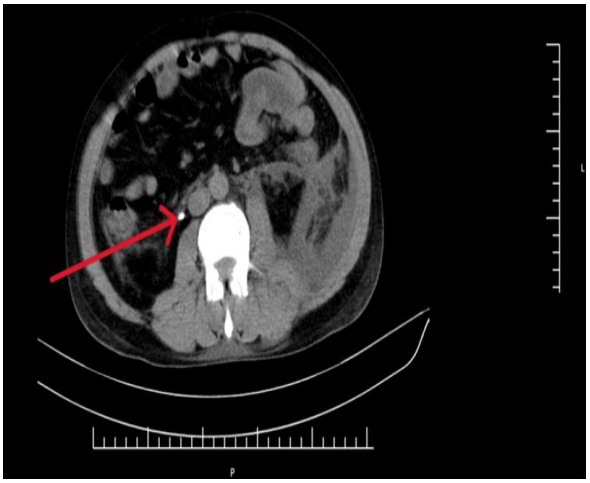

Figure 7: Axial CT image demonstrating an 8 × 6 mm hyperdense calculus (approximately 1000–1100 HU) in the proximal right ureter, approximately 5 cm distal to the right pelvi-ureteric junction, causing mild upstream hydroureteronephrosis (arrow).

The radiological impression was acute necrotizing pancreatitis with extensive multifocal peripancreatic and retroperitoneal non-enhancing inflammatory collections extending through the left paracolic gutter and pelvis and reaching the left scrotal sac through a dilated left inguinal ring. The modified CT severity index was 8/10, indicating severe radiological disease. Scrotal ultrasonography and Doppler examination were not performed. Consequently, the left testis and epididymis, testicular vascularity, presence or absence of hydrocele, and precise nature of the heterogeneous left hemiscrotal contents could not be characterized. The left scrotal finding was therefore considered radiological extension of the inflammatory process toward the scrotal sac rather than a specific scrotal diagnosis. No urological consultation, scrotal drainage, percutaneous drainage, or surgical intervention was performed.

During hospitalization, renal function and pancreatic enzyme levels improved. Blood urea decreased from 96 mg/dL on hospital day 1 to 22 mg/dl by hospital day 2. Serum creatinine decreased from 2.0 mg/dL on hospital day 1 to 1.0 mg/dl on hospital day 2, 0.9 mg/dl on hospital day 3, 0.9 mg/dl on hospital day 7, and 0.8 mg/dL on hospital day 9. Serum amylase decreased from 127 U/l to 55 U/l, while lipase decreased from 334 U/l to 100 U/L. The white blood cell count remained between 4,000 and 7,500/µl during the available measurements. Platelet count initially decreased from 114×10^3/µl to approximately $101\text{-}102\times10^3$/µl and subsequently increased to 208×10^3/µl before discharge (Table 1). Hemoglobin decreased from 14.7 g/dl on hospital day 1 to 10.1 g/dl on hospital day 9. No overt gastrointestinal bleeding requiring intervention was documented. Because no endoscopic evaluation was performed, the cause of the hemoglobin decline could not be definitively established despite the reported history of black stools/melena.

The patient's abdominal symptoms and overall clinical condition improved with conservative management. The left inguinoscrotal swelling showed slight clinical reduction by discharge on hospital day 10. No repeat CT, scrotal ultrasonography, Doppler examination, or post-discharge clinical follow-up was available. At discharge, the patient was prescribed oral faropenem 200 mg three times daily, metronidazole 500 mg three times daily, pantoprazole-domperidone twice daily, thiamine 100 mg twice daily, chlordiazepoxide 10 mg twice daily, a chymotrypsin-based preparation twice daily, and a probiotic preparation twice daily. He was advised to maintain adequate oral fluid intake and avoid alcohol.

Table 1: Laboratory investigations during hospitalization.

Parameter	Day 1	Day 2	Day 3	Day 7	Day 9	Normal range
Hemoglobin (g/dl)	14.7	13.2	12.8	10.4	10.1	13.5-18
White blood cells (/µl)	7500	4,000	5,300	4300	6,500	4000-11000
Platelets (×10³/µl)	114	102	101	208	166	150-450
Urea (mg/dl)	96	22	19	21	29	15-40
Creatinine (mg/dl)	2	1	0.9	0.9	0.8	0.6-1.4
Amylase (IU/l)	127	—	—	—	55	0-96
Lipase (IU/l)	334	—	—	—	100	0-60
Neutrophils (%)	88	70	84	85	—	40-75
Lymphocytes (%)	8	26	12	10	—	20-45
Sodium (mEq/l)	135	—	—	135	—	135-155
Potassium (mEq/l)	4.9	—	—	4.3	—	3.5-5.5
Calcium (mg/dl)	8.6	—	—	8.3	—	8.5-10.5
Random blood glucose (mg/dl)	115	131	122	130	110	70-150

DISCUSSION

Inguinoscrotal extension of pancreatic and retroperitoneal collections is an uncommon complication of acute pancreatitis. The present case is notable for the extensive anatomical pathway demonstrated on contrast-enhanced CT, with inflammatory collections extending from the pancreatic and peripancreatic regions through the left retroperitoneum, along the left paracolic gutter and iliopsoas region, into the pelvis, and subsequently through a dilated left inguinal ring toward the left scrotal sac. The proposed mechanism is the dissection of pancreatic and retroperitoneal inflammatory fluid along anatomical planes of relatively low resistance. The retroperitoneal spaces and paracolic gutters provide potential pathways for inferior extension toward the pelvis. From the pelvis, inflammatory fluid may enter the inguinal canal through a patent, widened, or dilated deep inguinal ring and subsequently extend toward the scrotum.[2,3] In the present case, the continuous anatomical relationship demonstrated on CT supports this mechanism.

Several previous reports have described pancreatic or peripancreatic collections extending into the inguinoscrotal region. Skouras et al. reported inguinoscrotal extension of a pancreatic collection and highlighted the potential for this unusual presentation to mimic primary groin pathology.[2] Kalia et al described three patients with inguinoscrotal involvement associated with extensive pancreatic necrosis and retroperitoneal collections extending toward the pelvis.[3] Other reports have described scrotal hydrocele, intrascrotal collections, and acute scrotal presentations associated with acute pancreatitis.[4-8]

The clinical differential diagnosis of acute or painful inguinoscrotal swelling is broad and includes incarcerated or strangulated inguinal hernia, hydrocele, epididymo-orchitis, testicular torsion, scrotal abscess, and other local inflammatory conditions. In a patient with concurrent abdominal pain and acute pancreatitis, however, pancreatic or retroperitoneal extension should also be considered. Cross-sectional imaging is particularly useful because it can demonstrate the continuity between the abdominal inflammatory process and the inguinoscrotal abnormality.

In this patient, CT demonstrated a dilated left inguinal ring and extension of the inflammatory process toward the left scrotal sac. The available imaging could not establish whether the dilated ring represented a pre-existing patent processus vaginalis, an inguinal hernia-related anatomical defect, or another anatomical variant. Similarly, because scrotal ultrasonography and Doppler examination were not performed, the precise nature of the intrascrotal component could not be determined. A hydrocele, discrete intrascrotal collection, epididymal involvement, or testicular vascular abnormality therefore cannot be confirmed or excluded. The finding is consequently best described as inguinoscrotal extension of the pancreatic and retroperitoneal inflammatory process rather than as a specific scrotal complication.

An important aspect of this case is the distinction between radiological and clinical severity. The modified

CT severity index incorporates the extent of pancreatic inflammation, necrosis, and extrapancreatic complications and provides a radiological assessment of disease severity.[9] The patient's modified CT severity index was 8/10, indicating extensive radiological disease. However, the revised Atlanta classification defines severe acute pancreatitis according to persistent organ failure lasting more than 48 hours rather than by CT severity alone.[1] Current management guidelines similarly emphasize assessment of organ failure and complications when determining clinical severity and management strategy.[10]

The patient had renal dysfunction on admission, with a serum creatinine of 2.0 mg/dL. This corresponds to a modified Marshall renal score of 2.[11] Serum creatinine decreased to 1.0 mg/dL by hospital day 2 and subsequently remained below 1.0 mg/dL in the available measurements. No persistent respiratory or cardiovascular organ failure was documented. Thus, persistent organ failure lasting more than 48 hours was not demonstrated, and the clinical course was consistent with moderately severe acute pancreatitis according to the revised Atlanta classification despite the high radiological severity.

Alcohol was the most plausible etiological factor in this case. The patient reported substantial chronic alcohol consumption, while CT showed hepatic steatosis without gallstones, biliary dilatation, or another obvious obstructive biliary cause. Nevertheless, a complete etiological work-up, including serum triglyceride measurement, was not available. Therefore, the pancreatitis should be described as probable alcohol-associated pancreatitis rather than definitively alcohol-induced pancreatitis.

The history of black stools and possible melena represents an additional clinical feature but should be interpreted cautiously. The patient reported black stools and subsequently demonstrated a decline in hemoglobin from 14.7 g/dL on hospital day 1 to 10.1 g/dL on hospital day 9. However, no endoscopic evaluation was performed, and no source of gastrointestinal bleeding was established. The hemoglobin decline could therefore not be definitively attributed to gastrointestinal hemorrhage. Similarly, dysuria with pyuria and microscopic hematuria was noted, but no urine culture was available to establish a urinary tract infection. The management of pancreatic necrosis requires distinction between sterile and infected necrosis. Current guidelines do not recommend routine prophylactic antibiotic therapy for acute pancreatitis or sterile pancreatic necrosis; antimicrobial therapy is generally reserved for suspected or confirmed infection.[10] In this case, ceftriaxone was administered initially, followed by meropenem and metronidazole. However, there was no microbiological confirmation of infected pancreatic necrosis, and no intervention was undertaken to obtain a culture from the collections. The documented antimicrobial treatment should therefore not be interpreted as evidence that the pancreatic necrosis was infected.

The absence of local intervention is another notable feature. Previously reported patients with infected or clinically significant inguinoscrotal collections have required drainage and, in some cases, necrosectomy.[3] In contrast, this patient had no documented scrotal abscess, no scrotal imaging demonstrating a drainable collection, and no clinical deterioration attributable to the inguinoscrotal component. The patient improved with conservative management directed at the underlying pancreatitis, with concurrent improvement in renal function and pancreatic enzyme levels and slight reduction in the inguinoscrotal swelling.

Nutritional management consisted initially of nil per oral status and Ryle's tube decompression, followed by gradual reintroduction of oral feeding. Liquid feeding was initiated on hospital day 6 and advanced to a soft diet on hospital day 8 as tolerated. Although the patient received relatively prolonged initial bowel rest, the case illustrates successful clinical progression to oral feeding without local intervention for the inguinoscrotal component. The additional finding of an obstructing proximal right ureteric calculus with mild hydroureteronephrosis is noteworthy but anatomically separate from the left-sided pancreatic and retroperitoneal inflammatory pathway. It may have contributed to the patient's dysuria and microscopic hematuria, although a causal relationship cannot be established without further urological evaluation. Its contralateral location also argues against it being the source of the left inguinoscrotal inflammatory process.

This case has several limitations. First, scrotal ultrasonography and Doppler examination were not performed, preventing definitive characterization of the intrascrotal component and assessment of testicular vascularity. Second, no repeat CT was performed, so subsequent radiological resolution of the pancreatic, retroperitoneal, or inguinoscrotal collections could not be documented. Third, post-discharge clinical follow-up was unavailable. Fourth, the etiological evaluation of acute pancreatitis was incomplete because serum triglycerides and some other potential secondary causes were not documented. Fifth, the reported melena was not confirmed by endoscopy, and the cause of the subsequent hemoglobin decline remains uncertain. Finally, microbiological evidence of infected pancreatic necrosis was unavailable.

Despite these limitations, the case demonstrates a rare anatomical route of extension of pancreatic and retroperitoneal inflammation into the inguinoscrotal region. The continuous pathway demonstrated on contrast-enhanced CT from the pancreatic region through the left retroperitoneum and pelvis, across the dilated left inguinal ring, and toward the scrotum provides the principal diagnostic feature of this case. Recognition of

this pathway may prevent misdiagnosis of the inguinoscrotal presentation as an isolated primary scrotal or inguinal disorder and may help guide appropriate conservative, radiological, surgical, or urological management according to the patient's clinical condition.

CONCLUSION

Acute pancreatitis can rarely extend beyond the pancreatic and peripancreatic compartments and track through the retroperitoneum, pelvis, and inguinal canal toward the scrotum. In this case, contrast-enhanced CT demonstrated a continuous pathway of inflammatory extension from necrotizing pancreatitis through the left retroperitoneum and pelvis, across a dilated left inguinal ring, and toward the left scrotal sac. In a patient with acute pancreatitis and new-onset inguinoscrotal swelling, pancreatic extension should be considered in the differential diagnosis of acute inguinal or scrotal pathology. Cross-sectional imaging is particularly valuable for identifying the anatomical pathway and distinguishing secondary pancreatic extension from primary inguinoscrotal disease. In selected patients without evidence of infected or otherwise complicated scrotal involvement, treatment of the underlying pancreatitis may result in clinical improvement without local intervention. In the present case, the precise nature of the intrascrotal component could not be established because scrotal ultrasonography and Doppler examination were not performed, and no follow-up imaging was available.

Funding: No funding sources
Conflict of interest: None declared
Ethical approval: Not required

REFERENCES

1. Banks PA, Bollen TL, Dervenis C, et al. Classification of acute pancreatitis—2012: revision of the Atlanta classification and definitions by international consensus. Gut. 2013;62:102-111.
2. Skouras C, Skouras T, Pai M, et al. Inguinoscrotal extension of a pancreatic collection: a rare complication of pancreatitis—case report and review of the literature. Updates Surg. 2013;65:153-159.
3. Kalia S, Gupta R, Shenvi SD, et al. Inguinoscrotal region as an unusual site of extra-pancreatic collections in infected pancreatic necrosis. Gastroenterol Rep (Oxf). 2016;4:246-250.
4. Loloi J, Clark JY. Scrotal hydrocele in acute pancreatitis. Urology. 2019;132:5-7.
5. Sood A, Cole D, Alanee S. Acute scrotum in setting of acute pancreatitis. BMJ Case Rep. 2018;2018:bcr2017223199.
6. Naresh D, de Kock S. Acute pancreatitis presenting as acute scrotum. BMJ Case Rep. 2023;16(2):e253867.
7. Moens L, Yengue Yengue P, Assenmacher C. Intrascrotal collection in an acute pancreatitis: a case report and review of the literature. Case Rep Urol. 2016;2016:7534781.
8. Chen W, Wang X, Zhang J. Left scrotal swelling caused by severe acute pancreatitis in a 38-year-old Chinese male. Int J Clin Exp Med. 2015;8(5):8194-6.
9. Mortele KJ, Wiesner W, Intriere L, Shankar S, Zou KH, Kalantari BN, et al. A modified CT severity index for evaluating acute pancreatitis: improved correlation with patient outcome. AJR Am J Roentgenol. 2004;183:1261-1265.
10. Tenner S, Vege SS, Sheth SG, Sauer B, Yang A, Conwell DL, et al. American college of gastroenterology guidelines: management of acute pancreatitis. The American Journal of Gastroenterology. 2023;119(3):419.
11. Marshall JC, Cook DJ, Christou NV, Bernard GR, Sprung CL, Sibbald WJ. Multiple organ dysfunction score: a reliable descriptor of a complex clinical outcome. Critical care medicine. 1995;23(10):1638-52.

Cite this article as: Mujawar ATN, Chavan SS, Gorad K, Magdum S, Hake PD. Acute necrotizing pancreatitis with retroperitoneal extension into the scrotum through a dilated inguinal ring: a case report. Int Surg J 2026;13:2635-41.