International Surgery Journal
Vera Flores JM et al. Int Surg J. 2026 Dec;13(12):2595-2602
https://www.ijsurgery.com
pISSN 2349-3305 | eISSN 2349-2902

DOI: https://dx.doi.org/10.18203/2349-2902.isj20264369

Case Report

Endovascular management of a giant thoracic aortic aneurysm sac rupture due to type IB endoleak with a pre-established iliac conduit

Juan Moctezuma Vera Flores*, José M. Cruz Pérez, José A. Barajas Colón

Department of Angiology and Vascular Surgery, Centro Médico Nacional Siglo XXI, Instituto Mexicano del Seguro Social, Mexico City, Mexico City, Mexico

Received: 03 October 2026
Revised: 04 November 2026
Accepted: 18 November 2026

***Correspondence:**
Juan Moctezuma Vera Flores,
E-mail: moctezumavera95(@gmail.com

Copyright: © the author(s), publisher and licensee Medip Academy. This is an open-access article distributed under the terms of the Creative Commons Attribution Non-Commercial License, which permits unrestricted non-commercial use, distribution, and reproduction in any medium, provided the original work is properly cited.

ABSTRACT

Endoleaks are the most common post-TEVAR complication, clinically relevant due to the risk of persistent pressurization of the aneurysmal sac and hence rupture with mortality ranging from 44% to 100%. TEVAR requires delivery systems ranging from 18 Fr to 24 Fr, sometimes needing the creation of an iliac conduit using whether open or endovascular techniques. Repeatedly used iliac conduit grafts may lead to further local increased difficulty for their manipulation or use for future procedures. We present the case of a 64-year-old man presenting to the emergency department due to thoracic pain. He had two previous endovascular aortic aneurysm repairs (thoracic and abdominal). The contrast-enhanced Computed Tomographic scan revealed a type 1B endoleak in the descending aorta with an 11.5 cm aortic sac diameter enlargement which had a spontaneous rupture 4 days after admission, requiring an emergency management using a previous iliac conduit which had been used two times before leading to a hostile anatomic area, and hemothorax drainage. This case highlights the importance of close monitoring after any endovascular aortic repair due to the risk of stent-graft associated complications like endoleaks and their consequences, as well as the importance of the creation of a successful permanent vascular access through iliac conduits due to the possibility of further procedures.

Keywords: Aortic aneurysm, Type IB endoleak, Aneurysm rupture, Iliac conduit, Endovascular

INTRODUCTION

Aneurysmal dilatation of the Descending Thoracic Aorta is a degenerative disease with an incidence of 6 to 10.4 per 100,000 persons per year, which increases with population aging and improvements in diagnostic studies.[1] Since the first thoracic endovascular aortic repair (TEVAR) reported in 1994, there has been a significant increase in the use of endovascular techniques, along with reductions in perioperative morbidity and mortality, shorter hospital stays and faster recovery.[2] With the rise in endovascular surgery, procedure-related complications have emerged, which must be correctly identified and managed to prevent late adverse outcomes. Endoleaks are the most common post-TEVAR complication, associated with an increased risk of reintervention and considered an independent risk factor for long-term mortality, with a hazard ratio of 4.6 and an incidence of up to 10.4%.[3-5]

The most frequent types are type I (attachment sites) and type III (structural defect), both clinically relevant because they lead to persistent pressurization of the aneurysmal sac, resulting in continued growth and rupture risk, which can be life-threatening if untreated. Mortality after thoracic aneurysm rupture ranges from

44% to 100%, similar to that reported after abdominal aneurysm rupture following EVAR: 42%, rising to 78% in hemodynamically unstable patients.[6-10]

TEVAR requires delivery systems ranging from 18 Fr to 24 Fr; therefore, one of the most critical considerations is vascular access, as a minimum diameter of 7 mm in the common femoral arteries is necessary.[11] An alternative in cases without adequate vascular access is the creation of an iliac conduit, which consists of placing an 8–10 mm synthetic graft onto the common iliac artery through a lateral retroperitoneal anastomosis, exteriorized to allow the introduction of devices.[12] The iliac conduit should be further studied to determine its functionality and safety as a vascular access alternative.

CASE REPORT

The case of a 64-year-old man was reported with a history of systemic arterial hypertension diagnosed 6 years earlier under medical treatment, dyslipidemia diagnosed 6 years earlier under medical treatment, and chronic obstructive pulmonary disease diagnosed 6 years earlier under medical treatment. He had a history of active smoking from age 11 to 59, averaging 20 cigarettes per day, with a smoking index of 144. The subject was diagnosed with a descending thoracic aortic aneurysm and an infrarenal abdominal aortic aneurysm, which required thoracic endovascular aortic repair (TEVAR) and a left iliofemoral bypass (common iliac artery end-to-side to common femoral artery side-to-end) with a 10-mm synthetic graft, used as an iliac conduit.

Figure 1 shows the baseline computed tomography angiography (CTA) performed 1 month prior to TEVAR, where the yellow arrows indicate the small iliac arteries (average size of 6 mm), while Figure 2 represents the CTA performed 9 months after the TEVAR, where it demonstrates absence of any type of endoleak (yellow arrowheads), patent left native external iliac artery (yellow arrow) and iliac conduit anastomosed to the left common iliac artery to the common femoral artery (red arrow). Additionally, the infrarenal abdominal aortic aneurysm underwent endovascular repair (EVAR) a year after, as shown in Figure 3 where the CTA performed 2 weeks after shows no endoleak development, the recent occluded left native external iliac artery (yellow arrow) and patent iliac conduit (red arrow).

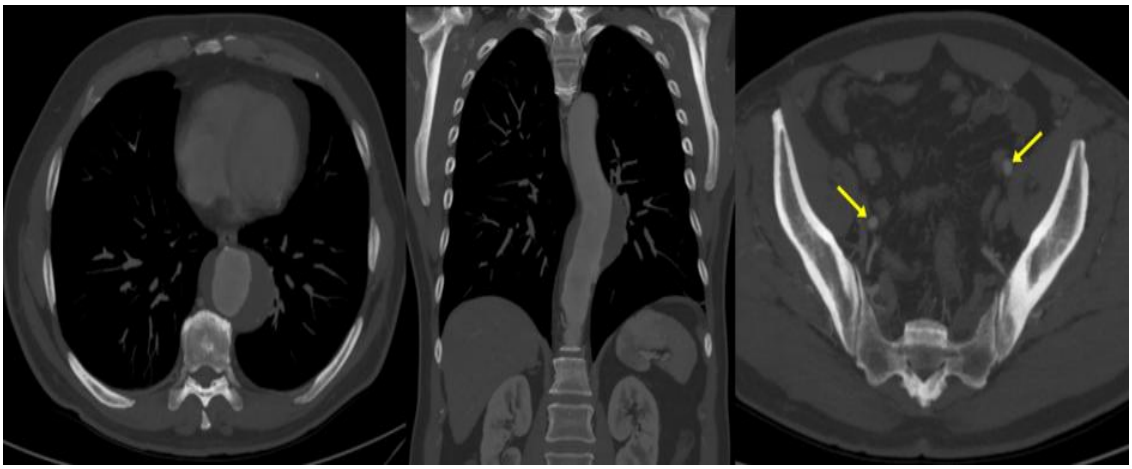

Figure 1: Initial CTA.

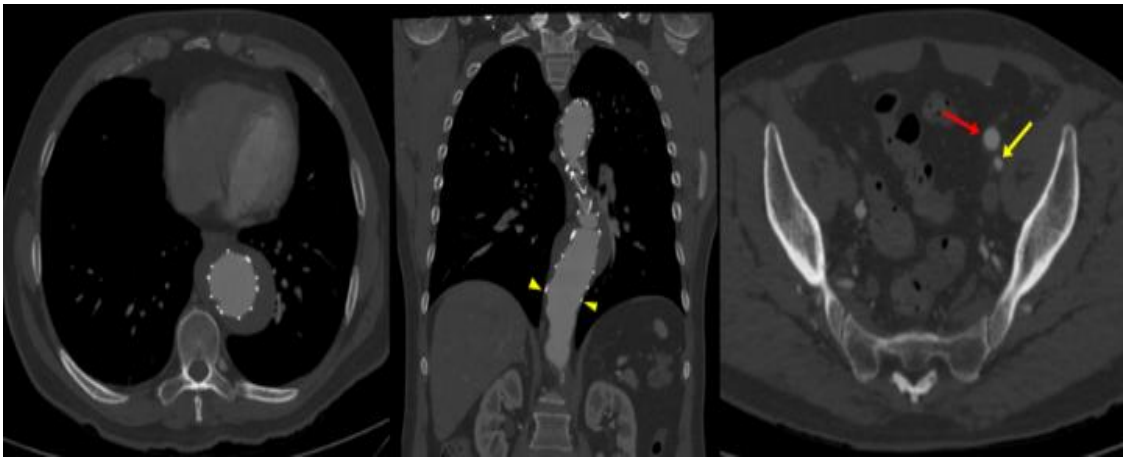

Figure 2: CTA 9 months after TEVAR.

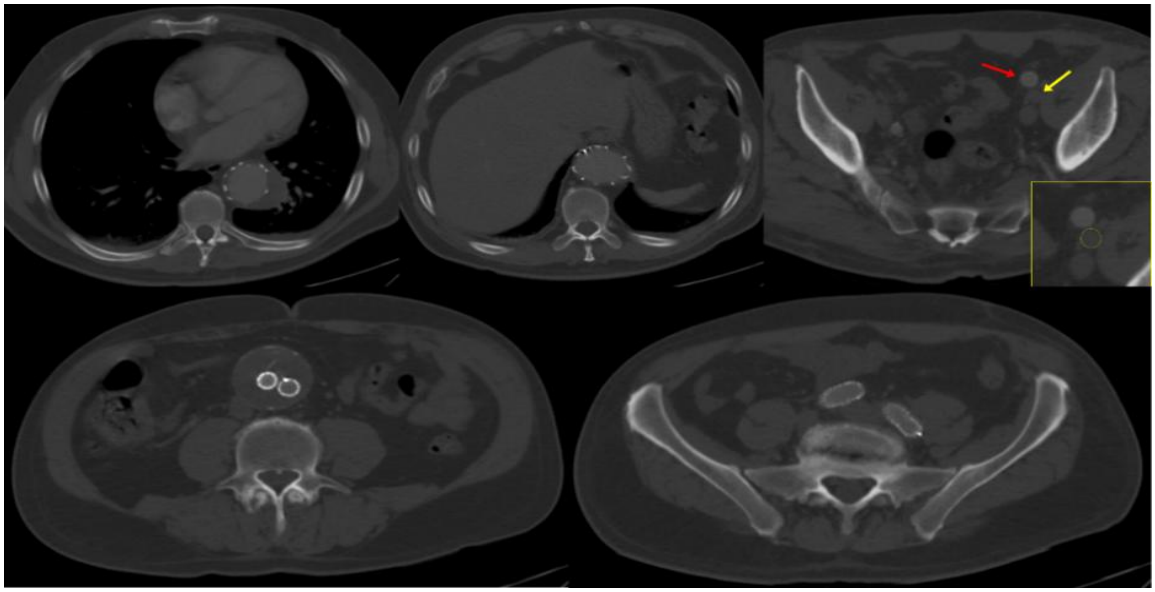

Figure 3: CTA 2 weeks after EVAR.

After 4 years and 6 months of endovascular treatment, the patient presented with stabbing epigastric pain, intensity 7/10 on the visual analogue scale, accompanied by dizziness. He went to his initial referral hospital where a CT angiography was performed. Given the finding of a type IB endoleak, he was referred to this national medical center. On admission, the patient showed no neurological alterations, was hemodynamically stable, did not require ventilatory support, and had normal thoracic and abdominal physical examination. Upper and lower limbs showed preserved arterial integrity, normothermia, immediate capillary refill, as well as preserved strength, mobility, and sensitivity.

CT angiography of the chest and abdomen identified a thoracoabdominal aortic aneurysm classified as Crawford II, with a thoracic endograft (extending from 2 cm distal to the left subclavian artery ostium to T10, 85 mm proximal to the celiac trunk ostium), an abdominal endograft (infrarenal fixation to the bifurcation of both common iliac arteries), and a type IB endoleak of the thoracic endograft with an aneurysmal sac measuring 115 mm (lateral) × 102 mm (anteroposterior), without signs of rupture, albeit presence of 20% right pleural effusion as shown in Figure 4 (yellow arrows indicate contrast leakage at the distal thoracic anchor site).

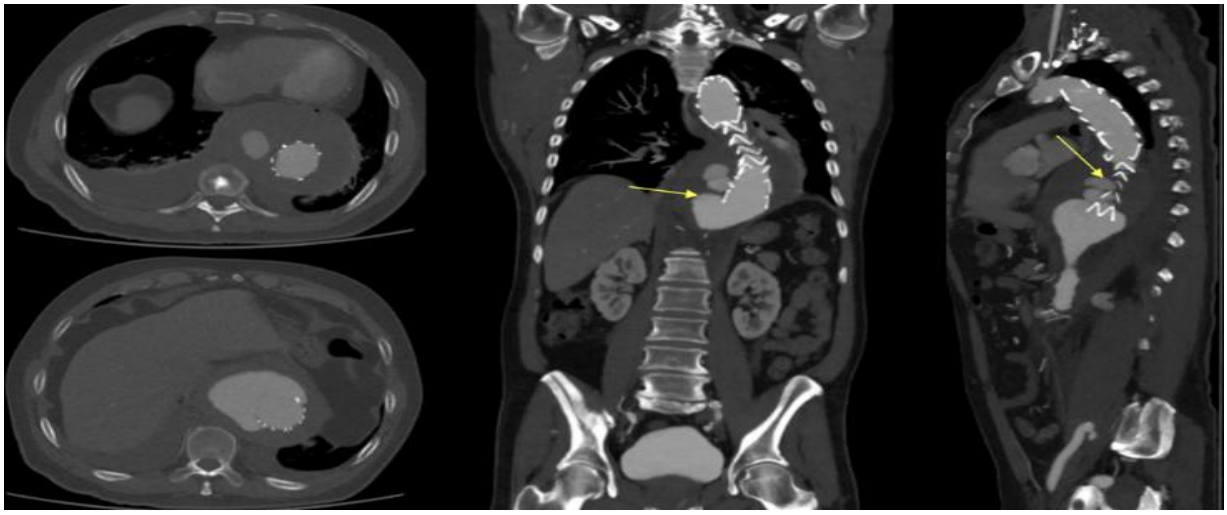

Figure 4: CTA at hospital admission.

The patient was admitted for an endovascular repair protocol. However, 4 days after admission he developed severe exacerbation of pain, dyspnea, and respiratory distress. A new CTA revealed an increase in the right pleural effusion (to 50%) with contrast leakage (yellow arrows) and enlargement of the thoracic aneurysmal sac (10 mm increase compared with prior imaging), findings suggestive of sac rupture as shown in Figure 5. Hemoglobin dropped by 2.8 g/dL, leading to the decision to perform an emergency endovascular repair. The patient

was urgently taken to the catheterization lab, where endovascular repair of the thoracoabdominal aneurysm was performed at the supraceliac portion (site of the endoleak causing the rupture) with deployment of a C-TAG 45 × 200 mm thoracic endograft, overlapping by 8 cm, covering up to the proximal portion adjacent to the celiac trunk ostium (Figure 6).

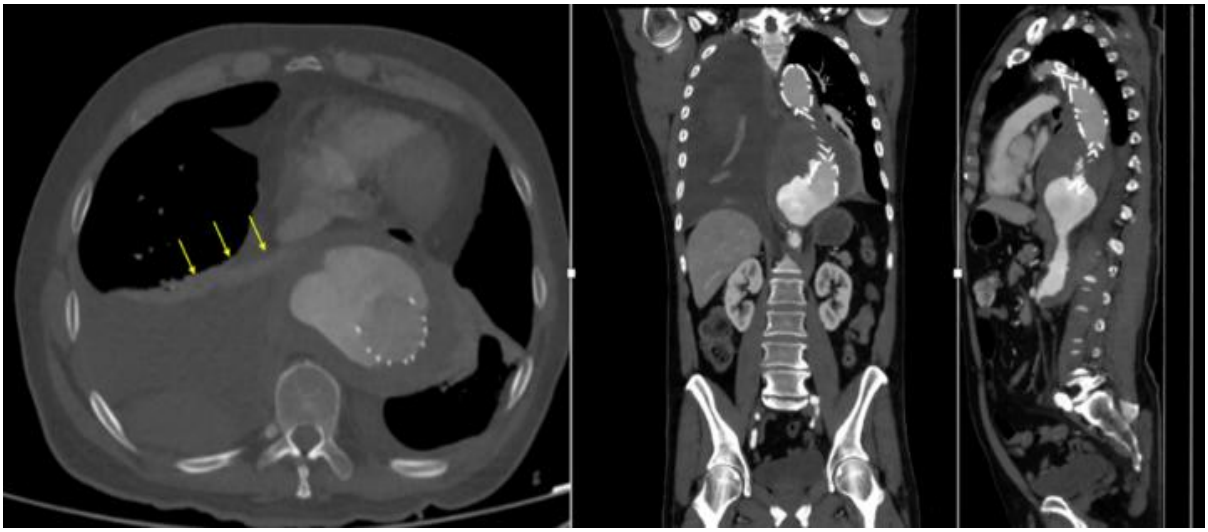

Figure 5: CTA 4 days after admission (rupture of aneurysmal sac).

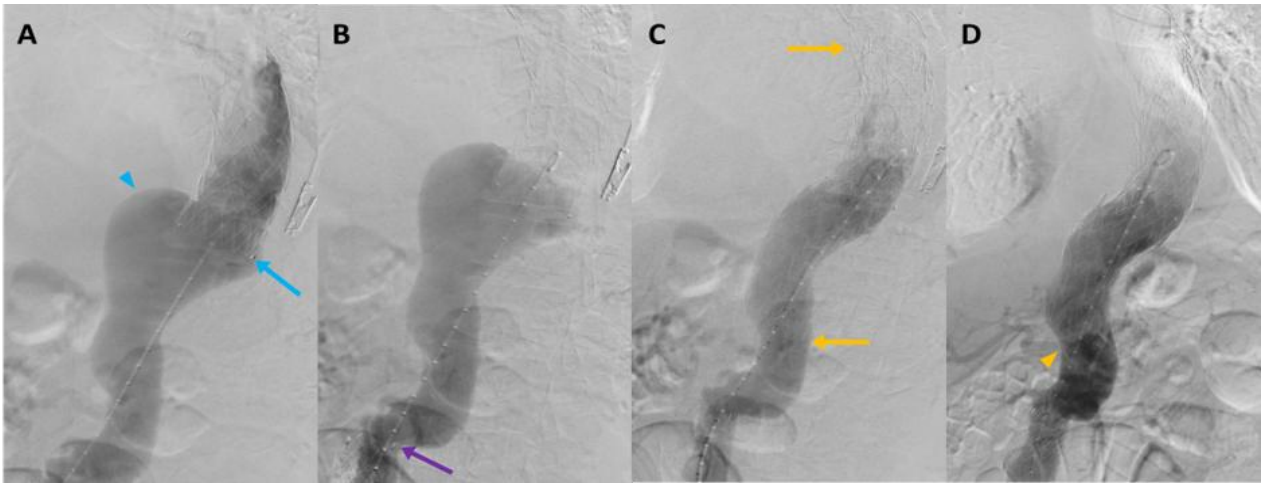

Figure 6: Emergency TEVAR; (A) Initial aortogram showing aneurysmal dilation (blue arrowhead) and the distal sealing zone of the previous thoracic endoprosthesis (blue arrow); (B) Proximal portion of the infrarenal abdominal endoprosthesis, approximately 140 mm from the distal edge of the thoracic endoprosthesis (purple arrow); (C and D) New thoracic stent graft deployed above the celiac trunk ostium, with no residual endoleaks (orange arrowhead indicates the celiac trunk and orange arrows indicate the proximal anchoring and distal sealing areas of the new thoracic stent graft spliced with the previous one).

For the procedure, an open dissection of the previously constructed iliac conduit at the left groin was necessary (its third use for endovascular repair) creating a hostile anatomical site. Dissection revealed the vascular graft used as iliac conduit, surrounded by abundant fibrous tissue; the common femoral artery was friable with marked perivascular fibrosis. These features led to a technically challenging dissection, requiring subsequent revision with a new iliofemoral bypass from the previous graft to the superficial femoral artery using a 6-mm ringed straight graft, as shown in Figure 7.

At the end of the procedure, distal pulses were preserved with no change in ankle-brachial index compared with pre-procedure values. A CTA performed after the procedure reveals absence of endoleaks and adecuate coverage of the descending thoracic aorta, however showing an increase in pleural effusion of up to 85% (Figure 8). A right pleural drain was later placed for hemothorax, draining 1050 cc within the first 24 hours, but a right thoracotomy was ultimately required for retained hemothorax. Series of following chest X-rays displayed the resolution of the pleural effusion as shown in Figure 9

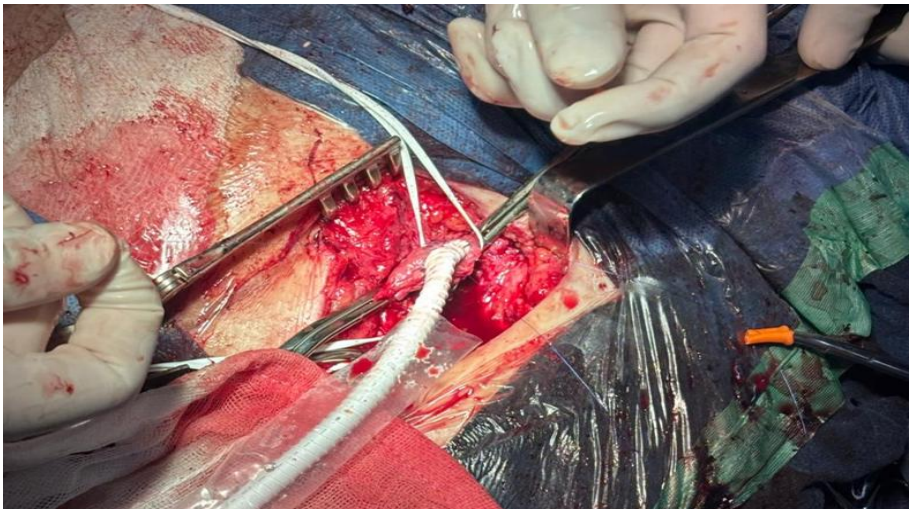

Figure 7: Left femoral reconstruction.

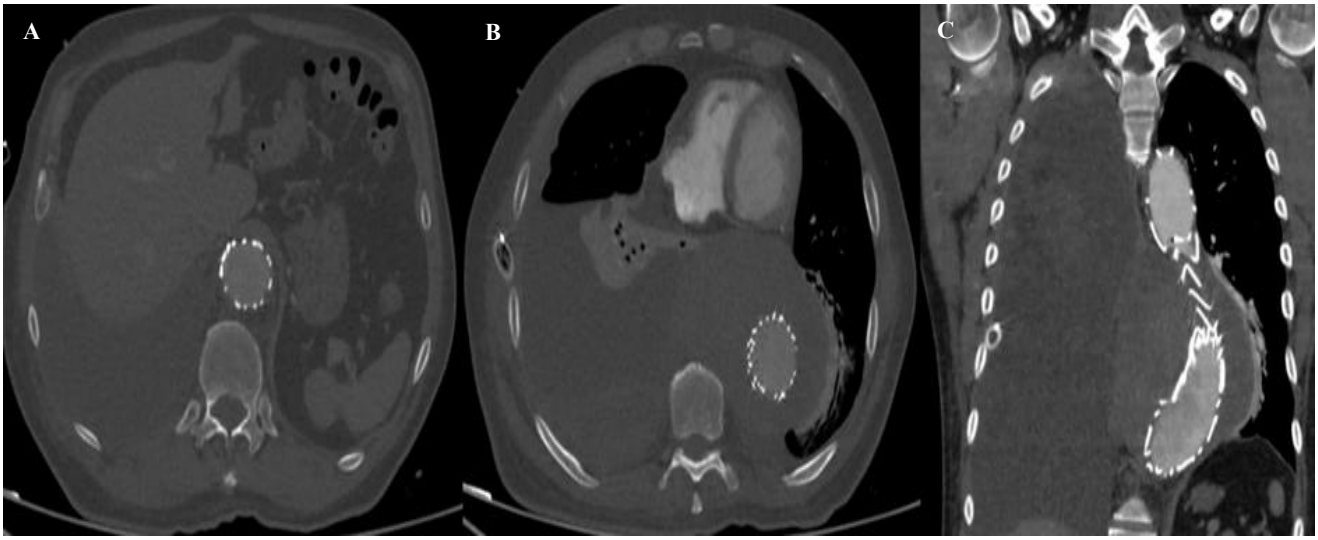

Figure 8 (A-C): CTA following emergency TEVAR.

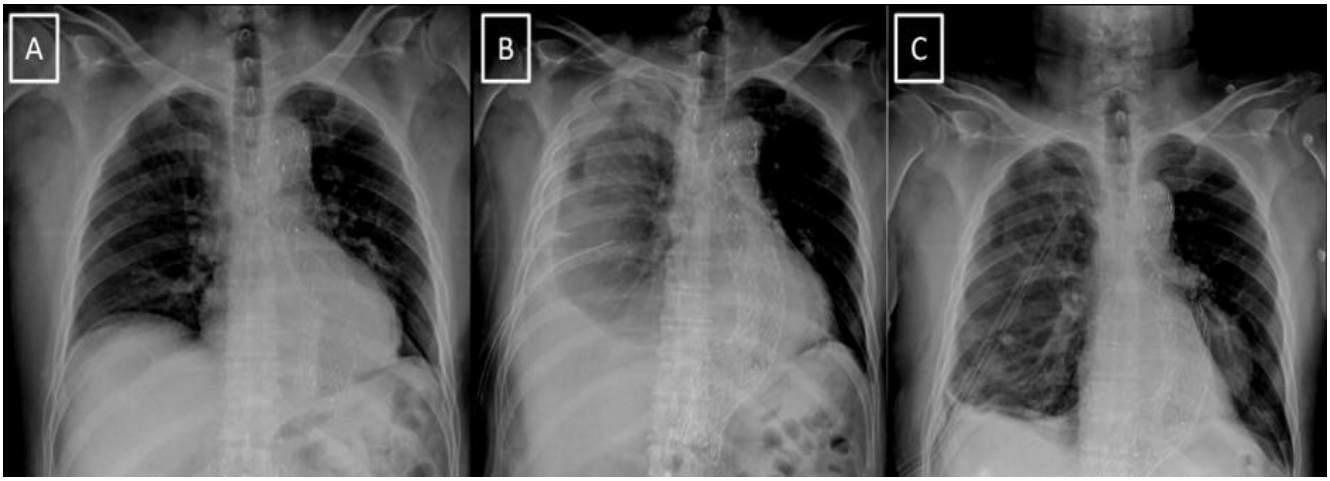

Figure 9: Serial chest X-rays; (A) Chest X-ray taken when the patient was admitted to hospital, with no evidence of right hemothorax; (B) Chest X-ray after insertion of the endopleural tube on the right side, placed after emergency TEVAR, showing significant blurring of the right costophrenic angle and pulmonary opacity; (C) Chest X-ray after open thoracotomy, showing adequate right lung expansion.

Following emergency endovascular treatment, the patient was admitted to the Intensive Care Unit for 5 days and discharged 21 days after the procedure, without evidence of spinal cord ischemia. The series of 3D reconstructions can be observed in Figure 10 where image A shows the Aneurysmal dilation of the descending thoracic aorta; image B the first thoracic endoprosthesis with no evidence of endoleak and the presence of a patent iliac duct together with the native artery; image C the thoracic and abdominal endografts, with the currently native left external iliac artery occluded; and image D the two thoracic stents visible with no evidence of endoleak.

DISCUSSION

Endeleaks are defined as the persistence of blood flow withing the aneurysmal sac after the deployment of the stent-graft, and can be defined as early (when the occur within the first 30 days after the procedure) or late (after the first 30 days). They are classified into 5 types (White's classification): Type I occurs when the persistent blood flow comes from the proximal sealing zone (Type IA) or distal sealing zone (Type IB), this last one with a reported frequency of 0-8% after an EVAR; Type II is defined when the blood comes from backbleeding side branches like the inferior mesenteric artery, middle sacral artery or lumbar branches; Type III results from leak between the components (only modular grafts) or fabric defect; Type IV are related to porosity of the graft material; Type V, also known as "endotension", occurs when the aneurysm sac continues growing without a demonstrable endoleak.[13,14] Endoleaks are the most frequent complication after an endovascular aneurysm repair (whether a thoracic or abdominal aneurysm).[15] The main concern of an endoleak is the persistence of a growing sac that leads to an early or delayed aneurysm rupture, hence the importance of a treatment.[16] There are very few published articles related to delayed rupture (>30 days after EVAR) after endovascular abdominal aneurysm repair and no published data related to the frequency of delayed rupture after delayed TEVAR due to endoleaks.

In a retrospective multicentre study published by Candell L et al, it was found that 20 out of 1736 subjects (1.2%) that had an EVAR developed rupture. Five out of those 20 subjects (0.29%) had an early rupture (40% of mortality) and 15 (0.86%) had a delayed rupture (with an average time of 31 months). Those with a delayed rupture who didn't receive any intervention had a 100% mortality, meanwhile those who received whether open or endovascular intervention, 30-day mortality was 44% and 66.7% in the first year. The conclusions of the study were that the incidence of delayed rupture in patients treated with EVAR for an abdominal aneurysm in 3 years was 0.86% with a 100% mortality of those without intervention.[16] Another study published by Oderich et al where 1109 subjects who underwent elective Fenestrated-Branched endovascular aortic repair of a thoracoabdominal aortic aneurysm, 4 (0.4%) developed early aortic rupture with an overall mortality of 75%, meanwhile 14 of 1062 subjects who were available for late clinical visits (1.3%) developed late aortic rupture within an average of 3.1 years, with an overall mortality of 85.7%.[17] In this study they describe the extension of the thoracoabdominal aneurysm as the only risk factor for late aortic rupture, a characteristic present in this patient. Another similar study published by Katsargyris et al where 331 subjets who underwent a FEVAR (Fenestrated EVAR) were followed-up within an average of 49 months, the incidence of late rupture was 0.91%.[18]

On a meta-analysis published by George A. Antoniou et al where 11 articles and a total of 16,974 patients were included, they found an incidence of 0.9% of late rupture after an EVAR with a mean time to rupture of 37 months, overall perioperative mortality of 32% and type I and III as the predominant causes of rupture.[19] The management of a Type IB endoleak relies on the mechanism of failure, but it's usually solvable with the deployment of a distal extension.[20]

On the other hand, an open iliac conduit is defined as a surgically placed conduit to obtain access for the endovascular devices, usually set at the common iliac artery with an 8-10 mm synthetic vascular graft (Dacron or ePTFE). They are usually needed when the iliac or femoral anatomy result unfavourable: iliac tortuosity, small diameter or diseased arteries and diffuse severe calcification of access vessels. After the implantation of the graft and once withdrawn the endovascular devices, the vessel graft may either be removed (leaving a small oversewn stump) or anastomosed distally to the common femoral artery, thus creating an ilio-femoral bypass.[21] However, iliac conduits are not free from potential harm: in a recent meta-analysis published by Giannopoulos et al was found that either open or endovascular iliac conduits were utilized in 17% of 16,855 aneurysm endovascular repair cases, with an incidence of periprocedural complications of 32% such as bleeding or wound complications and were associated with an increased rate of longer hospitalization and mortality.[12] In a retrospective study published by Gupta et al, they describe 231 patients who underwent an iliac conduit placement out from 14,399 who underwent elective endovascular aneurysm repair (1.6%). These patients also had a higher incidence of complications: with and OR of 2.3 for 30-day major morbidities and OR of 2.7 for 30-day mortality.[22] Hence, in spite of the inherently associated risks and iliac conduit placement lets an endovascular repair feasible, lowering the overall morbidity and mortality associated with an open approach.

Spinal cord ischemia is a devastating neurological condition characterized by a reduction or interruption of blood flow to the spinal cord, leading to tissue damage and neurological deficits The most common etiologies include aortic and vertebral artery arteriosclerosis, aortic surgery or aneurysm repair, arterial dissection, and less

frequently, systemic hypotension, embolic disease, or vascular malformations.[23] It is a complication that can occur following both open and endovascular repair of aortic aneurysms, especially in thoracoabdominal and complex aneurysms. The rate of spinal cord ischemia after endovascular repair of thoracoabdominal aneurysm repair have been reported as high as 20%.[24] Clinically, it is characterized by an abrupt neurological deficit, most commonly presenting as anterior spinal cord syndrome, which involves bilateral motor and pain/temperature sensory loss with relative preservation of proprioception.

The most important risk factors to consider for aneurysm repair include: the length of the aorta covered by the stent graft, thoracoabdominal aneurysms (especially Crawford Extent I-III), previous aortic surgery, renal disease, advanced age and cardiac arrhythmias. Some strategies that reduce the risk of spinal cord ischemia include: cerebrospinal fluid drainage, staged surgical procedures which reduce the risk compared to performing a single procedure maintaining optimal hemoglobin levels, and maintaining adequate mean arterial perfusion pressure.[25]

A staged procedure consists of dividing the aortic repair into two or more surgeries, allowing that, when blood supply to the spinal cord is reduced or interrupted, collateral circulation can adapt, thereby improving spinal cord tolerance to ischemia. In a cohort study reported by O'Callaghan et al they found an in single-stage procedures, the risk of spinal cord ischemia is up to 37.5% of patients, compared with staged procedures with a risk of 11.1%. Similarly, mortality is 18.8% in single-stage procedures compared with 0% in staged procedures.[26]

CONCLUSION

In this rare case, the subject underwent a TEVAR with an iliac conduit and an EVAR a year after, developing a undiagnosed thoracic Type IB endoleak which further triggered the rupture of the thoracic growing aneurysmal sac. In spite of the high reported mortality of this condition, the patient survived. The challenging aspect of this case was the need to use for a third time, a previously used iliac conduit which determined the need to do a femoral bypass due to a native femoral injury. Despite the extent of the aortic coverage, the patient did not develop spinal cord ischemia symptoms.

Funding: No funding sources
Conflict of interest: None declared
Ethical approval: Not required

REFERENCES

1. Coady MA, Ikonomidis JS, Cheung AT, Matsumoto AH, Dake MD, Chaikof EL, et al. Surgical management of descending thoracic aortic disease: open and endovascular approaches: a scientific statement from the American Heart Association. Circulation. 2010;121(25):2780-804.
2. Dake MD, Miller DC, Semba CP, Mitchell RS, Walker PJ, Liddell RP. Transluminal placement of endovascular stent-grafts for the treatment of descending thoracic aortic aneurysms. N Engl J Med. 1994;331(26):1729-34.
3. Tanious A, Boitano L, Canha L, Chou EL, Wang LJ, Latz C, et al. Thoracic aortic remodeling with endografting after a decade of thoracic endovascular aortic repair experience. J Vasc Surg. 2021;73(3):844-9.
4. Chen SW, Zhong YL, Qiao ZY, Li CN, Ge YP, Qi RD, et al. One-stage hybrid procedure for distal aortic arch disease: mid-term experience at a single center. J Thorac Dis. 2020;12(12):7117-26.
5. Ricotta JJ 2nd. Endoleak management and postoperative surveillance following endovascular repair of thoracic aortic aneurysms. J Vasc Surg. 2010;52(4 Suppl):91S-9S.
6. Deniz G, Kasımzade F, Ozcınar E, Yazicioglu L, Eryılmaz S. Long-term outcomes of TEVAR for thoracic aortic diseases: a retrospective single-center study. J Cardiothorac Surg. 2024;19(1):405.
7. Johansson G, Markström U, Swedenborg J. Ruptured thoracic aortic aneurysms: a study of incidence and mortality rates. J Vasc Surg. 1995;21(6):985-8.
8. Gouveia E Melo R, Silva Duarte G, Lopes A, Alves M, Caldeira D, Fernandes E Fernandes R, et al. Incidence and prevalence of thoracic aortic aneurysms: a systematic review and meta-analysis of population-based studies. Semin Thorac Cardiovasc Surg. 2022;34(1):1-16.
9. Moulakakis KG, Lazaris AM, Georgiadis GS, et al. A Greek multicentre study assessing the outcome of late rupture after endovascular abdominal aortic aneurysm repair. Eur J Vasc Endovasc Surg. 2024;67(5):756-64.
10. Jones M, Faris P, Moore R. Mortality and risk factors for ruptured abdominal aortic aneurysm after repair endovascular (rARE). J Vasc Surg Cases Innov Tech. 2023;9(3):101165.
11. Peterson BG. Conduits and endoconduits, percutaneous access. J Vasc Surg. 2010;52(4 Suppl):60S-4S.
12. Giannopoulos S, Malgor RD, Sobreira ML, Siada SS, Rodrigues D, Al-Musawi M, et al. Iliac conduits for endovascular treatment of aortic pathologies: a systematic review and meta-analysis. J Endovasc Ther. 2021;28(4):499-509.
13. Zuccon G, D'Oria M, Gonçalves FB, Fernandez-Prendes C, Mani K, Caldeira D, et al. Incidence, risk factors, and prognostic impact of type Ib endoleak following endovascular repair for abdominal aortic aneurysm: scoping review. Eur J Vasc Endovasc Surg. 2023;66(3):352-61.
14. Cassagnes L, Pérignon R, Amokrane F, et al. Aortic stent-grafts: endoleak surveillance. Diagn Interv Imaging. 2016;97(1):19-27.

15. Stoecker J, Glaser J. Review of type III endoleaks. Semin Intervent Radiol. 2020;37:371-6.
16. Candell L, Tucker LY, Goodney P, Walker J, Okuhn S, Hill B, et al. Early and delayed rupture after endovascular abdominal aortic aneurysm repair in a 10-year multicenter registry. J Vasc Surg. 2014;60(5):1146-53.
17. Oderich GS, Huang Y, Harmsen WS, Tenorio ER, Schanzer A, Timaran CH, et al.; United States Aortic Research Consortium. Early and late aortic-related mortality and rupture after fenestrated-branched endovascular aortic repair of thoracoabdominal aortic aneurysms: a prospective multicenter cohort study. Circulation. 2024;150(17):1343-53.
18. Katsargyris A, Marques de Marino P, Hasemaki N, Nagel S, Botos B, Wilhelm M, et al. Editor's choice - single centre midterm experience with primary fenestrated endovascular aortic aneurysm repair for short neck, juxtarenal, and suprarenal aneurysms. Eur J Vasc Endovasc Surg. 2023;66(2):160-6.
19. Antoniou GA, Georgiadis GS, Antoniou SA. Late rupture of abdominal aortic aneurysm after previous endovascular repair: a systematic review and meta-analysis. J Endovasc Ther. 2015;22(5):734-44.
20. Wanhainen A, Van Herzeele I, Bastos Goncalves F, Bellmunt Montoya S, Berard X, Boyle JR, et al. European Society for Vascular Surgery (ESVS) 2024 clinical practice guidelines on the management of abdominal aorto-iliac artery aneurysms. Eur J Vasc Endovasc Surg. 2024;67(2):192-331.
21. Criado FJ. Iliac arterial conduits for endovascular access: technical considerations. J Endovasc Ther. 2007;14(3):347-51.
22. Gupta PK, Sundaram A, Kent KC. Morbidity and mortality after use of iliac conduits for endovascular aortic aneurysm repair. J Vasc Surg. 2015;62(1):22-6.
23. Weidauer S, Nichtweiss M, Hattingen E, Berkefeld J. Spinal cord ischemia: aetiology, clinical syndromes and imaging features. Neuroradiology. 2015;57:241-57.
24. Spanos K, Kölbel T, Kubitz JC, Wipper S, Konstantinou N, Heidemann F, et al. Risk of spinal cord ischemia after fenestrated or branched endovascular repair of complex aortic aneurysms. J Vasc Surg. 2019;69(2):357-66.
25. Rinaldi E, Melloni A, Gallitto E, et al. Spinal cord ischemia after thoracoabdominal aortic aneurysms endovascular repair: from the Italian multicenter fenestrated/branched endovascular aneurysm repair registry. J Endovasc Ther. 2023;30(2):281-8.
26. O'Callaghan A, Mastracci TM, Eagleton MJ. Staged endovascular repair of thoracoabdominal aortic aneurysms limits incidence and severity of spinal cord ischemia. J Vasc Surg. 2015;61(2):347-54.e1.

Cite this article as: Flores JMV, Pérez JMC, Colón JAB. Endovascular management of a giant thoracic aortic aneurysm sac rupture due to type IB endoleak with a pre-established iliac conduit. Int Surg J 2026;13:2595-602.