International Surgery Journal
Kumaravel M et al. Int Surg J. 2026 Dec;13(12):2631-2634
https://www.ijsurgery.com
pISSN 2349-3305 | eISSN 2349-2902

DOI: https://dx.doi.org/10.18203/2349-2902.isj20264377

Case Report

Surgical excision of a mediastinal venolymphatic malformation in a 2-year-old: a case report

Mahindan Kumaravel, Rohit Kumar Rathi, Roman Dutta, Sabyasachi Bal*

Department of Thoracic Surgery & Thoracic Surgical Oncology, Sir Ganga Ram Hospital, New Delhi, India

Received: 23 September 2026
Revised: 22 October 2026
Accepted:07 November 2026

***Correspondence:**
Dr. Sabyasachi Bal,
E-mail: drsbal@gmail.com

Copyright: © the author(s), publisher and licensee Medip Academy. This is an open-access article distributed under the terms of the Creative Commons Attribution Non-Commercial License, which permits unrestricted non-commercial use, distribution, and reproduction in any medium, provided the original work is properly cited.

ABSTRACT

Mediastinal venolymphatic malformations are rare congenital low-flow vascular anomalies that occasionally present as anterior mediastinal masses in young children and may mimic malignancy. We describe a previously healthy 2-year-old boy who presented with two to three weeks of recurrent cough that disturbed sleep and intermittent fever. A chest radiograph showed mediastinal widening, and computed tomography identified an anterior mediastinal mass. A computed tomography-guided core biopsy performed elsewhere reported a benign vascular-lymphatic lesion. Contrast-enhanced magnetic resonance imaging demonstrated a solid-cystic mass measuring 67 by 50 by 73 millimetres, abutting the great vessels without intraluminal extension or compression. The lesion was excised completely through a median sternotomy together with the adjacent thymus. The right phrenic nerve was inseparable from the mass, so the involved segment was resected, followed by right hemidiaphragm plication. Histopathology confirmed a benign venolymphatic malformation. The child remained asymptomatic at three months with a stable diaphragmatic position. This case demonstrates that complete surgical excision is feasible and provides early disease control for a localized, fully resectable mediastinal venolymphatic malformation, highlighting the role of resectability in treatment planning.

Keywords: Venolymphatic malformation, Mediastinal mass, Phrenic nerve, Diaphragmatic plication, Child

INTRODUCTION

Venolymphatic malformations are congenital low-flow vascular anomalies composed of dilated venous and lymphatic channels lined by normal endothelium. They are classified as combined vascular malformations and differ from vascular tumors in their congenital origin and lack of endothelial proliferation.[1] Primary mediastinal involvement is uncommon, with isolated cases reported in children and adults and pediatric cases are particularly rare.[2-4] In the anterior mediastinum these lesions can mimic thymic neoplasms.[2] Published reports largely describe observation of high-risk lesions or prolonged medical therapy with sirolimus.[4,5] Few describe the outcome of complete excision with phrenic nerve sacrifice and immediate diaphragmatic plication in a young child. We report such a case in a 2-year-old boy, in whom resectability determined the choice of treatment.

CASE REPORT

A previously healthy 2-year-old boy presented with a history of recurrent cough persisting for two to three weeks, which disrupted sleep and was accompanied by intermittent fever. A chest radiograph revealed mediastinal widening, and computed tomography (CT) of the chest identified a well-defined anterior mediastinal mass. Surgical excision was recommended. The family sought a second opinion at another institution, where a CT-guided true-cut biopsy was conducted.

Histopathological analysis indicated a benign vascular-lymphatic lesion, characterized by spindle cells positive for smooth muscle actin and desmin, vascular spaces positive for D2-40 and CD31, and negative for STAT6 and beta-catenin. The Ki-67 proliferative index was below one percent, with no atypia or evidence of malignancy.

The child was then referred to our unit. In light of the biopsy diagnosis, contrast-enhanced magnetic resonance imaging of the chest was performed for surgical planning. It revealed a solid-cystic anterior mediastinal mass measuring 67 by 50 by 73 millimetres, extending from the level of the manubrium sterni to the junction of the superior vena cava and right atrium, and abutting the innominate vein, superior vena cava, right atrium, ascending aorta, aortic arch, and proximal right brachiocephalic artery, without intraluminal extension or compression (Figure 1).

The lesion contained at least three large cysts that were hyperintense on T1 and T2 weighted sequences, consistent with proteinaceous or haemorrhagic contents, with a solid component that was isointense on T1 and heterogeneously hyperintense on T2 weighted sequences. There was no pericardial effusion and no mediastinal lymphadenopathy. Serum tumour markers, including beta-human chorionic gonadotropin, alpha-fetoprotein, and lactate dehydrogenase, were within normal limits, and cartridge-based nucleic acid amplification testing for tuberculosis was negative.

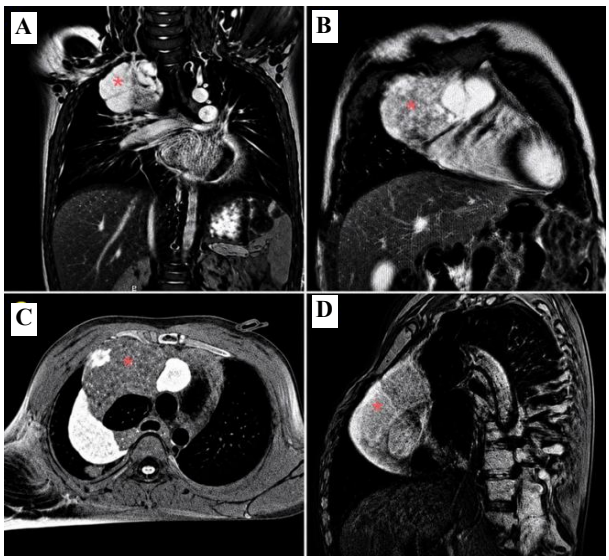

Figure 1: Contrast-enhanced magnetic resonance imaging of the chest showing a large multiloculated solid-cystic anterior mediastinal mass (asterisk) in coronal (A) coronal cine (B) axial (C) and sagittal (D) views. The cystic components are hyperintense on T1 and T2 weighted sequences and the solid component is T1 isointense and heterogeneously T2 hyperintense. The mass abuts the superior vena cava, right atrium and great vessels without intraluminal extension.

Because the child had a symptomatic, biopsy-proven benign vascular malformation that was localized and anatomically resectable, complete surgical excision was performed to remove the lesion entirely. Through a median sternotomy, a large anterior mediastinal mass measuring 5 by 6 centimeters was identified, closely related to the thymus, with multiple venous connections to the right and left brachiocephalic veins and the superior vena cava (Figure 2). The thymus and the lesion were dissected en bloc off the pericardium and pleura and freed from the right pleural cavity. A prominent venous channel draining into the junction of the superior vena cava and the confluence of the brachiocephalic veins was dissected, stapled, and divided. The right phrenic nerve was densely adherent to the lesion and could not be separated, so the involved segment was resected en bloc with the tumor. The entire lesion with the adjacent thymus was removed without rupture or spillage. Because the phrenic nerve had been resected, the right hemidiaphragm was plicated with interrupted 2-0 polyester sutures to prevent paradoxical movement. Plication was performed at the same sitting to avoid a second anesthetic and early postoperative paradox. Two intercostal drains were placed, and the sternotomy was closed in layers.

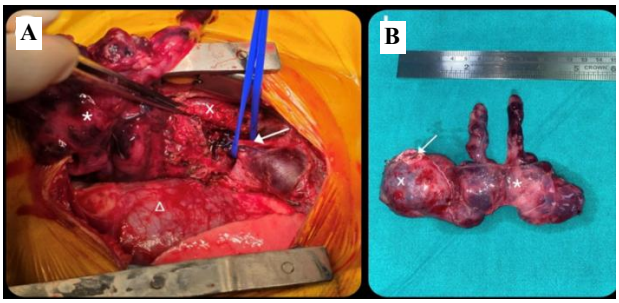

Figure 2: (A) Intraoperative view after median sternotomy showing the anterior mediastinal venolymphatic malformation (x) arising from the thymus (asterisk) and lying adjacent to the pericardium (triangle). The brachiocephalic vein (arrow) lies close to the lesion, and a feeding venous tributary has been looped for control during dissection (B) Resected specimen.

The child was extubated on the operating table and subsequently monitored in the intensive care unit. The postoperative period was uneventful, and the child was discharged on the fourth postoperative day. Histopathological analysis of the resected specimen, measuring 13 by 8 by 3 centimetres, revealed a well-encapsulated mass. This mass contained a 4.5 by 4.5 by 3 cm multicystic spongy grey-white lesion adjacent to normal thymic tissue. Microscopic examination identified thick and thin-walled congested intercommunicating vascular channels, along with dilated lymphatic channels lined by flattened endothelium and containing proteinaceous fluid. These were separated by fibrous septa with smooth muscle bundles and adipose tissue, without atypia or increased mitotic activity. The

diagnosis was a benign vascular malformation consistent with a venolymphatic malformation, with normal adjacent thymic tissue. The resection was macroscopically complete with an intact capsule, although a formal microscopic margin assessment was not conducted. At follow-up visits at two weeks, four weeks, and three months, the child was in good health and thriving, with no respiratory issues. Serial chest radiographs indicated a stable, appropriately elevated right hemidiaphragm with satisfactory bilateral lung expansion (Figure 3). An objective assessment of diaphragmatic mechanics and sleep-related breathing is planned as the child continues to grow.

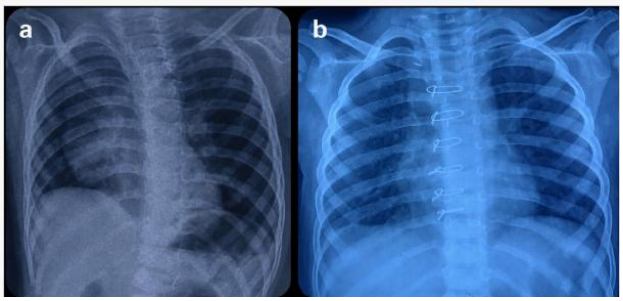

Figure 3: Chest radiographs; (a) Preoperative film showing a widened anterior mediastinum due to the mass; (b) Postoperative film showing reduced mediastinal width after excision, with a stable elevated right hemidiaphragm and satisfactory bilateral lung expansion.

DISCUSSION

Fever and cough, this child raised the possibility of lymphoma or infection, and fever with these lesions has been linked to intralesional hemorrhage, thrombosis or inflammation.[3] In this particular case, normal tumor markers, a negative tuberculosis evaluation and distinctive magnetic resonance imaging findings indicated a benign lesion.[6] Image-guided biopsy of vascular mediastinal lesions is generally discouraged due to the risk of hemorrhage.[3] In this instance, the core biopsy was conducted at a different institution prior to referral, and while it confirmed the diagnosis, magnetic resonance imaging features are often adequate, necessitating careful consideration of the biopsy's risks against its additional diagnostic value.

Medical therapy plays an increasingly important role in managing these lesions. Sirolimus elicits a response in most treated patients; however, these responses are typically partial rather than complete, and therapy is prolonged or indefinite, with lesions often regrowing after treatment cessation.[5] Consequently, sclerotherapy and sirolimus are most beneficial for diffuse or infiltrative disease, or when operative risk is prohibitive. In some reported cases, a high-risk mediastinal lesion has been observed without intervention.[4] The present lesion was different, being localized, well-circumscribed, symptomatic and fully resectable. Complete excision removed the lesion in a single procedure and provided a whole-specimen diagnosis, which medical therapy cannot offer. Since the malformation encased the phrenic nerve, sirolimus would not have eliminated the lesion or freed the nerve, making it unsuitable for avoiding nerve sacrifice in this case. This report suggests that for a localized, resectable venolymphatic malformation, excision can achieve definitive removal without prolonged immunosuppression, although comparative studies are needed to define the optimal treatment algorithm.

Phrenic nerve sacrifice in a young child is not undertaken lightly but is accepted when the nerve is inseparable from the lesion and the contralateral nerve is intact.[7] Immediate plication was performed to prevent paradoxical diaphragmatic movement. Favourable long-term outcomes after plication for phrenic nerve loss in children have been reported, including a neonate with a mediastinal lymphangioma in whom plication, performed five weeks after excision, was followed by no recurrence and no respiratory problems at four years.[8] In the present case, plication was immediate rather than delayed. This report has several limitations.

Follow-up is short at three months, which does not allow assessment of long-term respiratory function, recurrence, the late effects of plication, or the impact of unilateral diaphragmatic loss on a growing child. Objective diaphragmatic and sleep assessment will be undertaken as the child matures, since effort-dependent pulmonary function testing is not reliable at this age. Margins were assessed macroscopically with an intact capsule but not microscopically, which is accepted for a benign vascular malformation but precludes formal confirmation of clearance.

Histology did not confirm nerve infiltration, so dense adherence rather than true invasion may have necessitated resection, a distinction that could refine surgical indications in future cases. As a single case without a medical-therapy comparator, it cannot establish the relative efficacy of surgery and sirolimus, and the treatment choice reflects clinical judgement rather than comparative evidence. Concordance between the preoperative biopsy and the resection specimen, which gave the same benign diagnosis on two independent samplings, supported the diagnostic pathway.

CONCLUSION

A localized, symptomatic mediastinal venolymphatic malformation in a young child can be excised completely through a median sternotomy, even when the phrenic nerve has to be sacrificed. Immediate plication of the right hemidiaphragm at the same sitting avoided a second anesthetic, and the child remained free of respiratory problems with a stable diaphragmatic position at three months. Published experience with these lesions centers

on observation and sirolimus. This case adds evidence that resectability should guide treatment planning, and that excision gives definitive removal and a whole-specimen diagnosis without prolonged immunosuppression. Longer follow-up will define recurrence risk and diaphragmatic function in the growing child.

Funding: No funding sources
Conflict of interest: None declared
Ethical approval: Not required

REFERENCES

1. Kunimoto K, Yamamoto Y, Jinnin M. ISSVA classification of vascular anomalies and molecular biology. Int J Mol Sci. 2022;23:2358.
2. Kang MK, Kang DK, Hwang YH, Kim JY. Mediastinal venolymphatic malformations mimicking thymic carcinoma. Thorac Cancer. 2020;11(1):170-2.
3. Tovichien P, Kaeotawee P, Udomittipong K, Pacharn P, Ruangchira-Urai R. A rare case of mediastinal lymphatic venous malformations in children. Respirol Case Rep. 2021;9(12):e0881.
4. Munechika M, Tobino K, Okahisa M, Gotou Y, Murakami K, Sueyasu T, et al. A case of huge lymphatic and venous malformations of the mediastinum. Respir Med Case Rep. 2018;26:53-5.
5. Adams DM, Trenor CC 3rd, Hammill AM, Vinks AA, Patel MN, Chaudry G, et al. Efficacy and safety of sirolimus in the treatment of complicated vascular anomalies. Pediatrics. 2016;137:e20153257.
6. Donnelly LF, Adams DM, Bisset GS 3rd. Vascular malformations and hemangiomas: a practical approach in a multidisciplinary clinic. AJR Am J Roentgenol. 2000;174:597-608.
7. Simansky DA, Paley M, Refaely Y, Yellin A. Diaphragm plication following phrenic nerve injury: a comparison of paediatric and adult patients. Thorax. 2002;57(7):613-6.
8. Takamatsu H, Noguchi H, Tahara H, Kajiya H, Akiyama H. Giant mediastinal lymphangioma in a neonate: report of a case. Surg Today. 1996;26(7):527-31.

Cite this article as: Kumaravel M, Rathi RK, Dutta R, Bal S. Surgical excision of a mediastinal venolymphatic malformation in a 2-year-old: a case report. Int Surg J 2026;13:2631-4.